

# An unusual natural history of a rare bladder tumor: Primitive neuroectodermal tumor

Mehdi Kardoust Parizi , Arman Mousavi , Niloofar Sadeghyar 

**Cite this article as:** Parizi MK, Mousavi A, Sadeghyar N. An unusual natural history of a rare bladder tumor: Primitive neuroectodermal tumor. Turk J Urol 2019; 45(4): 316–8.

## ABSTRACT

A primary primitive neuroectodermal tumor (PNET) of the urinary bladder is a very rare bladder tumor. There are few described cases in the literature to date. We presented a 70-year-old man with primary non-metastatic bladder PNET. The diagnosis was confirmed according to immunohistochemistry evaluation. The patient underwent bladder-sparing protocol using radiotherapy and standard systemic multidrug chemotherapy (vincristine + doxorubicin + cyclophosphamide). At the end of three years of follow-up, we performed radical cystoprostatectomy due to newly diagnosed high-grade transitional cell carcinoma of the bladder at the site far from the primary bladder PNET. In conclusion, multimodal bladder sparing protocol including radiotherapy and standard systemic chemotherapy can be used for the management of primary bladder PNET with acceptable oncological outcomes.

**Keywords:** Bladder cancer; primitive neuroectodermal tumor; radical cystectomy.

## Introduction

Primitive neuroectodermal tumors (PNETs) are among highly malignant subtypes of Ewing family of neoplasias that can be defined in one of three groups including: central nerve system PNETs, neuroblastomas, and peripheral PNETs. Morphologically, PNETs are composed of round and small cells with diffuse necrosis that are confirmed by immunohistochemistry (IHC) and molecular assays.<sup>[1]</sup> Primary bladder PNET is a very rare but so invasive tumor that usually is seen in young patients.<sup>[2,3]</sup> Up to now, only few case of primary bladder PNET are reported in the literature. We present a case of a 70-year-old man with primary bladder PNET that had unusual natural history and had undergone various treatment options within three years follow-up.

## Case presentation

A 70-year-old man presented with gross hematuria and irritative urinary symptoms in April

2014. The patient underwent usual evaluation for hematuria that included abdominopelvic computed tomography (CT), urine cytology, and cystoscopy. In cystoscopic evaluation and CT scan one 44x25x27 mm nodular mass was detected in posterior wall of the bladder. After complete transurethral resection of bladder (TUR-B), pathological assessment demonstrated poorly differentiated malignancy characterized by blue small and round cells with muscularis propria involvement (Figure 1). IHC staining confirmed PNET diagnosis with strong reactivity for CD99 and synaptophysin and negative staining for thrombomodulin and cytokeratin markers (Figures 2 and 3). Metastatic evaluation was negative. The patient refused to undergo radical cystectomy as a curative therapy and he was only managed by radiotherapy and systemic chemotherapy using standard VAC regime (vincristine + doxorubicin + cyclophosphamide). Follow-up assessment of the patient including the results of periodical cystoscopy and imaging studies were normal until the year 2017. In March 2017, the patient presented with gross hematu-

### ORCID IDs of the authors:

M.K.P. 0000-0002-9380-8492;  
A.M. 0000-0002-3686-907X;  
N.S. 0000-0002-6735-5530.

Department of Urology,  
Shariati Hospital, Tehran  
University of Medical Sciences,  
Tehran, Iran

**Submitted:**  
21.11.2017

**Accepted:**  
28.12.2017

**Available Online Date:**  
12.09.2018

**Correspondence:**  
Mehdi Kardoust Parizi  
E-mail:  
m.kardoust@yahoo.com

©Copyright 2019 by Turkish  
Association of Urology

Available online at  
www.turkishjournalofurology.com



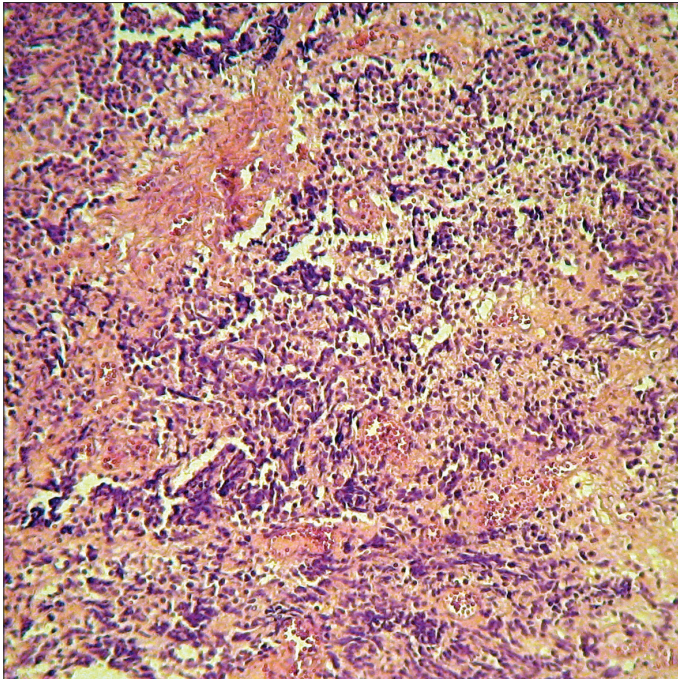


Figure 1. Uniform tumoral cells with round nuclei and small nucleoli (H&E x200)

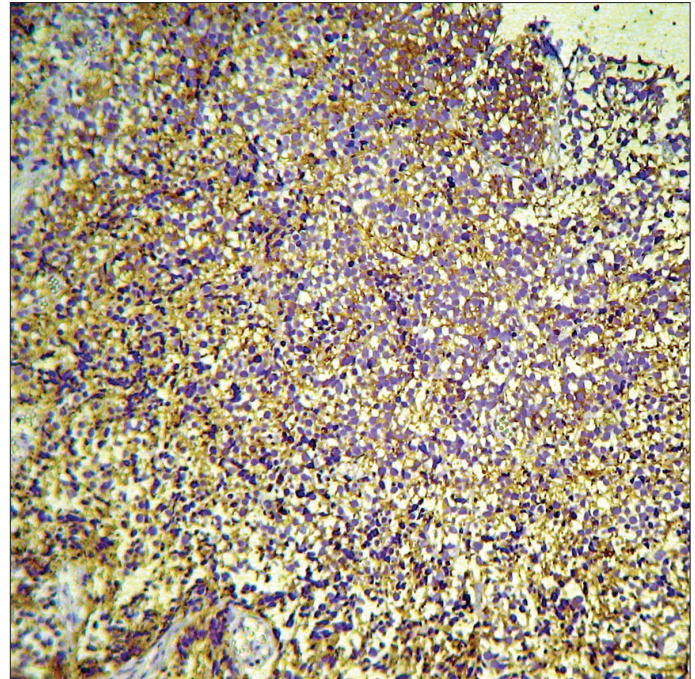


Figure 3. Histopathology section exhibiting synaptophysin immunostaining

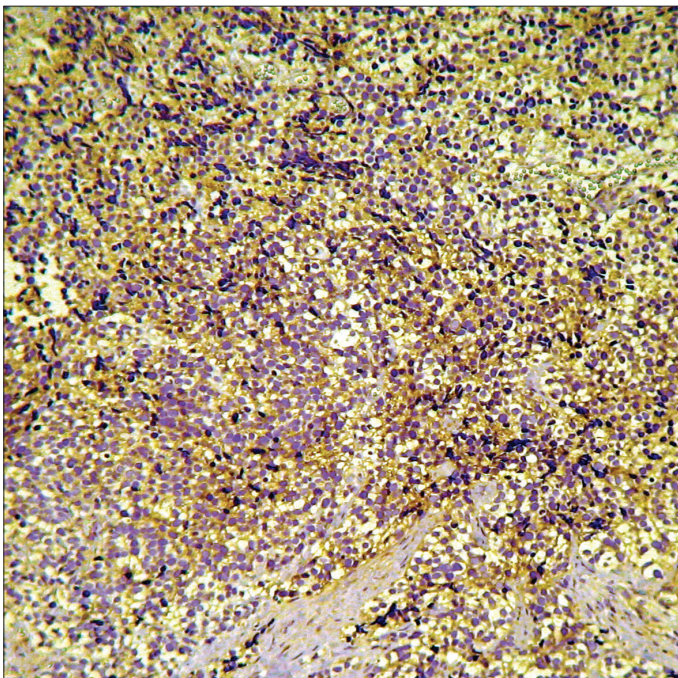


Figure 2. Tumor cells exhibiting strong membranous CD99 staining

ria, and evaluations revealed a new nodular 22x24x22 mm mass at the bladder neck with 3 cm away from the previous TUR-B scar. Histological assessment of *de novo* completely resected mass revealed high grade transitional cell carcinoma of the

bladder with muscularis propria involvement. IHC evaluation demonstrated positive staining for CK20, CK7, GATA-3, P53, weak staining for CD99 and negative staining for PSA, desmin, calretinin and thrombomodulin markers. Finally, the patient underwent radical cystoprostatectomy and extended lymph node dissection. Pathological evaluation of surgical specimen revealed invasive urothelial carcinoma without involvement of regional lymph nodes. Moreover, we found no evidence of prostatic adenocarcinoma in pathological evaluation of prostate specimen. The patient agreed to participate in this case report.

## Discussion

Primary urinary bladder PNET is known as a rare bladder malignancy and there are few presented cases in the literature.<sup>[2-7]</sup> Histologically, PNETs are consisted of small, round, uniform and poorly differentiated cells whose definite diagnosis is confirmed by IHC assessment.<sup>[3-5]</sup> These cells are strongly positive for CD99 marker and similarly EWS-FL11 fusion test yields positive results. There is no definitive guideline for treating primary bladder PNETs. These tumors, and PNETs involving other organs can be managed by the same treatment strategies including radical surgery, systemic chemotherapy and radiotherapy.<sup>[2-7]</sup> In this case report, we presented a primary bladder PNET that was managed by bladder-sparing multimodality protocol safely. Finally, the patient underwent radical cystoprostatectomy. The main indication of this surgery is



newly diagnosed transitional cell carcinoma of the bladder at the site far from primary bladder PNET. We found no focus of PNET cells in the radical cystectomy specimen. This means that primary bladder PNET may be treated completely by bladder-sparing protocol with at least three years follow-up. To our knowledge, this case is the only patients with primary bladder PNET that survived and remained tumor free at least three years after diagnosis.

In conclusion, highly aggressive primary urinary bladder PNET can be managed by a multimodal bladder-sparing protocol consisting radiotherapy and standard systemic chemotherapy.

**Informed Consent:** Written informed consent was obtained from patient who participated in this case.

**Peer-review:** Externally peer-reviewed.

**Author Contributions:** Concept – M.K.P.; Design – M.K.P.; Supervision – M.K.P.; Resources – M.K.P.; Materials – M.K.P., A.M., N.S.; Data Collection and/or Processing – M.K.P., N.S.; Analysis and/or Interpretation – M.K.P.; Literature Search – M.K.P., A.M.; Writing Manuscript – M.K.P.; Critical Review – M.K.P.; Other – M.K.P.

**Conflict of Interest:** Authors have no conflicts of interest to declare.

**Financial Disclosure:** The authors have declared that they didn't receive any financial support for this study.

## References

1. Bernstein M, Kovar H, Paulussen M, Randall RL, Schuck A, Teot LA, Juergens H. Ewing's sarcoma family of tumors: current management. *Oncologist* 2006;11:503-19. [\[CrossRef\]](#)
2. Ellinger J, Bastian PJ, Hauser S, Biermann K, Müller SC. Primitive neuroectodermal tumor: rare, highly aggressive differential diagnosis in urologic malignancies. *Urology* 2006;68:257-62. [\[CrossRef\]](#)
3. Lopez-Beltran A, Pérez-Seoane C, Montironi R, Hernández-Iglesias T, Mackintosh C, de Alava E. Primary primitive neuroectodermal tumour of the urinary bladder: A clinico-pathological study emphasising immunohistochemical, ultrastructural and molecular analyses. *J Clin Pathol* 2006;59:775-8. [\[CrossRef\]](#)
4. Banerjee SS, Eyden BP, McVey RJ, Bryden AA, Clarke NW. Primary peripheral primitive neuroectodermal tumour of urinary bladder. *Histopathology* 1997;30:486-90. [\[CrossRef\]](#)
5. Kruger S, Schmidt H, Kausch I, Böhle A, Holzhausen HJ, Johannisson R, Feller AC. Primitive neuroectodermal tumour (PNET) of the urinary bladder. *Pathol Res Pract* 2003;199:751-4. [\[CrossRef\]](#)
6. Busato WF Jr, Almeida GL, Ogata DC. Primary primitive neuroectodermal tumour of the bladder: Histologic and clinical features of nine cases. *Clin Genitourin Cancer* 2011;9:63-7. [\[CrossRef\]](#)
7. Zheng Y, Tan F, Wang L, Xu N, Mou H. Primary primitive neuroectodermal tumour of the urinary bladder: A case report and literature review. *Med Oncol* 2011;28(Suppl 1):S388-91.