



Pedicled preputial island flap for double functions in hypospadias surgery

Rabea G. Omar , Mostafa M. Khalil , Hammouda Sherif , Hesham Elezaby

Cite this article as: Omar RG, Khalil MM, Sherif H, Elezaby H. Pedicled preputial island flap for double functions in hypospadias surgery. Turk J Urol 2018; 44(5): 423-7.

ABSTRACT

Objective: To use the prepuce for double functions one as a second layer for the neourethra to decrease the incidence of urethrocutaneous fistula and the second as a skin covering for the ventral aspect of the penis.

Material and methods: From January 2013 to December 2016, 37 cases of hypospadias with mild to moderate chordee were included in this study. The cases with ventral penile skin defect were managed by tubularized incised plate urethroplasty (TIPU) using pedicled preputial flap. Recurrent cases, cases with severe chordee which necessitated division of the urethral plate, and cases with penoscrotal hypospadias were excluded from this study.

Results: Thirty-seven cases of hypospadias aged 9-60 months with a mean age of 24.8 months were included in this study. Coronal (n= 9 cases; 24.3%), distal penile (n=11; 29.9%), and midpenile hypospadias (n= 17; 45.9%) were detected in respective number of patients. Postoperative complications consisted of external meatal stenosis (n=2; 8.1%), and one case with urethrocutaneous fistula. Skin necrosis was not reported in this study. Follow-up visits were performed at 1, 3 and 6 months which showed good cosmetic appearance that was accepted by their parents.

Conclusion: This technique was beneficial in decreasing the rate of skin necrosis, as it keeps the blood supply to the preputial skin intact, and decreases the incidence of urethrocutaneous fistula.

Keywords: Hypospadias; prepuce; skin necrosis; urethrocutaneous fistula.

Introduction

Hypospadias is defined as hypoplasia of the ventral aspect of the penis beyond the division of corpus spongiosum^[1], including abnormal ventral opening of the urethral meatus, abnormal ventral curvature of the penis (chordee), and/or abnormal distribution of the foreskin. It is one of the most common genital anomalies in male newborn 1:300.^[2,3] Hypospadias may be classified into distal penile, midpenile and coronal hypospadias depending on the location of the abnormal urethral opening.^[1] Surgical reconstruction is the only therapeutic method for hypospadias to create normal looking penis with terminally situated meatus with correction of chordee if present.^[4,5] There are different surgical techniques for hypospadias

repair, tubularized incised plate urethroplasty (TIPU) repair is the most common technique in many institutions.^[6,7]

The prepuce is an important tissue that can be used in different ways for hypospadias repair: firstly, reconstruction of the neourethra. secondly, dartos layer as a cover for the neourethra to decrease the incidence of urethrocutaneous fistula, and lastly, for providing skin cover for the ventral aspect of the penis. Unfortunately, each patient has only one prepuce usually serving one function in the repair, In TIPU, urethral plate is used for urethroplasty and dartos layer created from the prepuce and dorsal penile skin are used for covering the neourethra, in cases of ventral penile skin defect, Byar's method of using preputial skin to cover the ventral

ORCID IDs of the authors:

R.G.O. 0000-0002-4821-6455;
M.M.K. 0000-0002-3865-2501;
H.S. 0000-0002-9621-4630;
H.E. 0000-0002-7588-7975

Department of Urology, Benha
University School of Medicine,
Egypt

Submitted:
22.10.2017

Accepted:
19.01.2018

Available Online Date:
16.03.2018

Corresponding Author:
Hammouda Sherif
E-mail:
hammoda_elsherif@yahoo.com

©Copyright 2018 by Turkish
Association of Urology

Available online at
www.turkishjournalofurology.com

aspect of the penis results in ventral skin loss in 21% as the skin is deficient from its blood supply.^[8]

The aim of this study is to use the prepuce for double functions one as a second layer for the neourethra to decrease the incidence of urethrocutaneous fistula and the second one as a skin covering for the ventral aspect of the penis.

Material and methods

From January 2013 to December 2016 after approval of the local ethics committee, 95 children with hypospadias were assessed for eligibility at urology department, and 82 children with distal and midpenile hypospadias were managed by TIPU in our department. In 45 cases the ventral surface of the penis was covered by suturing the lateral edges the already pliable skin together to form a median ventral raphe. The remaining 37 cases with mild to moderate chordee, and ventral penile skin defect was managed by TIPU using pedicled preputial flap. Recurrent cases, cases with severe chordee which necessitated division of the urethral plate, and cases with penoscrotal hypospadias were excluded from this study (Figure 1).

Surgical technique

Under general anesthesia with caudal analgesia, a stay suture

was placed at the tip of the glans. Circumferential subcoronal skin incision 5 mm proximal to the coronal sulcus at the dorsal aspect of the penis and a U shaped incision around the urethral plate at the ventral aspect of the penis proximal to the urethral meatus, and complete degloving of the penile skin up to the penoscrotal junction along the Buck's fascia were performed. Afterwards an artificial erection test was realized. In 35 cases the chordee was formed by skin only and managed by degloving. In 2 cases of midpenile hypospadias associated with mild chordee, plication of dorsal tunica was realized by longitudinal incision on both sides at the maximal convexity avoiding the neurovascular bundles and the incision was closed transversely by proline 4/0 sutures. TIPU was performed as described by Snodgrass.^[6] Transverse skin incision was performed at the dorsal aspect of the penile skin at the junction between the penile skin and the prepuce (Figure 2). This incision was deepened to include the epidermis and the dermis only entering the plane just beneath the dermis. Then dissection was extended proximally up to the proximal third of the penis, taking care to avoid injury of the skin blood supply or the preputial pedicle (dartos flap). This preputial flap was rotated ventrally and the remaining part of the inner surface of the prepuce was excised, and the length of the pedicle flap was assessed. If it was long enough, it could be applied as a second layer for the neourethra keeping the

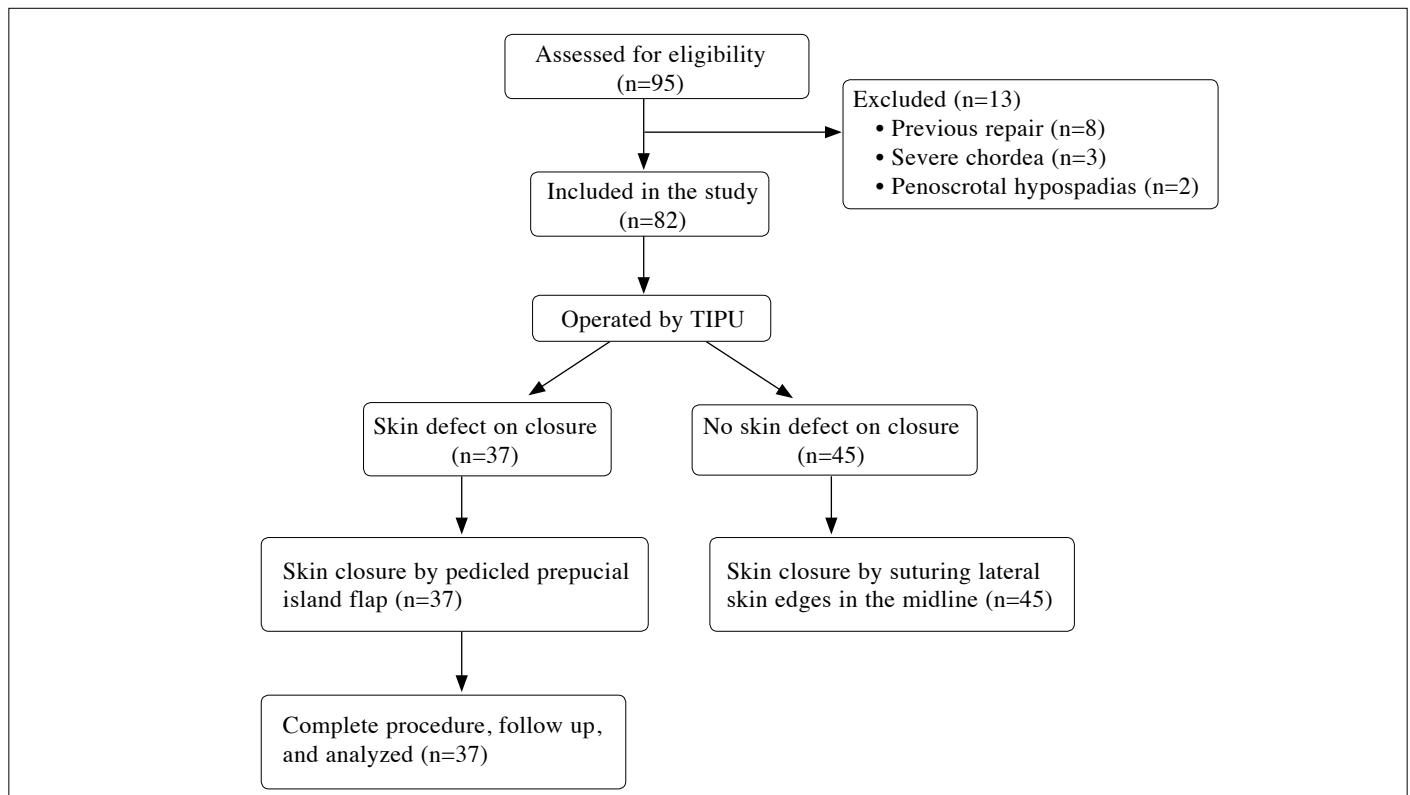


Figure 1. Study flow chart

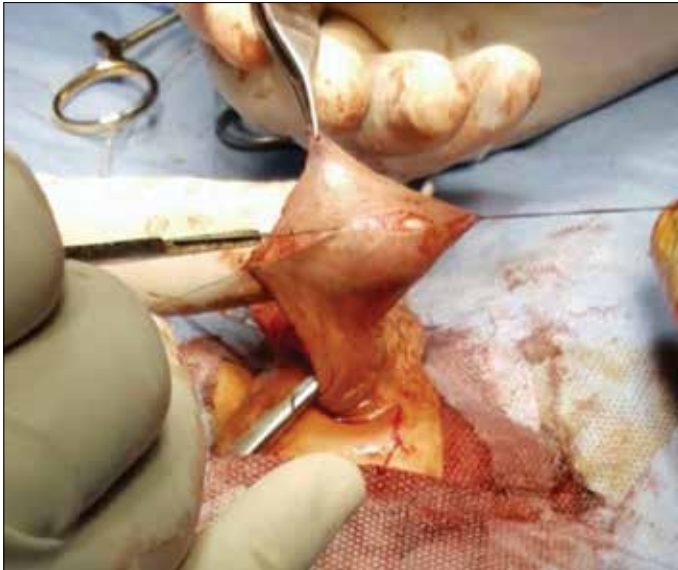

Figure 2. Transverse skin incision at the junction of the prepuce and penile skin

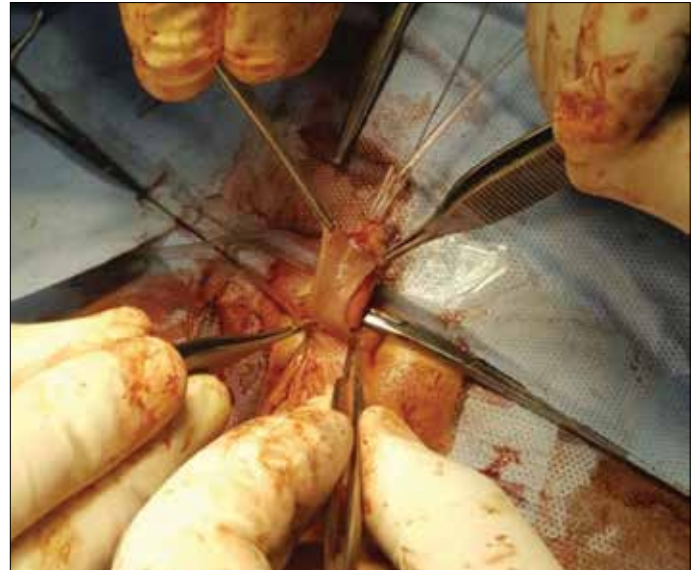


Figure 4. The preputial skin used for covering the ventral aspect of the penis

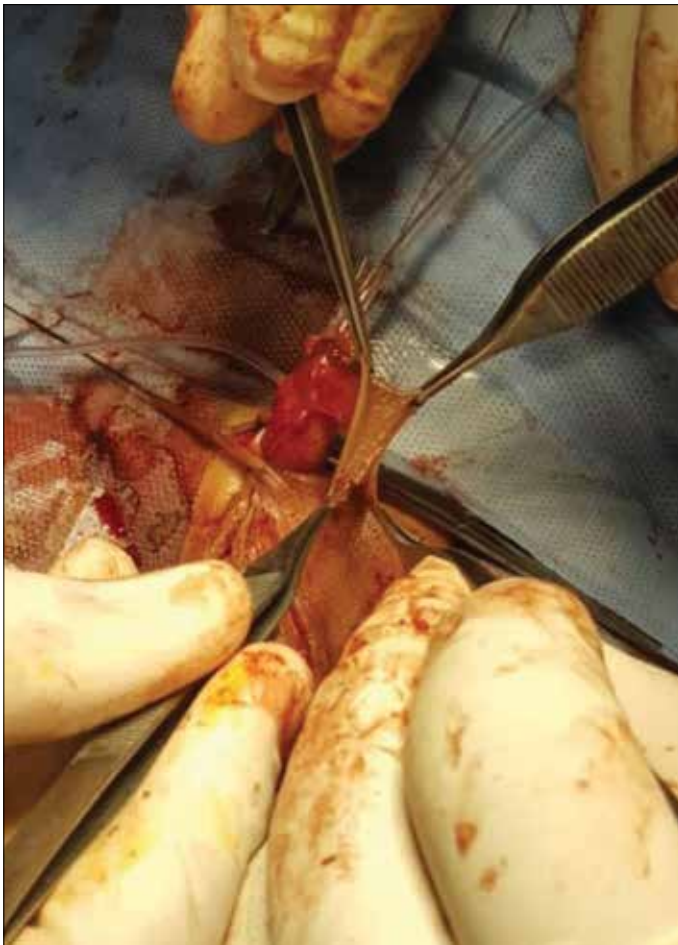

Figure 3. The proximal part of the dartos pedicle was used as a second layer for the neourethra

skin proximal to the mucosal collars of the ventral coronal sulcus intact (Figure 3, 4) but if the pedicle flap was enough to reach the neourethra without tension, it could be applied over the neourethra. But the distal part of it which covers the urethral part and will be under the glanular wings and coronal sulcus was de-epithelialized keeping the remaining skin as a cover for the ventral aspect of the penis suturing it to the lateral penile skin edges and proximal skin edge at the original meatus. Then the distal margin of the dorsal penile skin was sutured to the mucosal collar at the coronal sulcus and after completion of suturing all around, soft dressing was applied. The incidence of the skin necrosis, urethrocutaneous fistula, wound dehiscence and meatal stenosis were recorded and analyzed statistically.

Statistical analysis

Data of the study were collected, analyzed and tabulated using IBM Statistical Package for the Social Sciences (IBM SPSS Statistics; Armonk, NY, USA) version 20 software. The categorical data were presented as numbers and percentages, and quantitative data were presented as means with standard deviation (SD).

Results

Thirty-seven cases of hypospadias aged 9-60 months with a mean age of 24.8 month swere included in this study. The cases with coronal (n=9; 24.3%), distal penile (n=11; 29.9%), and midpenile (n=17; 45.9%) hypospadias all of them with mild to moderate chordee were included in the study. Thirty-five cases with mild chordee was corrected by complete skin degloving

Table 1. Patient characteristics and postoperative complications

Variables	
Age (months) Mean (± SD) age; range	24.8±13.4 (9-60)
Location of meatus	
Coronal, n (%)	9 (24.3)
Distal penile, n (%)	11 (29.8)
Mid shaft, n (%)	17(45.9)
Complications	
Meatal stenosis, n (%)	2 (5.4)
Urethral fistula, n (%)	1 (2.7)

only, the remaining 2 cases of midpenile hypospadias with moderate chordee needed dorsal tunica plication to straighten the penis. All cases were done by the same technique of TIPU with pedicled preputial flap. The postoperative complications (n=3; 8.1%) included 2 cases of external meatal stenosis, one of which responded to conservative management by regular dilatation and the other was associated with urethrocuteaneous fistula that needed ventral meatotomy and fistula repair after 6 months postoperative (Table 1). Skin necrosis was not reported in this study. Follow- up visits were performed at postoperative 1, 3 and 6 months and showed good cosmetic appearance that was accepted by their parents.

Discussion

TIPU is the most common procedure used for hypospadias repair all over the world.^[9] It has the advantage of sparing the prepuce, and the dartos flap created from the prepuce and dorsal penile skin is used as a second layer for the neourethra to decrease the incidence of fistula formation.^[10]

Skin covering is the last step of hypospadias repair and it is very important to resurface the penis after urethroplasty. Several techniques have been used for this purpose. (a) The lateral skin edges are sutured together in the midline. However this method may create tension, so a relaxing dorsal skin incision may be needed to relieve the skin tension^[11], (b) A button hole is created in the skin of the midshaft, and the penis is delivered through this button hole. However it creates difficulty in fashioning the lateral edges^[12-14] or (c) A Byar's flap is formed. But as the dartos is used to cover the neourethra created from the prepuce this method leads to skin necrosis, and dorsal penile skin used causes preputial skin necrosis due to its poor blood supply.^[15]

Abou Zeid^[8] published a modified Byar's flap technique for skin closure combined with TIPU. He divided the prepuce after degloving and urethroplasty. Then he used one half of the prepuce, and created a dartos flap for covering the neourethra and the other half was used to cover the ventral aspect of the penis with its dartos fascia to guard against skin necrosis. He compared the results of Byar's and modified Byar's techniques in his study, and detected higher incidence of ventral skin loss in original Byar's method (21%) when compared with modified Bayer's method (0%) method.

In the present study we used the prepuce with its dartos pedicle to perform double functions, first to cover the neourethra to decrease the incidence of fistula and second to cover the ventral aspect of the penis with vascularized skin and no case of skin necrosis was reported in this study. This technique was previously described and published by others with some modifications.^[16,17] Mollaeian et al.^[18] had performed the same technique in 112 children and reported a complication rate of 8% including 2 cases of flap necrosis (1.7%) which they argued that these were performed previously, and development of flap necrosis might be due to technical error. They reported development of fistula in 2.6% (n=3), and external meatal stenosis in 3.5% (n=4) of their cases (corresponding rates in our study were 2.7%, and 5.4%) Galifer and Kalfa^[19] performed the same technique. But in their study the dartos pedicle did not cover the distal part of the neourethra which was covered by glans penis and it covered only the penile part of the neourethra which resulted in infrequent (<2%) partial necrosis of the lateral border of the flap with no effect on urethroplasty. However in the present study, the dartos pedicle covered the whole neourethra in addition to that, two suture lines of the preputial skin was placed on the urethral suture line. All these factors decreased the incidence of skin necrosis. So, this technique was beneficial in decreasing the rate of skin necrosis as modified Byar's flap, as it keeps the blood supply to the preputial skin intact, and decreases the incidence of urethrocuteaneous fistula as its pedicle acts as a second layer. And we recommend using this technique in hypospadias cases associated with ventral skin defect and intact urethral plate to be used for urethroplasty.

In conclusion, pedicled preputial island flap for double functions in hypospadias repair was beneficial in decreasing the rate of skin necrosis, as it keeps the blood supply to the preputial skin intact, and decreases the incidence of urethrocuteaneous fistula.

Ethics Committee Approval: Ethics committee approval was received for this study from the ethics committee of Benha University School of Medicine.

Informed Consent: Written informed consent was obtained from patients' parents who participated in this study.

Peer-review: Externally peer-reviewed.

Author Contributions: Concept - H.S.; Design - M.M.K.; Supervision - R.G.O.; Data Collection and/or Processing - H.E.; Analysis and/or Interpretation - H.S.; Literature Search - R.G.O.; Writing Manuscript - H.S.; Critical Review - M.K.

Conflict of Interest: No conflict of interest was declared by the authors.

Financial Disclosure: The authors declared that this study has received no financial support.

References

1. Tekgül S, Riedmiller H, Dogan HS, Hoebeke P, Kocvara R, Nijman R, et al. Guidelines on pediatric urology: European Association of Urology 2013.
2. Djakovic N, Nyarangi-Dix J, Öztürk A, Hohenfellner M. Hypospadias. *Adv Urol* 2008;650135.
3. Baskin LS, Ebberts MB. Hypospadias: anatomy, etiology, and technique. *J Pediatr Surg* 2006;41:463-72. [\[CrossRef\]](#)
4. Zaontz MR, Dean GE. Glanular hypospadias repair. *Urol Clin North Am* 2002;29:291-8. [\[CrossRef\]](#)
5. Aboulwafa A, Aboufotouh S, El-sherbeni K. Modified Tubularized Incised Plate (TIP) Hypospadias Repair Using Dartos Fascia Flap. *Egypt J Plast Reconstr Surg* 2006;30:139-42.
6. Snodgrass WT, Nguyen MT. Current technique of tubularized incised plate hypospadias repair. *Urology* 2002;60:157-62. [\[CrossRef\]](#)
7. EL-Sherbiny MT. Tubularized incised plate repair of distal hypospadias in toilet-trained children: should a stent be left? *BJU Int* 2003;92:1003-5.
8. Abou Zeid AA. Modified Byars' flaps for securing skin closure in proximal and mid-penile hypospadias. *Ther Adv Urol* 2001;3:251-6.
9. Snodgrass WT. Utilization of urethral plate in hypospadias surgery. *Indian J Urol* 2008;24:195-9. [\[CrossRef\]](#)
10. Retik AB, Mandell J, Bauer SB, Atala A. Meatal based hypospadias repair with the use of a dorsal subcutaneous flap to prevent urethrocutaneous fistula. *J Urol* 1994;152:1229-31. [\[CrossRef\]](#)
11. Baskin LS, Duckett JW, Ueoka K, Seibold J, Snyder HM 3rd. Changing concept of hypospadias curvature lead to more onlay island flap procedures. *J Urol* 1994;151:191-6. [\[CrossRef\]](#)
12. Asopa HS, Elhence EP, Atria SP, Bansal NK. One stage correction of penile hypospadias using a foreskin tube a preliminary report. *Int Surg* 1971;55:435-40.
13. Welch KJ. Hypospadias. pediatric surgery; 3rd edn. Chicago: year book medical publishers; 1979.pp.1353-76.
14. Snodgrass W, Patterson K, Plaire JC, Grady R, Mitchell ME. Histology of the urethral plate: implications for hypospadias repair. *J Urol* 2000;164:988-9. [\[CrossRef\]](#)
15. Bakal Ü, Abeş M, Sarac M. Necrosis of the ventral penile skin flap: a complication of hypospadias surgery in children. *Adv Urol* 2015;452870.
16. Scuderi N, Campus GV. A new technique for hypospadias one stage repair. *Chir Plast* 1983;7:103-6. [\[CrossRef\]](#)
17. Rushton HG. Hypospadias. *J Urol* 1994;152:1241-2. [\[CrossRef\]](#)
18. Mollaeian M, Pourang H, Eskandari F, Raji H. Use of preputial island flap for penile skin reconstruction in hypospadias. *Iranian J Pediatr Surg* 2015;1:1-4.
19. Galifer RB, Kalfa N. The transverse outer preputial (TOP) island flap: an easy method to cover urethroplasties and skin defects in hypospadias repair. *J Pediatr Surg* 2005;1:89-94.