



# Supraclavicular lymph node as the first presentation and late skin metastasis: an unusual clinical course for prostate cancer

*Supraklaviküler lenf nodu ile ilk başvuru ve cilt metastazı, prostat adenokarsinomu için alışılmadık klinik seyir*

Meftun Çulpan , Asif Yıldırım , Turgay Turan , Turhan Çaşkurlu

**Cite this article as:** Çulpan M, Yıldırım A, Turan T, Çaşkurlu T. Supraclavicular lymph node as the first presentation and late skin metastasis, an unusual clinical course for prostate cancer. Turk J Urol 2018; 44(1): 75-8.

## ABSTRACT

Prostate cancer is the most common non-cutaneous malignancy and the second cause of cancer death in men. Despite improvements in diagnostic methods, the primary diagnosis of a number of patients may still be on metastatic stage. Cutaneous and supraclavicular lymph nodes are very rare metastatic sites for prostate cancer. In this report we present an extremely rare prostate cancer case diagnosed with supraclavicular lymph node and then developed cutaneous metastasis. A 64 year-old man was admitted to an internal medicine outpatient clinic with supraclavicular lymph node and biopsy of lymph node showed an adenocarcinoma. After prostate cancer diagnosis, patient was treated with androgen deprivation therapy, docetaxel chemotherapy and abiraterone acetate, respectively. While abiraterone treatment, cutaneous metastasis developed in inguinal area and diagnosis was confirmed by skin biopsy. In some cases, atypical symptoms may guide us to find disease with aggressive clinics. That's why, physical rectal examination and prostate specific antigen measurements should be kept in mind for prostate cancer in male patients with supraclavicular lymph node or atypical metastasis.

**Keywords:** Prostate cancer; skin metastasis; supraclavicular lymph node..

## ÖZ

Prostat kanseri, erkeklerde görülen cilt kanserleri dışında en yaygın ve ölüme yol açan en sık ikinci kanserdir. Tanı yöntemlerindeki gelişmelere rağmen, bazı hastaların teşhisi halen metastatik evrede konulabilmektedir. Cilt ve supraklaviküler lenf nodları, prostat kanseri için nadir görülen metastaz bölgeleridir. Bu yazıda supraklaviküler lenf nodu metastazı ile tanı alan ve ciltte metastaz gelişen nadir bir prostat kanseri vakası sunulmuştur. 64 Yaşındaki erkek hasta supraklaviküler lenf nodu ile iç hastalıkları polikliniğine başvurmuş ve lenf nodu biyopsisinde adenokarsinom saptanmıştır. Prostat kanseri tanısından sonra sırasıyla androjen baskılama tedavisi, dosetaksel kemoterapisi ve abiraterone asetat ile tedavi edilmiştir. Abirateron tedavisi sırasında inguinal alanda kutanöz metastaz gelişmiş ve biyopsi ile prostat kanseri metastazı olduğu doğrulanmıştır. Bazı durumlarda atipik semptomlar agresif seyirli bir hastalığın tanısını koymamıza yardımcı olabilir. Bu nedenle supraklaviküler lenf nodu veya atipik metastazlı erkek hastalarda prostat kanseri için parmakla rektal muayene ve PSA ölçümleri akılda tutulmalıdır.

**Anahtar Kelimeler:** Prostat kanseri; cilt metastazı; supraklaviküler lenf nodu.

## Introduction

Prostate cancer is the most common non-cutaneous malignancy and the second most common cause of cancer death in men with 180,890 estimated new cases and 26,120 estimated deaths in 2016.<sup>[1]</sup> Widespread clinic usage of prostate specific antigen (PSA) leads increased incidence of especially asymptomatic, early stage prostate cancer disease. Even if carcinoma of the prostate is generally slow

growing, it can be rarely detected with metastatic lesions. The percentage of metastatic prostate cancer in newly diagnosed cases is approximately 5%.<sup>[1]</sup> Prostate cancers mostly spread to bones and internal, external and obturator lymph nodes, followed by pre-sacral and para-aortic lymph nodes.<sup>[2,3]</sup>

In children and young adults cervical lymph node enlargement is usually related to an inflammatory disease or lymphoma.<sup>[4]</sup> In

**ORCID IDs of the authors:**  
M.Ç. 0000-0001-8573-1192;  
A.Y. 0000-0002-3386-971X;  
T.T. 0000-0002-4951-6396;  
T.Ç. 0000-0002-4471-2670

Department of Urology,  
İstanbul Medeniyet University  
Göztepe Training and Research  
Hospital, İstanbul, Turkey

**Submitted:**  
23.09.2016

**Accepted:**  
09.12.2016

**Available Online Date:**  
19.12.2018

**Correspondence:**  
Meftun Çulpan  
E-mail:  
mculpan@gmail.com

©Copyright 2018 by Turkish  
Association of Urology

Available online at  
www.turkishjournalofurology.com

elderly patients it can be related to lymphoma or a metastatic dissemination of either squamous cell carcinoma or adenocarcinoma.<sup>[5]</sup> Cervical and especially supraclavicular lymph node metastases are frequently originated from head and neck cancers and this metastases are very rarely originated from prostate cancer.<sup>[3]</sup> Cutaneous metastasis is rare condition also with 5.3% overall incidence and breast cancer is the most frequent tumor that spread to the skin.<sup>[6]</sup> Despite high incidence and prevalence of prostate cancer, supraclavicular lymph node and cutaneous metastases are uncommon with a reported incidence rates of approximately 0.28% and 0.36%, respectively.<sup>[3,7]</sup> We report herein a prostate cancer patient with skin metastasis who firstly presented with supraclavicular lymph node enlargement and then developed cutaneous metastasis.

## Case presentation

A 64-year-old man was referred to internal medicine outpatient clinic with a 2-month history of painless, palpable and persistent bilateral supraclavicular enlargement. He had no other subjective complaints or lower urinary tract symptoms and no comorbidity or family history of malignancy. Physical examination showed a painless, non-tender, firm mass measuring approximately 9 cm at left and 3 cm at right supraclavicular lymph node, fixed to underlying tissues. Complete blood count and routine biochemical laboratory findings were unremarkable. A magnetic resonance imaging of neck showed left and right supraclavicular lymph nodes measuring 87x49 mm, and 23x27 mm, respectively. There were no tumor or lymph node in chest computerized tomography (CT) but an abdominal CT showed bulky masses of para-aortic, para-caval, aorto-caval, bilateral common iliac, left internal iliac, left obturator and left external iliac nodes. The maximum diameter of the abdominal lymph nodes was 21mm. Positron emission tomography-computed tomography (PET-CT), performed to detect the primary site of the malignancy showed pathologically increased fluorodeoxyglucose (<sup>18</sup>F) (FDG) involvement of the bilateral supraclavicular and supra-infradiaphragmatic lymph nodes and bone metastasis.

Fine needle biopsy of supraclavicular lymph node was performed and histological examination showed adenocarcinoma that had metastasized to lymph nodes. To identify the primary lesion, serum tumor markers were examined and rectal examination was done. PSA levels were 351 ng/mL and rectal examination revealed a fixed, enlarged prostate. Transrectal ultrasound-guided prostate biopsy was performed and histological examination showed poorly differentiated adenocarcinoma with a total Gleason score of 5+5. Bone scintigraphy was performed and showed multiple bone metastases.

After diagnosis of metastatic prostate cancer, hormone therapy including a luteinizing hormone-releasing hormone agonist and

an anti-androgen was started. The patient responded well to this therapy and after 3 months, PSA level had decreased to 3.59 ng/mL. But within 1 year disease became castration-resistant and bone scan and abdominal CT showed a progression in bone and lymph node metastases. Bilateral nephrostomy catheter was placed due to bilateral hydronephrosis. After 10 cycles of docetaxel (75-mg/m<sup>2</sup>) chemotherapy per 3-week PSA rises and progression of metastasis could not be prevented, so abiraterone acetate treatment was started.

While patient was under abiraterone acetate treatment; pink, elevated and non-tender skin lesions were inspected on the pubic and left inguinal region (Figure 1). A punch biopsy was performed with the suspicion of prostate cancer metastasis and histological examination showed malign epithelial tumor metastasis corresponding to prostate cancer metastasis with supporting immunohistological examination of PSAP positivity. After diagnosis of cutaneous metastasis, PSA levels continued to rise and after 2 months the patient died in the hospital. Written informed consent form had been priorly obtained from the patient.

## Discussion

Although, bone is the most common site of distant metastasis for prostate cancer, some other rare metastatic sites can be seen. Skin and supraclavicular lymph nodes are very rare metastatic locations for prostate cancer. Mueller et al.<sup>[7]</sup> published a meta-analysis exhibiting cutaneous metastasis of genitourinary malignancies and reported that 8 patients had cutaneous metastasis (0.36%) in 2197 cases of prostate adenocarcinoma. In another published report, Wang et al.<sup>[8]</sup> found 78 cases with cutaneous metastases of prostate cancer in a literature review and indicated the most common sites of cutaneous metastasis as penis and inguinal area (28%), abdomen (23%), neck and head (16%), thoracic wall (14%), extremities (10%), and back (9%). Hematpour et al.<sup>[3]</sup> found 4 (0.3%) supraclavicular lymph node metastases among 1,400 metastatic prostate cancer patients. In our case, the patient had both supraclavicular lymph node and cutaneous metastasis. When we investigated our records of 1695 prostate cancer patients, this was the first case, with both supraclavicular lymph node and cutaneous metastasis.

Distant metastases can occur mainly through hematogenous and lymphatic spread. Inguinal and retroperitoneal metastases are mostly result of lymphatic spread but distant metastases to supraclavicular lymph node develop typically by way of hematogenous route.<sup>[9]</sup> Our patient first presented with bilateral supraclavicular swelling via hematogenous spread and then inguinal edema and papules appeared which were probably caused by obstruction of lymphatic channels.

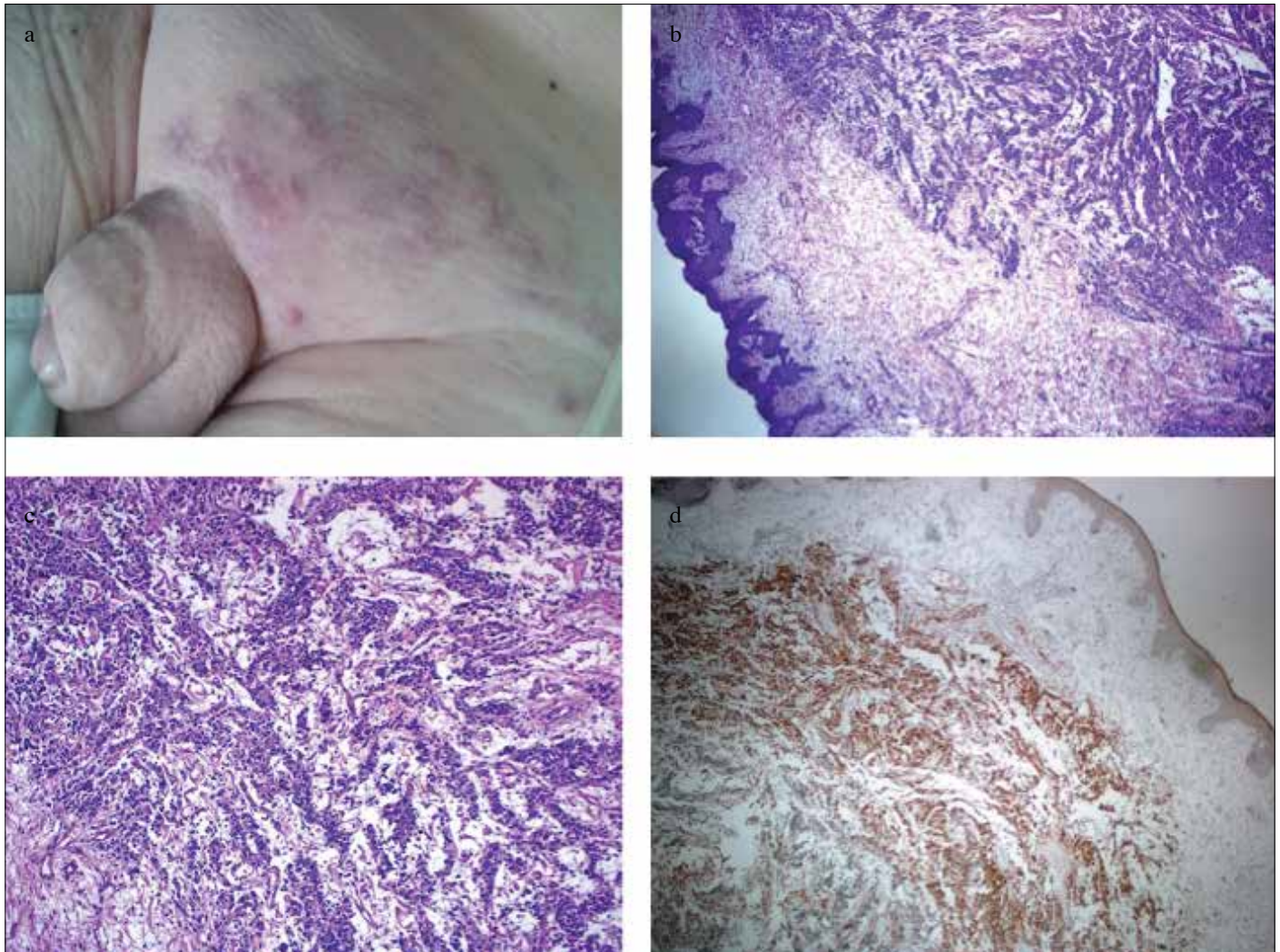


Figure 1. a-d. (a) Cutaneous metastasis. (b) The histopathological findings of skin metastasis of the prostate cancer (HEX40). (c) Tumor cells have pleomorphic and hyperchromatic nuclei. There was no cellular differentiation (HEX100). (d) Tumor cells were found to be positive for PSAP by immunohistochemical staining, (PSAPX40)

Patients with such a rare metastasis have an extremely poor prognosis because of extensive systemic involvement of diseases. After supraclavicular lymph node metastasis, mean survival times were reported as 19.8 and 29.7 months in two separate small series of case analysis and after cutaneous metastasis the mean survival was 7 months according to literature review of 78 cases.<sup>[8,10,11]</sup> First treatment option for castration-sensitive metastatic prostate cancer is androgen deprivation therapy. After development of castration resistance, docetaxel chemotherapy, abiraterone acetate, enzalutamide and sipuleucel-T can be used for the first-line treatment and for the second-line treatment abiraterone acetate, enzalutamide, cabazitaxel and radium-223 can be used.<sup>[12]</sup> One of these treatment may be chosen according to performance status, presence of symptoms or area of metastasis (only bone, only visceral or both).<sup>[12]</sup> Local excision, intral-lesional chemotherapy or radiotherapy are some options for the

treatment of cutaneous metastasis.<sup>[13]</sup> In our case, patient lived 38 months after supraclavicular lymph node metastasis and 2 months after diagnosis of cutaneous metastasis.

In our case, a patient was referred to the internal medicine clinic for supraclavicular swelling and the biopsy of supraclavicular lymph node was reported as adenocarcinoma. A lot of tests have been made to search for the primary site of tumor, but neither rectal examination nor PSA level measurements were done. The time interval between the first admission to outpatient clinic and the diagnosis of prostate cancer was 9 months. It seems as a waste of time for such a progressive cancer of prostate. Supraclavicular lymph node invasion of prostate is claimed to be a rare entity. Men with supraclavicular lymph node enlargement, physical rectal examination and PSA measurements should be kept in mind.

**Informed Consent:** Written informed consent was obtained from patient who participated in this case.

**Peer-review:** Externally peer-reviewed.

**Author Contributions:** Concept - M.Ç.; Design - M.Ç., A.Y.; Supervision - A.Y., T.Ç.; Resources - M.Ç., T.T.; Materials - M.Ç.; Data Collection and/or Processing - M.Ç.; Analysis and/or Interpretation - M.Ç., A.Y., T.T., T.Ç.; Literature Search - M.Ç., T.T.; Writing Manuscript - M.Ç., T.T.; Critical Review - M.Ç., A.Y., T.T., T.Ç.; Other - M.Ç., A.Y., T.T., T.Ç.

**Conflict of Interest:** No conflict of interest was declared by the authors.

**Financial Disclosure:** The authors declared that this study has received no financial support.

**Hasta Onamı:** Yazılı hasta onamı hastadan alınmıştır.

**Hakem Değerlendirmesi:** Dış bağımsız.

**Yazar Katkıları:** Fikir - M.Ç.; Tasarım - M.Ç., A.Y.; Denetleme - A.Y., T.Ç.; Kaynaklar - M.Ç., T.T.; Malzemeler - M.Ç.; Veri Toplanması ve/veya İşlemesi - M.Ç.; Analiz ve/veya Yorum - M.Ç., A.Y., T.T., T.Ç.; Literatür Taraması - M.Ç., T.T.; Yazıyı Yazan - M.Ç., T.T.; Eleştirel İnceleme - M.Ç., A.Y., T.T., T.Ç.; Diğer - M.Ç., A.Y., T.T., T.Ç.

**Çıkar Çatışması:** Yazarlar çıkar çatışması bildirmemişlerdir.

**Finansal Destek:** Yazarlar bu çalışma için finansal destek almadıklarını beyan etmişlerdir.

## References

1. Siegel RL, Miller KD, Jemal A. Cancer statistics, 2016. *CA Cancer J Clin* 2016;66:7-30. [\[CrossRef\]](#)
2. Lookingbill DP, Spangler N, Sexton FM. Skin involvement as the presenting sign of internal carcinoma. A retrospective study of 7316 cancer patients. *J Am Acad Dermatol* 1990;22:19-26. [\[CrossRef\]](#)
3. Hematpour K, Bennett CJ, Rogers D, Head CS. Supraclavicular lymph node: incidence of unsuspected metastatic prostate cancer. *Eur Arch Otorhinolaryngol* 2006;263:872-4. [\[CrossRef\]](#)
4. Lang S, Kansy B. Cervical lymph node diseases in children. *GMS Curr Top Otorhinolaryngol Head Neck Surg* 2014;13:Doc08.
5. Lopez F, Rodrigo JP, Silver CE, Haigentz M, Bishop JA, Strojan P, et al. Cervical lymph node metastases from remote primary tumor sites. *Head Neck* 2016;38:2374-85. [\[CrossRef\]](#)
6. Krathen RA, Orengo IF, Rosen T. Cutaneous metastasis: a meta-analysis of data. *South Med J* 2003;96:164-7. [\[CrossRef\]](#)
7. Mueller TJ, Wu H, Greenberg RE, Hudes G, Topham N, Lessin SR, et al. Cutaneous metastases from genitourinary malignancies. *Urology* 2004;63:1021-6. [\[CrossRef\]](#)
8. Wang SQ, Mecca PS, Myskowski PL, Slovin SF. Scrotal and penile papules and plaques as the initial manifestation of a cutaneous metastasis of adenocarcinoma of the prostate: case report and review of the literature. *J Cutan Pathol* 2008;35:681-4. [\[CrossRef\]](#)
9. Rattanasirivilai A, Kurban A, Lenzy YM, Yaar R. Cutaneous metastasis of prostatic adenocarcinoma: a cautionary tale. *J Cutan Pathol* 2011;38:521-4. [\[CrossRef\]](#)
10. Jones H, Anthony PP. Metastatic prostatic carcinoma presenting as left-sided cervical lymphadenopathy: a series of 11 cases. *Histopathology* 1992;21:149-54. [\[CrossRef\]](#)
11. Cho KR, Epstein JI. Metastatic prostatic carcinoma to supradiaphragmatic lymph nodes. A clinicopathologic and immunohistochemical study. *Am J Surg Pathol* 1987;11:457-63.
12. Cornford P, Bellmunt J, Bolla M, Briers E, De Santis M, Gross T, et al. EAU-ESTRO-SIOG Guidelines on Prostate Cancer. Part II: Treatment of Relapsing, Metastatic, and Castration-Resistant Prostate Cancer. *Eur Urol* 2017;71:630-42. [\[CrossRef\]](#)
13. Mak G, Chin M, Nahar N, De Souza P. Cutaneous metastasis of prostate carcinoma treated with radiotherapy: a case presentation. *BMC Research Notes* 2014;7:505. [\[CrossRef\]](#)