



# Recurrence of childhood nephrogenic adenoma in urinary bladder developed four years after previous surgery despite intravesical sodium hyaluronate therapy

*İntravezikal sodyum hyaluronat tedavisine rağmen ilk cerrahiden dört yıl sonra gelişen çocukluk çağı mesane nefrojenik adenomu rekürrensi*

Burak Özçift<sup>1</sup>, Ayper Kaçar<sup>2</sup>, Hüseyin Tuğrul Tiryaki<sup>1</sup>

## ABSTRACT

Nephrogenic adenoma (NA) is a rarely seen benign metaplastic lesion of the urinary tract. Its etiology is uncertain, but induced by chronic inflammation, irritation, and trauma. NA is located in the urinary tract, most commonly in the bladder. NA usually presents with hematuria and lower urinary tract symptoms. In the literature it is mostly seen in adults but about 30 cases of NA's have been reported in children. Treatment of intravesical lesions consists of transurethral resection (TUR) and fulguration and rarely partial or total cystectomy may be required in ineffective TUR. Recurrence rate is high during long-term follow-up. The intravesical application of sodium hyaluronate produces a protective effect on the glycosaminoglycan layer and delays or prevents its recurrence. We report a case of recurrent NA of the bladder in a pediatric male patient who was presented four years after previous surgery despite intravesical sodium hyaluronate therapy.

**Keywords:** Adenoma; intravesical; nephrogenic; sodium hyaluronate; urinary bladder.

## ÖZ

Nefronik adenoma (NA) üriner sistemin nadir görülen benign metaplastik lezyonudur. Etyolojisi kesin değildir, ancak kronik inflamasyon, irritasyon ve travma tetiklemektedir. NA üriner sistemde yerleşim göstermekte olup en sık mesanede görülmektedir. Literatürde sıklıkla erişkinlerde görülmektedir ve çocuklarda yaklaşık olarak sadece 30 olgu bildirilmiştir. NA genellikle hematüri ve alt üriner sistem semptomlarıyla kendini gösterir. Mesanede olan olgularda tedavi seçeneği transüretal rezeksiyon (TUR) ve fulgurasyondur, efektif olmayan TUR'larda ise nadiren parsiyel veya total sistektomi gerekebilmektedir. Uzun süreli takipte tekrarlama oranı yüksektir. Sodyum hyaluronatın intravezikal uygulaması glikozaminoglikan tabakasındaki koruyucu etkisi nedeniyle muhtemelen üroepitelyum üzerindeki kronik stimülasyonun negatif etkisini azaltıp, rekürrensi geciktirmekte veya önlemektedir. Biz bu makalede intravezikal sodyum hyaluronat tedavisine rağmen erkek çocuk hastada ilk cerrahiden dört yıl sonra gelişen mesane nefrojenik adenomu rekürrensi olgusunu sunduk.

**Anahtar Kelimeler:** Adenom; intravezikal; nefrojenik; sodyum hyaluronat; mesane.

## Introduction

Nephrogenic adenoma (NA) is a rare benign metaplastic lesion of urinary tract induced by chronic inflammation and irritation of the bladder mucosa, due to infection, trauma, surgery, calculi, foreign bodies, chemical agents such as BCG, anatomic anomalies, intravesical immu-

notherapy or pelvic radiation treatment. NA is located in the urinary tract, most commonly in the bladder.<sup>[1-3]</sup> Presentation in children represents only a small proportion of NA cases which has a high recurrence rate.<sup>[4]</sup> The symptoms are not specific. Clinical presentation consists of hematuria (40%), suprapubic pain (15%), flank pain (5%) or irritative voiding symptoms.<sup>[1]</sup>

<sup>1</sup>Clinic of Pediatric Urology, Ankara Child Health and Diseases Hematology Oncology Education and Research Hospital, Ankara, Turkey

<sup>2</sup>Clinic of Pathology, Ankara Child Health and Diseases Hematology Oncology Education and Research Hospital, Ankara, Turkey

**Submitted:**  
10.12.2015

**Accepted:**  
04.05.2016

**Correspondence:**  
Burak Özçift  
E-mail:  
burakozcift@hotmail.com

©Copyright 2016 by Turkish Association of Urology

Available online at  
www.turkishjournalofurology.com

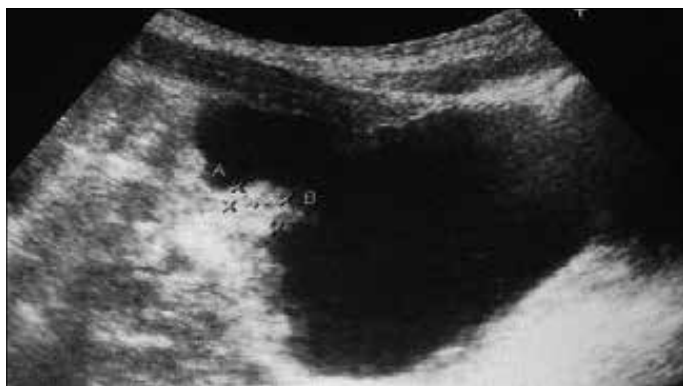

Figure 1. Ultrasonographic view of intravesical nephrogenic adenoma

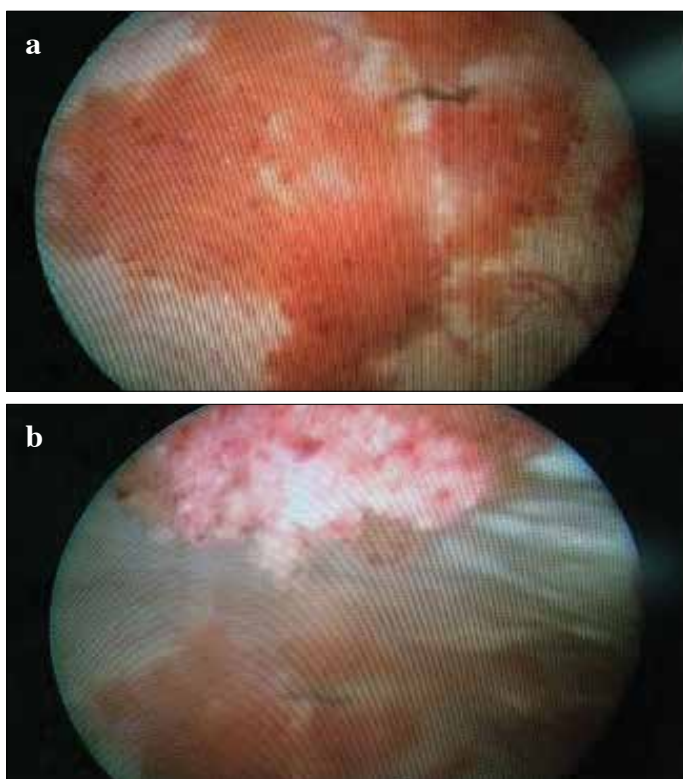


Figure 2. a, b. Cystoscopic view of multifocal exophytic nephrogenic adenoma

We report a case of recurrent NA in an eleven-year-old boy who was successfully treated by open submucosal excision and presented four years after previous surgery despite subsequent intravesical sodium hyaluronate therapy.

### Case presentation

A seven-year-old boy presented with macroscopic hematuria and severe dysuria. He had undergone left ureteroneocystostomy for vesicoureteral reflux five years ago. Physical exami-

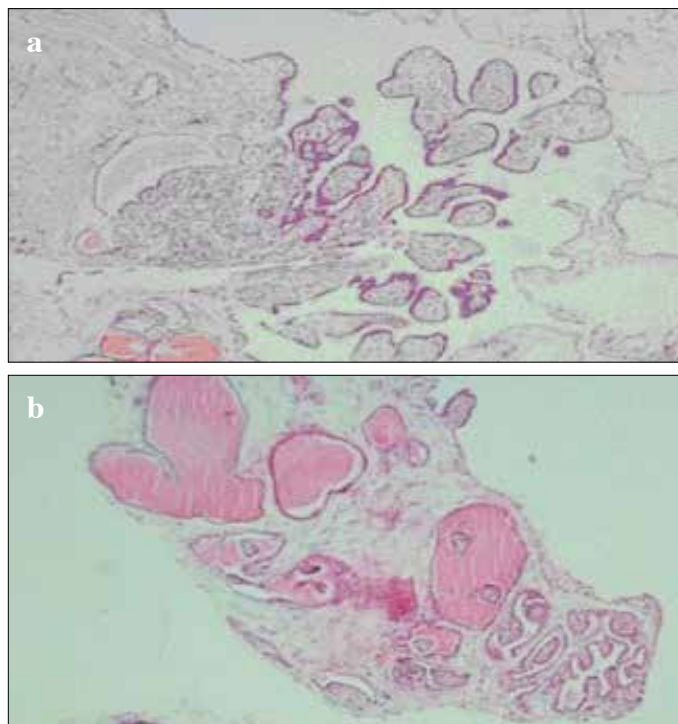


Figure 3. a, b. Papillary projections of mucosa covered by cuboidal nephrogenic epithelium

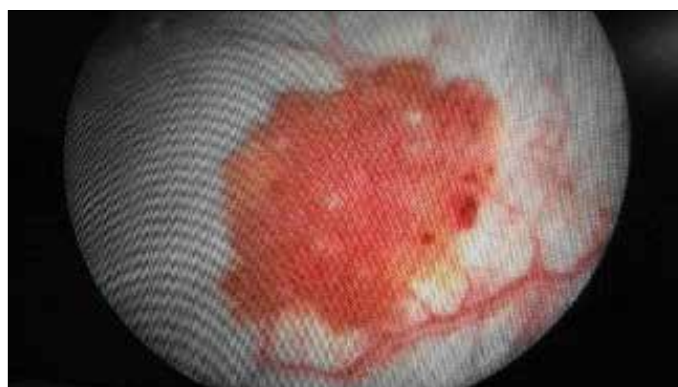


Figure 4. Cystoscopic view of recurrent nephrogenic adenoma

nation was normal. Urinalysis and urine cultures did not show urinary infections. Ultrasonography scan revealed an intravesical space-occupying lesion (Figure 1).

At the cystoscopic evaluation multifocal exophytic tumor was viewed on the anterior and peritoneal wall of the bladder and cold cup biopsy material was obtained (Figure 2a, b). Histological study revealed papillary projections of mucosa covered by cuboidal nephrogenic epithelium suggesting the diagnosis of NA (Figure 3a, b). Trial of transurethral resection (TUR) was ineffective and an open submucosal resection was performed at

which all macroscopic tumor was resected and fulgurated. In the resected specimen, multicentric lesions were located in the neighborhood of areas of cystitis cystica and cystitis glandularis (colonic metaplasia). Histopathological analysis of the specimen confirmed the diagnosis of NA.

Sodium hyaluronate solution (120 mg/50 mL) was administered intravesically in 3 doses a day at 10 day intervals. Then 4 doses were delivered at every 15 days amounting to 7 doses in 3 months. Informed consent was obtained prior to treatment.

The patient is now in his five- year follow-up performed with cystoscopic and ultrasonographic examinations. The patient was followed up by cystoscopy at 6-month intervals in the first year, then at yearly intervals. Recurrent tumors were found in control cystoscopy performed at postoperative 4<sup>th</sup> year. Two minimal sized papillary lesions were seen on the bladder wall (Figure 4), cold cup biopsy materials were obtained and tumors were fulgurated with holmium laser without complication. Histopathological evaluation confirmed the diagnosis of NA. At the 1 year follow-up after the last operation, he still remained disease-free.

## Discussion

Nephrogenic adenoma is a rare benign metaplastic lesion of the urinary tract induced by chronic inflammation and irritation of the bladder mucosa. The etiology of this entity is unclear. Davis reported the first case in the literature in 1949.<sup>[5]</sup> The term “nephrogenic adenoma” was coined by Friedman and Kuhlbeck<sup>[6]</sup> in 1950 because of the similarity of the lesion to renal tubules and suggested that it originated from mesodermal potentialities of the urothelium. Our case was associated with previous surgery and trauma (bilateral ureteroneocystostomy), similar to most other reported cases.

The nephrogenic adenoma is an uncommon benign metaplasia of the urothelial mucosa. Many specialists suggest that NA is an atypical response from the site of the regenerating epithelium due to stimulus or injury.<sup>[7]</sup> Presentation in children represents only a small proportion of NA cases. NA appears most commonly in middle-aged males.<sup>[8]</sup> It is located in the urinary tract, most commonly in the bladder (80%), urethra (15%), ureter (5%), and rarely renal pelvis (<1%).<sup>[11]</sup> Only two previous cases of urethral and 25 cases of bladder NA have been reported in children. There is a 3:1 female predominance and recurrence rate ranges between 37.5- 75% during long-term follow-up of pediatric patients.<sup>[4,9]</sup> NA is believed to have no malignant potential. Although development of malignancy from NA in adults has been reported, no case of malignant transformation has been reported in pediatric patients.<sup>[10]</sup> The presentation of NA is usually with hematuria and lower urinary tract symptoms of frequency, nocturia and urgency.<sup>[11]</sup>

Cystoscopy provides the initial visual diagnosis in suspicion of transitional cancer.<sup>[7]</sup> Macroscopic presentations in cystoscopy consist of papillary (56%), flat (34%), and polypoid (10%) lesions. NA appears like a low-grade TCC. Its common localization is on the bladder wall; and generally lesions are less than 1 cm in size and limited up to 7 cm.<sup>[3,9,11]</sup> Histopathological study is needed to distinguish it from malignancy.<sup>[12]</sup> NA generally demonstrates multiple histologic patterns, with a minority composing of small tubules or papillary projections alone. Small tubules are often surrounded by a thickened hyalinized basement membrane without any desmoplastic stromal response.<sup>[12,13]</sup>

Treatment of intravesical lesions consists of TUR and fulguration and rarely partial or total cystectomy may be required after ineffective TUR.<sup>[3,14]</sup> In our case patient underwent open submucosal resection and fulguration.

Also in some difficult cases, intravesical administration of sodium hyaluronate is used in the treatment of disseminated NA. A male patient with diffuse NA was successfully treated with sodium hyaluronate as reported in a study.<sup>[15]</sup> In our case recurrence was prevented using intravesical sodium hyaluronate which was confirmed by cystoscopy. The role of sodium hyaluronate is not clear in NA. Intravesical application of sodium hyaluronate solution possibly reduces the negative effect on chronic stimulation on uroepithelium by producing a protective effect on the glycosaminoglycan layer.<sup>[15]</sup> In our case, despite sodium hyaluronate administration NA was relapsed and the patient was treated by fulguration with holmium laser.

In conclusion, NA is a rare entity and presentation in children represents only a small proportion of NA cases. NA appears to represent a nonspecific metaplastic reaction without malignant potential. In spite of this condition, patients must be closely follow-up because of the high rate of recurrence of NA. To our knowledge there are only one or two reports of the use of intravesical sodium hyaluronate in pediatric NA. In our opinion, sodium hyaluronate prevents or delays recurrence, however the mechanism of sodium hyaluronate in the prevention of NA relapses is unclear. Control cystoscopies are recommended for early detection of relapses.<sup>[16]</sup> When NA relapses, holmium laser fulguration and cold cup biopsy are sufficient for the treatment of small sized tumors.

**Informed Consent:** Written informed consent was obtained from patients who participated in this case.

**Peer-review:** Externally peer-reviewed.

**Author Contributions:** Concept – B.Ö., H.T.T.; Design – B.Ö., H.T.T.; Supervision – B.Ö., H.T.T.; Resources – B.Ö., H.T.T., A.K.; Materials – B.Ö., H.T.T., A.K.; Data Collection and/or Processing – B.Ö., H.T.T., A.K.; Analysis and/or Interpretation – B.Ö., H.T.T.; Literature Search – B.Ö., H.T.T.; Writing Manuscript – B.Ö., H.T.T.; Critical Review – B.Ö., H.T.T.

**Conflict of Interest:** No conflict of interest was declared by the authors.

**Financial Disclosure:** The authors declared that this study has received no financial support.

**Hasta Onamı:** Yazılı hasta onamı bu olguya katılan hastalardan alınmıştır.

**Hakem Değerlendirmesi:** Dış bağımsız.

**Yazar Katkıları:** Fikir – B.Ö., H.T.T.; Tasarım – B.Ö., H.T.T.; Denetleme – B.Ö., H.T.T.; Kaynaklar – B.Ö., H.T.T., A.K.; Malzemeler – B.Ö., H.T.T., A.K.; Veri Toplanması ve/veya İşlemesi – B.Ö., H.T.T., A.K.; Analiz ve/veya Yorum – B.Ö., H.T.T.; Literatür Taraması – B.Ö., H.T.T.; Yazıyı Yazan – B.Ö., H.T.T.; Eleştirel İnceleme – B.Ö., H.T.T.

**Çıkar Çatışması:** Yazarlar çıkar çatışması bildirmemişlerdir.

**Finansal Destek:** Yazarlar bu çalışma için finansal destek almadıklarını beyan etmişlerdir.

## References

1. Weiss MA. Bladder lesion in a young man. *Contemp Urol* 2001;13:15-9.
2. Ford TF, Watson GM, Cameron KM. Adenomatous metaplasia (Nephrogenic adenoma) of urothelium. An analysis of 70 cases. *Br J Urol* 1985;57:427-33. [CrossRef]
3. Porcaro AB, D'Amico A, Ficarra V, Balzarro M, Righetti R, Martignoni G, et al. Nephrogenic adenoma of the urinary bladder: our experience and review of the literature. *Urol Int* 2001;66:152-5. [CrossRef]
4. Crook TJ, Mead Z, Vadgama B. A case series of nephrogenic adenoma of the urethra and bladder in children: review of this rare diagnosis, its natural history and management, with reference to the literature. *J Pediatr Urol* 2006;2:323-8. [CrossRef]
5. Davis TA. Hamartoma of the urinary bladder. *Northwest Med* 1949;48:182-5.
6. Friedman NB, Kuhlenbeck H. Adenomatoid tumors of the bladder reproducing renal structures (nephrogenic adenomas). *J Urol* 1950;64:657-70.
7. Zougkas K, Kalafatis M, Kalafatis P. Nephrogenic adenoma of the urinary bladder. *Int Urol Nephrol* 2004;36:513-7. [CrossRef]
8. Sanchiz CM, Ruiz JM, Fernandez PJA, Bachs JMG, Tobarra MA, Rodriguez JAV, et al. Vesical nephrogenic adenoma: an unusual presentation of a bladder tumour. *Can Urol Assoc J* 2011;5:79-80. [CrossRef]
9. Chen CS, Cheng CL. Nephrogenic adenoma of the urinary bladder: clinical experience and review of the literature. *J Chin Med Assoc* 2006;69:166-8. [CrossRef]
10. Hungerhuber E, Bach E, Hartmann A, Frimberger D, Stief C, Zaak D. Adenocarcinoma of the bladder following nephrogenic adenoma: a case report. *J Med Case Reports* 2008;2:164-7. [CrossRef]
11. Oyama N, Tanase K, Akino H, Mori H, Kanamaru H, Okada K. Nephrogenic adenoma in a patient with transitional cell carcinoma of the bladder receiving intravesical Bacillus Calmette-Guerin. *Int J Urol* 1998;5:185-7. [CrossRef]
12. Alexiev BA, LeVea CM. Nephrogenic adenoma of the urinary tract: a review. *Int J Surg Pathol* 2012;20:123-31. [CrossRef]
13. Kuzaka B, Pudełko P, Powłata A, Gornicka B, Radziszewski P. Nephrogenic adenoma of the urinary bladder: A report of three cases and a review of the literature. *Ann Transplant* 2014;19:153-6. [CrossRef]
14. Peeker R, Aldenborg F, Fall M. Nephrogenic adenoma--a study with special reference to clinical presentation. *Br J Urol* 1997;80:539-42. [CrossRef]
15. Campobasso P, Fasoli L, Dante S. Sodium hyaluronate in treatment of diffuse nephrogenic adenoma of the bladder in a child. *J Pediatr Urol* 2007;3:156-8. [CrossRef]
16. Young RH, Scully RE. Nephrogenic adenoma: a report of 15 cases, review of literature, and comparison with clear cell carcinoma of the urinary tract. *Am J Surg Pathol* 1986;10:268-75. [CrossRef]