



Approach to bulbar urethral strictures: Which technique and when?

Bulbar darıklara yaklaşım: Hangi teknik ve ne zaman?

Pankaj Joshi¹, Cevdet Kaya², Sanjay Kulkarni¹

ABSTRACT

Bulbar urethra is the most common site of anterior urethral stricture and this stricture develops secondary to idiopathic (40%), iatrogenic (35%), inflammatory (10%), and traumatic (15%) causes. Various techniques and approaches with buccal mucosal graft have been described. We wanted to describe different techniques of repair with specific advantages.

Keywords: Bulbous urethra stricture; urethra; urethroplasty.

ÖZ

Bulbar üretra anterior üretral darlıkların en sık görüldüğü lokalizasyondur. Yaklaşık olarak %40 idiopatik, %35 iyatrojenik, %10 enflamatuvar ve %15 travmatik nedenlerden kaynaklanmaktadır. Bukkal Mukoza Grefti kullanılarak tanımlanmış birçok teknik vardır. Bu derlemede farklı tekniklerin farklı avantajlarından bahsedip, her bir teknik basamak basamak tanımlandı.

Anahtar kelimeler: Bulböz üretra darlığı; üretra; üretroplasti.

Introduction

Bulbar urethra is the most common site of anterior urethral stricture.^[1] Of the bulbar urethral strictures, about 40% are idiopathic, particularly in the developed world. Some of these idiopathic cases are thought to be congenital in origin. One-third of all bulbar urethral strictures were reported to be due to instrumentation, including surgery for hypospadias, the rest of the patients have a history of infection, especially history of sexually transmitted diseases.^[2,3] Until now, various surgical techniques and approaches with or without buccal mucosal graft (BMG) have been defined for bulbar urethroplasty operations performed for bulbar urethral strictures. Most commonly used techniques include dorsal onlay,^[4] ventral onlay,^[5] Asopa dorsal inlay,^[6] double-face with BMG, and non-transaction anastomotic urethroplasty, in addition to end-to-end anastomosis.^[7] There are still some controversies in the current practices of bulbar urethral surgery about the use of oral mucosa, grafting versus anastomotic repair, use of dorsal versus ventral

placement of the graft and surgical options for patients with failed hypospadias repair.^[8] It is not surprising that these different kinds of techniques of repair have their own specific advantages. The highlighted steps and the reasoning behind the choice of each procedure in a specific condition were provided in this paper. Additionally our success rates of different techniques that we use in the patients with bulbar urethral strictures are analyzed.

Patient characteristics and diagnostic investigation

The data of the patients who had undergone bulbar urethroplasty between 1995, and 2014 in our tertiary referral center are collected retrospectively and prospectively. Patients who had difficulty in urination are evaluated in this urethroplasty center with a detailed history taking and physical examination. Initially uroflowmetry was performed and postvoiding residual volume was calculated. Patients with obstructive lower urinary tract symptoms and flow rate less than 12 mL/sec were further

¹Kulkarni Center for Reconstructive Urology, Pune, India

²Department of Urology, Marmara University School of Medicine, İstanbul, Turkey

Submitted:
18.09.2015

Accepted:
02.03.2016

Correspondence:
Pankaj Joshi
E-mail:
drpankajmjoshi@gmail.com

©Copyright 2016 by Turkish Association of Urology

Available online at
www.turkishjournalofurology.com

investigated with retrograde urethrogram (RGU) to identify the site of stricture. A voiding cystourethrogram (VCUG) was performed to augment the posterior anatomy of the urethra. In all patients with a diagnosis of bulbar urethral stricture, urethroscopy was performed intraoperatively with a narrow channel 6 F ureteroscope to provide more information about the location, caliber, and visual characteristics of the stricture. Urethroscopy can also provide insight into other pathologies such as, urethral and bladder neoplasms and stones. A diluted 50:50 saline and methylene blue which has a property to stain abnormal urethra and also useful for identifying the true lumen was injected through the meatus into the urethra. Then a perineal incision is done to perform urethroplasty. The descriptive steps of each technique are described in the following sections. Patients usually remained catheterized with indwelling 14 F all silicone catheters for 4 weeks after surgery, then the patients were discharged on low dose quinolones. Although, the subjective complexity of the case increases the need for a pericatheter RUG in occasional cases, it was not routinely performed. If an anastomotic leak developed, then the catheter was kept for another 2 weeks. After catheter removal, we performed uroflowmeter in all patients. Then the patient was requested to attend follow-up visits every 3 months for the first 2 years and then yearly. Each visit the patient underwent uroflowmeter and bladder ultrasonography for the determination of residual urine volume. Failure was defined as need for any intervention, including dilatation. The success rates of different urethroplasty techniques that we currently use in our tertiary referral center, in patients with bulbar urethral strictures are listed in Table 1.

A brief description of relevant anatomy

Anterior urethra is divided anatomically into 2 parts, namely penile and bulbar urethra. The bulbar urethra lies between penoscrotal junction and membranous urethra, which includes external urethral sphincter. The bulbar urethra is divided also into proximal, middle and distal bulbar urethra. The proximal and middle bulbar urethral parts are unique in terms of spongy tissue, which is more developed in these regions. These proximal and middle parts of the bulbar urethra are covered by the bulbospongio-cavernosus muscle, which is divided into 2 parts, and the proximal 2/3 of the muscle surrounds the urethra. We know from the anatomical studies that this proximal portion aids in the ejaculation, and also in the evacuation of last few drops of urine. The distal 1/3 parts of bulbospongio-cavernosus muscle surrounds the corpora cavernosa at the base of the penis. This distal muscle is known to compresses the deep dorsal vein of the penis to aid in erection.^[9]

We approach the dorsal surface of urethra by one of two ways. The first one is by incising bulbospongiosus muscle in midline ventrally with circumferential mobilization of the urethra. The

Table 1. The success rates of different urethroplasty techniques that we currently use in our tertiary referral center, in patients with bulbar urethral strictures

Types of surgery	Number	Median age	Success rate
Dorsal onlay	332	46.2 years	80.3%
Ventral onlay	204	46.96 years	82.10%
Anastomotic repair	16	36.69 years	86.20%
Augmented anastomotic	31	44.8 years	84.20%
Double-face	56	44.96 years	86.12%

second is by one-sided dissection, sparing the bulbospongiosus muscle and limiting the muscle division only to the distal bulbocavernosus muscle, which is a muscle preserving approach (Figure 1-6). The following section will describe, briefly, the bulbar urethroplasty techniques that we commonly use in the management of bulbar urethral strictures in our urethroplasty center in India.

1. Dorsal onlay

Dorsal onlay urethroplasty can be used mainly with the indications of either proximal, middle or distal bulbar strictures or cases of stenotic lumens with near-obliterative bulbar strictures. This method can be achieved by two well-known techniques, which are called Barbagli^[4] circumferential mobilization of the urethra, and Kulkarni^[10] one side dissection.

First of all, a midline vertical perineal incision is made. In classical Barbagli method, the bulbospongiosus muscle is incised in midline and retracted laterally. Then, the bulbar urethra is mobilized circumferentially. The landmark that may help us for complete distal dissection is the penoscrotal junction. After a 12 Fr dilatator or urethral catheter is passed through meatus to facilitate urethotomy, a dorsal and distal incisions are made at the 12 o'clock position. Dorsal urethrotomy is extended proximally up to normal urethra. Simultaneously a second team harvests an elliptical buccal mucosal graft of required length from the cheek with low postoperative oral morbidity and high patient satisfaction, according to the graft harvesting technique, described previously.^[4,11] Proximal anastomosis is made with three interrupted sutures at the 10, 12 and 2 o'clock positions. Then the graft is spread and fixed on corpora cavernosa by multiple quilting sutures. The urethra is anastomosed to the BMG with continuous suture. One side is BMG to urethral mucosa and a 14 F silicone catheter is then inserted. On the other side, buccal mucosa to corpora spongiosa sutures are taken. The muscle layer is then closed with interrupted sutures.

In Kulkarni approach, the bulbospongiosus muscle is spared by the means of incising on one side, different than the previously described method.^[10] This sparing method gives a good access to the dorsal side of the urethra, and the urethra is mobilized

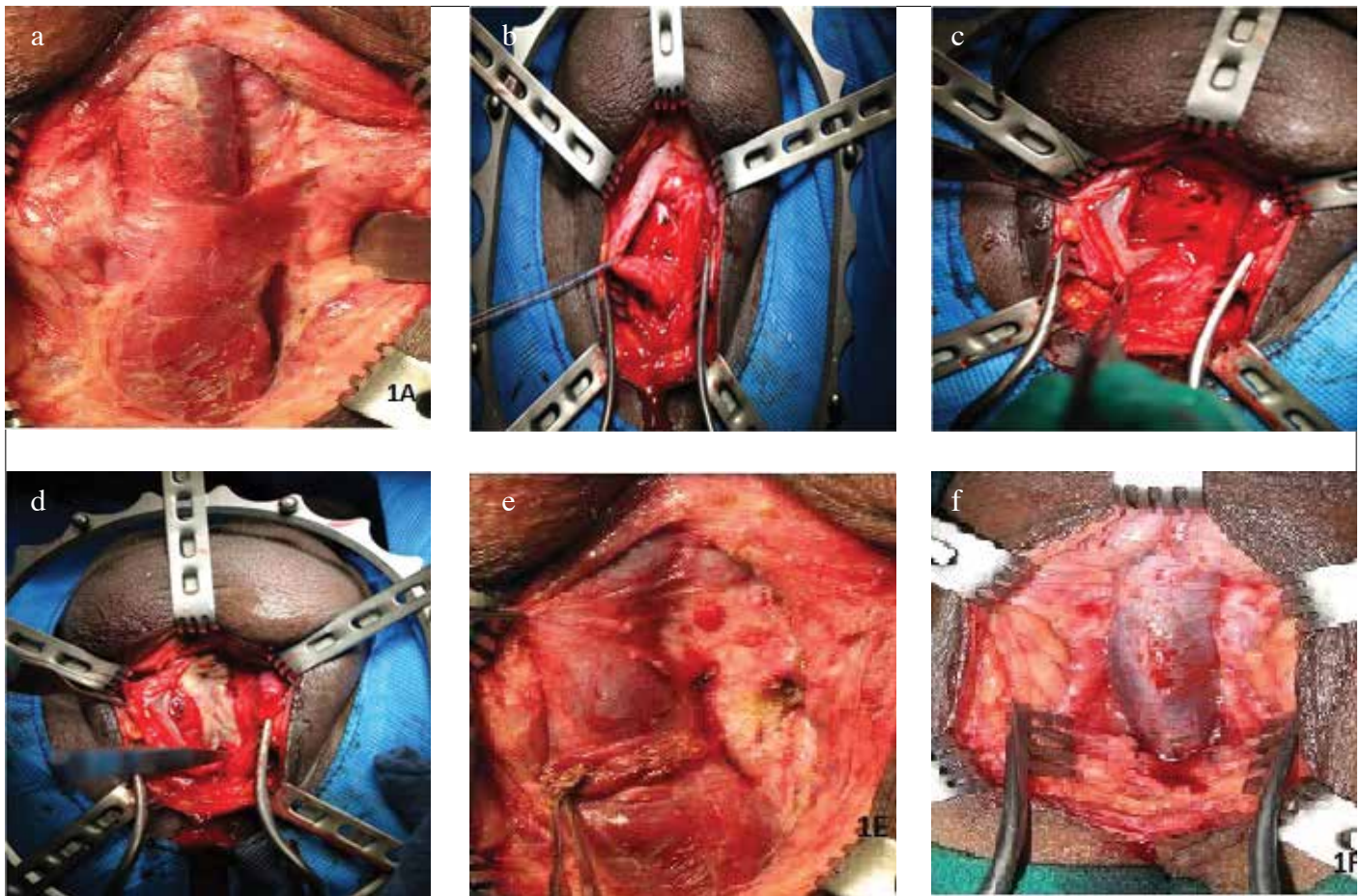


Figure 1. a-f. (a) Anatomy of Bulbospongio-cavernosus muscle. (b) Mobilising urethra circumferentially for dorsal onlay technique. (c) Incising urethra dorsally across the stricture. (d) Inserting buccal graft dorsally as onlay. (e) Incising bulbocavernosus muscle for muscle sparing technique by Kulkarni approach. (f) Urethra is mobilized on one side without circumferential dissection. The tissues on the right side are intact. Buccal graft can now be applied as dorsal onlay

on one side only. The dissection continues across the midline to 1-2 o'clock position in order to facilitate dorsal graft placement. There is no circumferential mobilization. Therefore, the neurovascular supply to the urethra on one side of patient is preserved.^[4] One of the systematic reviews by The SIU with the International Consultation on Urological Disease (ICUD) reported average success rates of 88.3% after dorsal onlay approach during the average follow-up period of 42 months.^[12]

2. Ventral onlay

The ventral graft placement urethroplasty, requiring less urethral dissection and mobilization, can be performed with either muscle cutting or muscle sparing techniques. The best indications for ventral onlay urethroplasty are proximal or middle bulbar urethral strictures only and particularly proximal strictures developing after transurethral resection of prostate surgery. It is essential that the patient should have wide spongy tissue of more than 1 cm diameter. The buccal mucosal graft is dependent on this

spongy tissue for blood supply, and if the spongy tissue is narrow, then dorsal inlay should be performed. As it is mentioned previously, the proximal or middle bulbar urethra has significant spongy tissue as compared with the distal bulbar urethra. Also there is second layer provided by bulbospongiosus muscle which is deficient distally. Hence, for all these reasons, the dorsal onlay technique should be preferred for distal strictures.^[5]

After midline vertical perineal incision is made, the bulbospongiosus muscle is incised in the midline. A 12 F dilatator is passed to aid urethrotomy incision to be made at 6 o'clock position, distal to the stricture. Then, two lateral retracting sutures are made in the spongy tissue and the mucosa of the urethra and it is incised gently in a proximal direction. One should recall that proximally, the bulbar urethra enters horizontally into the membranous region. A narrow forceps or nasal speculum is inserted, and using a sharp ophthalmic blade, a vertical incision is made in the mucosa. Indeed this technique is the ideal opera-

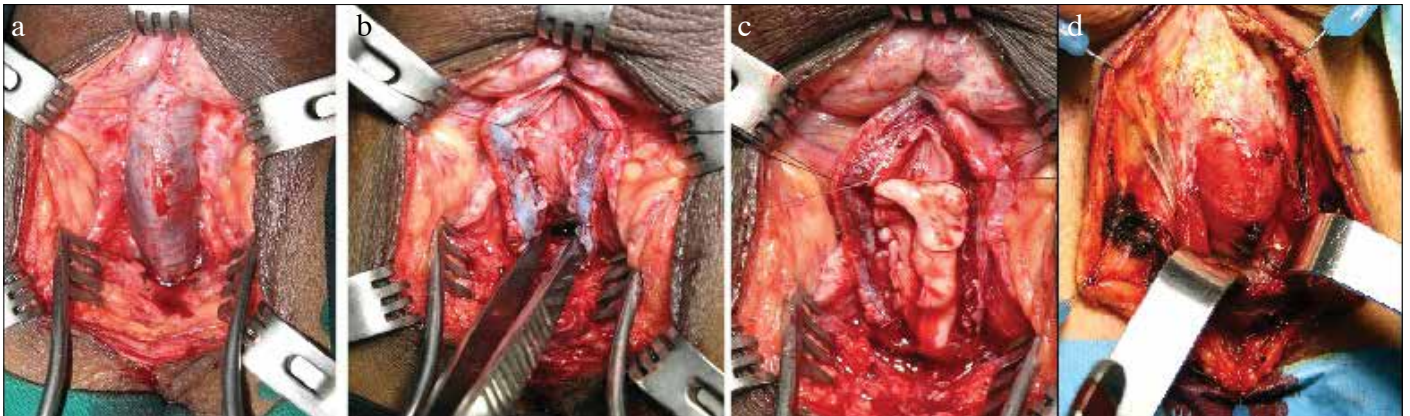


Figure 2. a-d. (a) Incising bulbospongiosus muscle in midline to access urethra ventrally. (b) Incision on urethra ventrally across stricture. (c) Placing graft ventrally as onlay. (d) Muscle sparing technique where muscle is retracted down to access the ventral aspect of urethra

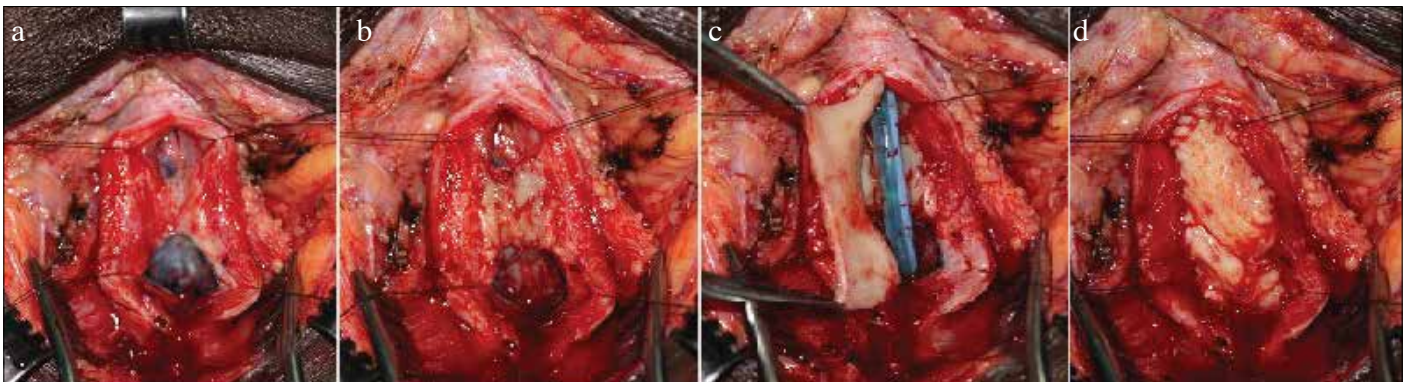


Figure 3. a-d. (a) Ventral incision in urethra showing near-obliterative bulbar stricture. (b, c) Small graft placed as dorsal inlay and large graft as ventral onlay-double- face BMG Urethroplasty. (d) Ventral onlay

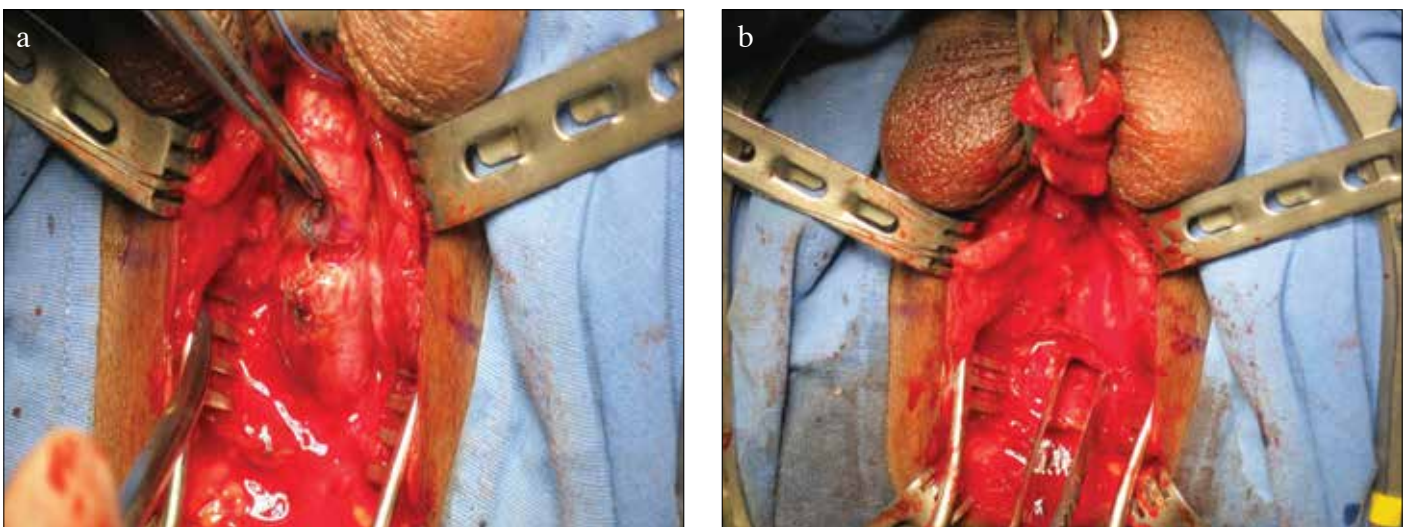


Figure 4. a, b. (a) Transecting for near-obliterative bulbar stricture. Evidence of “waist” formation seen at site of stricture. (b) Spatulating 2 ends of urethra for a wide anastomosis

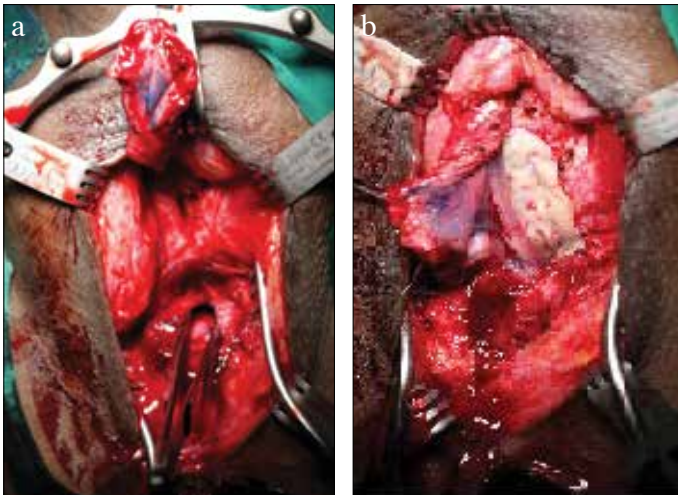


Figure 5. a, b. (a) Transecting urethra for 2 cm-long segment with near-obliterative bulbar stricture. (b) Augmentation with buccal graft dorsally and anastomosis ventrally

tion for proximal bulbar strictures developed secondary to endoscopic prostate surgery. There is minimal risk of damaging the sphincter because only the mucosal layer is incised. the mucosa. After an elliptical buccal graft is harvested, the proximal anastomosis is performed as mucosa to mucosa at 9-6-3 o'clock position, and then a 14 F silicone catheter is inserted. Including the BMG in the spongious tissue wound is closed with "reverse quilting" suture, and then the muscular layer is closed.

In the muscle sparing approach, an assistant or retractor retracts the bulbospongiosus muscle down without incising the muscle in midline. Then standard steps of ventral only BMG bulbar urethroplasty are performed. However this should be preferred for mid-bulbar urethral strictures, because it may be challenging for a beginner to perform this muscle sparing approach for proximal bulbar strictures.

There has been a debate in the case of the choice of the technique according to the dorsal or ventral placement of BMG. Although, it was reported that the ventral graft placement requiring less urethral dissection and mobilization, is technically easier, however both ventral and dorsal onlay urethroplasty were found to provide the similar success rates in several well designed studies. Well-designed studies revealed that the techniques using placement of oral mucosal grafts on the ventral or dorsal surface of the bulbar urethra were found to have similar success rates (85-93%) and the stricture recurrence.^[4,5,8]

The reported complications of bulbar urethroplasty, other than recurrence of the stricture and erectile dysfunction, are related mostly to the operation itself, rather than any specific technique, and although, there were no reported complications in

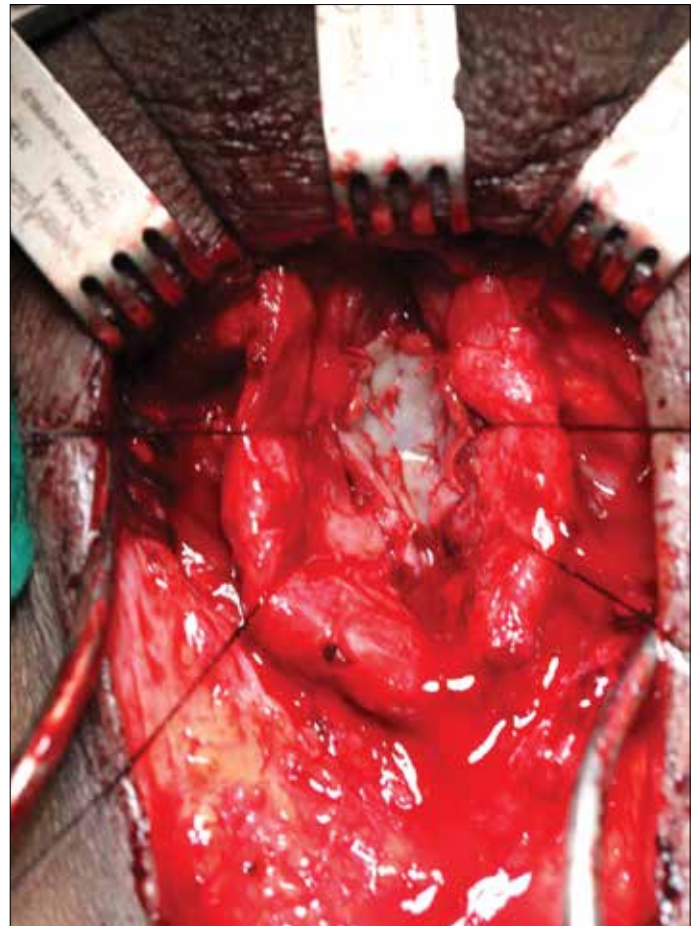


Figure 6. Asopa technique of incising bulbar urethra ventrally and inserting buccal grafts: dorsal inlay buccal mucosal graft urethroplasty

50 patients of a study by Barbagli et al.^[13], complications may include wound and urinary tract infection, perineal hematoma and nerve injuries related to the positioning of the patient.^[14]

3. Double-face BMG urethroplasty

The double-face BMG urethroplasty can be performed in two ways, either dorsal onlay with ventral inlay or ventral onlay with dorsal inlay technique. Near-obliterative bulbar strictures are the main indications of double-face graft urethroplasty. Dorsal or ventral onlay can be performed if there is at least 4-6 mm urethral plate available for anastomosis. This is equivalent to be able to do urethroscopy with narrow caliber 6 F ureteroscope or passing a guide wire. When urethral lumen is narrower than this it may require augmentation on both sides.

Initially, the approach is similar to circumferential dorsal approach as stated above. If the urethral plate is too narrow, an intraoperative decision is made to place an additional ventral graft. The unhealthy mucosa is excised on the already exposed

urethra. A small patch of buccal graft is inserted ventrally and quilted with delicate sutures. On the dorsal aspect a long buccal graft is quilted on the corpora. The anastomosis is performed as stated above. This is termed a dorsal onlay with ventral inlay.

A ventral onlay with dorsal inlay can also be done. The urethra is incised ventrally as stated above in the ventral onlay section. Unhealthy mucosa on the dorsal aspect is excised and a small buccal graft is inserted on the sponge and quilted. The procedure concludes with the ventral inlay as stated above. The type of surgery may change depending on the intraoperative findings. If the urethra was incised ventrally then dorsal inlay is performed. If urethra was incised dorsally then ventral inlay can be performed.

4. Anastomotic urethroplasty

Traumatic strictures and the redo surgery with excessive scar tissue in the corpus spongiosum are two main indications of end-to-end anastomotic urethroplasty in bulbar urethral strictures. In the current literature, primary end-to-end anastomosis is suggested for the repair of the 1-2 cm-long bulbar urethral strictures. We strongly believe in avoiding transection of the urethra unless necessary. The argument is beyond the scope of this article, but our reasoning is based upon maintaining the bulbar urethral arterial supply. Because, transecting the urethra to perform an anastomotic urethroplasty may cause vascular and neuronal damage to the urethra and penis, thus promoting post-operative sexual dysfunction. However, traumatic strictures have extensive spongiofibrosis and non-transecting approach, unfortunately, does not allow removal of the scarred tissue.^[15] There is already a clear zone of tissue wasting with poor blood flow across the corpus spongiosum. Therefore, anastomotic urethroplasty should be kept for mostly traumatic strictures and failed cases with extensive inflammation.

A 20 F Foley catheter is inserted up to the site of obstruction so as to palpate the catheter from the perineum. After a vertical midline incision through the Colles fascia, as stated before, the subcutaneous tissue is dissected away from the midline of bulbospongiosus muscle, and then the bulbospongiosus muscle is incised in midline with the same direction as the skin incision. The urethra is mobilized circumferentially, and then the zone of wasting is identified. Then the urethra is transected at the level of the scar tissue, and the scarred urethra is totally excised. The two ends of the urethra are spatulated on opposite sides. Wide spatulated anastomosis is performed over a 14 Fr Silicone catheter. Ventrally, the anastomosis is performed in a two layer technique. The first is mucosa to mucosa. The second is a sponge to sponge closure. Finally, re-approximation of bulbospongiosus muscle is performed.

5. Augmented anastomotic urethroplasty

The main indication of augmented anastomotic urethroplasty is priorly failed urethroplasty. The recurrence after anastomotic urethroplasty is ischemic and obliterative. In redo surgery transection is mostly required. The loss of urethral length may cause chordee due to further shortening of bulbar urethra. If transecting normal tissue leaves a large gap causing chordee, the gap can be augmented with BMG. We place a BMG dorsally as stated above. The spongy tissue has more elasticity ventrally and usually can accommodate the gap. The ventral aspect of urethra is slightly longer than the dorsal aspect. Hence a buccal mucosal graft is inserted dorsally. Ventrally anastomotic urethroplasty is performed in two layers as stated above.

6. Asopa dorsal inlay BMG urethroplasty

Another bulbar urethroplasty technique that is indicated in priorly failed urethroplasty is Asopa dorsal inlay BMG urethroplasty.^[6] Priorly ventral onlay urethroplasty may have been performed. Also there could be scarring of spongy tissue and surrounding tissues. Many times urethra becomes hardened and mobilizing is challenging. Another approach to such a scenario is Asopa dorsal inlay urethroplasty. Midline perineal incision is made. Urethra is incised ventrally and its margins are retracted. A deep dorsal incision is made in the urethral plate. The incision is widened. Scarred tissue is excised. A wide elliptical deficit is created. A buccal graft of appropriate size is then inserted dorsally, and fixed with multiple quilting sutures. A 14 F silicone catheter is inserted, and the urethra is closed meticulously on ventral aspect.

7. Non-transecting anastomotic urethroplasty

This is the latest addition from Dr Mundy's unit in London.^[7] The aetiology of the stricture has been found to be the main determinant of performing transection or non-transection of the urethra in bulbar urethroplasty. The concept is to avoid urethral transection in non-transecting urethroplasty, since minimising the trauma and preservation of the blood supply are the key principles for any surgical intervention.^[16] The basic approach is dorsal onlay as stated above. The main indications of non-transecting anastomotic urethroplasty are idiopathic small segment proximal bulbar urethral stricture and bulbar strictures that occurred after transurethral operation for benign prostate hyperplasia. The urethra is mobilized circumferentially and incised dorsally. The unhealthy mucosa of urethra is excised. Then mucosa to mucosa anastomosis is performed with a fine suture. This is a non transecting anastomotic urethroplasty. Depending on the situation, urethra can be closed dorsally or longitudinal opening in the urethra can be closed transversely based on Heineke Mikulicz principle or a dorsal graft can be inserted as onlay and the urethra closed.

Conclusion

It is evident that there are various ways and techniques of performing bulbar urethroplasty, additionally the superiority of one over another could not yet been clearly defined. One dealing with reconstruction surgery of the urethral strictures must be very familiar with the use of various surgical techniques to manage any condition of the urethra that might emerge at the time of urethroplasty. We may make a conclusion from the literature that there are specific indications for each type of surgery. Generally, a dorsal onlay can be performed for most urethral strictures. Ventral onlay should be performed for widely spongy mid- or proximal bulbar strictures. A one-sided dissection is a muscle sparing, vascular sparing, minimally invasive technique. Anastomotic urethroplasty should only be performed in traumatic strictures with obliterative spongiofibrosis. Double-face urethroplasty is indicated for near-obliterative strictures. Nontransection anastomotic urethroplasty is a new versatile technique for idiopathic short segment proximal bulbar strictures.

Peer-review: This manuscript was prepared by the invitation of the Editorial Board and its scientific evaluation was carried out by the Editorial Board.

Author Contributions: Concept - P.J.; Design - C.K.; Supervision - S.K.; Resources - P.J., C.K.; Materials - P.J., C.K.; Data Collection and/or Processing - P.J.; Analysis and/or Interpretation - P.J., C.K., S.K.; Literature Search - P.J., C.K.; Writing Manuscript - P.J., C.K.; Critical Review - P.J., C.K., S.K.; Other - P.J., C.K.

Conflict of Interest: No conflict of interest was declared by the authors.

Financial Disclosure: The authors declared that this study has received no financial support.

Hakem değerlendirmesi: Bu makale Editörler Kurulu'nun davetiyle hazırlandığından bilimsel değerlendirmesi Editörler Kurulu tarafından yapılmıştır.

Yazar Katkıları: Fikir - P.J.; Tasarım - C.K.; Denetleme - S.K.; Kaynaklar - P.J., C.K.; Malzemeler - P.J., C.K.; Veri Toplanması ve/veya İşlemesi - P.J.; Analiz ve/veya Yorum - P.J., C.K., S.K.; Literatür Taraması - P.J., C.K.; Yazıyı Yazan - P.J., C.K.; Eleştirel İnceleme - P.J., C.K., S.K.; Diğer - P.J., C.K.

Çıkar Çatışması: Yazarlar çıkar çatışması bildirmemişlerdir.

Finansal Destek: Yazarlar bu çalışma için finansal destek almadıklarını beyan etmişlerdir.

References

1. Hampson LA, McAninch JW, Breyer BN. Male urethral strictures and their management. *Nat Rev Urol* 2014;11:43-50. [\[CrossRef\]](#)
2. Mundy AR, Andrich DE. Urethral strictures. *BJU Int* 2011;107:6-26. [\[CrossRef\]](#)
3. Andrich DE, Mundy AR. What is the best technique for urethroplasty? *Eur Urol* 2008;54:1031-41.
4. Barbagli G, Selli C, di Cello V, Mottola A. A one-stage dorsal free-graft urethroplasty for bulbar urethral strictures. *Br J Urol* 1996;78:929-32. [\[CrossRef\]](#)
5. Morey AF, McAninch JW. When and how to use buccal mucosal grafts in adult bulbar urethroplasty. *Urology* 1996;48:194-8. [\[CrossRef\]](#)
6. Asopa HS, Garg M, Singhal GG, Singh L, Asopa J, Nischal A. Dorsal free graft urethroplasty for urethral stricture by ventral sagittal urethrotomy approach. *Urology* 2001;58:657-9. [\[CrossRef\]](#)
7. Andrich DE, Mundy AR. Non-transecting anastomotic bulbar urethroplasty: a preliminary report. *BJU Int* 2012;109:1090-4. [\[CrossRef\]](#)
8. Barbagli G, Sansalone S, Djinojic R, Romano G, Lazzeri M. Current controversies in reconstructive surgery of the anterior urethra: a clinical overview. *BJU Int* 2012;38:307-16. [\[CrossRef\]](#)
9. Mundy AR. Male urethra. In: Standring S, editor. *Gray's anatomy*. Elsevier; 2005:1295-8.
10. Kulkarni S, Barbagli G, Sansalone S, Lazzeri M. One-sided anterior urethroplasty: a new dorsal onlay graft technique. *BJU Int* 2009;104:1150-5. [\[CrossRef\]](#)
11. Zimmerman WB, Santucci RA. Buccal mucosa urethroplasty for adult urethral strictures. *Indian J Urol* 2011;27:364-70. [\[CrossRef\]](#)
12. Chapple C, Andrich D, Atala A, Barbagli G, Cavalcanti A, Kulkarni S, et al. SIU/ICUD consultation on urethral strictures: the management of anterior urethral stricture disease using substitution urethroplasty. *Urology* 2014;83(Suppl 3):S31-S47.
13. Barbagli G, Palminteri E, Guazzoni G, Montorsi F, Turini D, Lazzeri M. Bulbar urethroplasty using buccal mucosa grafts placed on the ventral, dorsal or lateral surface of the urethra: are results affected by the surgical technique? *J Urol* 2005;174:957-8.
14. Venkatesan K, Blakely S, Nikolavsky D. Surgical Repair of Bulbar Urethral Strictures: Advantages of ventral, dorsal, and lateral approaches and when to choose them. *Adv Urol* 2015;2015:397936. [\[CrossRef\]](#)
15. Barbagli G, Lazzeri M. Reconstructive urethral surgery to be addressed at 2009 GURS meeting. *AUA News* 2009;14:14.
16. Bugeja S, Andrich D, Mundy AR. Non-transecting bulbar urethroplasty. *Transl Androl Urol* 2015;4:41-50.