

Robotic sequential right adrenalectomy and zero ischemia left partial nephrectomy in a patient with synchronous pheochromocytoma and renal cell carcinoma

Eş zamanlı feokromasitoma ve renal hücreli karsinom saptanan bir olguda robotik sağ adrenalectomi ve sıfır iskemi sol parsiyel nefrektomi

Abdullah Erdem Canda¹, Özer Ural Çakıcı², Kemal Ener², Ali Fuat Atmaca¹

This case was presented as a video presentation at the EAU Robotic Urology Section 2014, 17–19 September 2014, Amsterdam, The Netherlands and awarded second prize at the Young Academic Urologist Robotic Urology session.

17–19 Eylül 2014 tarihlerinde Amsterdam'da yapılan ERUS 2014 (The EAU Robotic Urology Section) Young Academic Urologist Robotic Urology oturumunda video sunuları arasında ikincilik ödülü almıştır.

¹Department of Urology, Yıldırım Beyazıt University Faculty of Medicine, Atatürk Training and Research Hospital, Ankara, Turkey

²Clinic of Urology, Ankara Atatürk Training and Research Hospital, Ankara, Turkey

Submitted:
04.08.2014

Accepted:
27.10.2014

Available Online Date:
18.02.2015

Correspondence:
Abdullah Erdem Canda,
E-mail: erdemcanda@yahoo.com

©Copyright 2015 by Turkish Association of Urology

Available online at
www.turkishjournalofurology.com

ABSTRACT

Currently, most renal masses are detected incidentally while still small in size because of the widespread use of radiological imaging, and most pheochromocytomas are localized in the adrenal glands as unilateral lesions. A 5 x 4-cm right adrenal mass and a 19 x 13-mm exophytic left renal mass were synchronously detected by contrast enhancement on computed tomography and magnetic resonance imaging in a 47-year-old male with hypertension. The patient's preoperative serum and 24-h urine catecholamine levels were elevated. Initially, robotic transperitoneal right adrenalectomy was performed, and histopathology confirmed a 4 cm pheochromocytoma. After 3 months, transperitoneal zero ischemia robotic left partial nephrectomy was performed, and histopathology demonstrated clear cell renal cell carcinoma, Fuhrman grade II, 17 mm in size with clear surgical margins. This case indicates that sequential robotic surgery is feasible and safe as a minimally invasive approach to remove bilateral renal and adrenal masses. Zero ischemia robotic partial nephrectomy is also feasible and safe for selected small renal masses.

Key words: Pheochromocytoma; renal cell carcinoma; robotic adrenalectomy; robotic partial nephrectomy; small renal mass; zero ischemia.

ÖZ

Genellikle, renal kitlelerin çoğu, radyolojik görüntülemelerin yaygın kullanımına bağlı olarak, daha küçük boyutlarda, insidental olarak saptanmakta ve feokromositomaların çoğu, adrenal bezlerde tek taraflı olarak yerleşmektedir. Hipertansiyonu olan 47 yaşındaki bir erkek hastada, 5 x 4 cm boyutlarındaki sağ adrenal kitle ile 19 x 13 mm boyutlarında, bilgisayarlı tomografi ve manyetik rezonans görüntülemelerde kontrast tutulumu gösteren, ekzofitik sol renal kitle, eş zamanlı olarak tespit edilmiştir. Hastanın, preoperatif olarak, serumda ve 24 saatlik idrarda katekolamin seviyeleri yüksekti. Öncelikle, robotik transperitoneal sağ adrenalectomi uygulandı ve histopatolojik olarak, 4 cm boyutunda feokromositoma tespit edildi. Üç ay sonra, robotik transperitoneal sıfır-iskemi sol parsiyel nefrektomi uygulandı ve histopatolojik olarak, cerrahi sınırları temiz olan, 17 mm boyutunda, Fuhrman derece II, şeffaf hücreli renal hücreli karsinom tespit edildi. Ardışık robotik cerrahi, bilateral renal ve adrenal kitlelerde, minimal invaziv bir yaklaşım olarak uygun ve güvenilir bir yöntemdir. Aynı zamanda, seçilmiş küçük renal kitleler için, sıfır iskemi robotik parsiyel nefrektomi uygun ve güvenilirdir.

Anahtar kelimeler: Feokromositoma; renal hücreli karsinom; robotik adrenalectomi; robotik parsiyel nefrektomi; küçük renal kitle; sıfır iskemi.

Introduction

Currently, most renal masses are detected incidentally while still small in size because of the widespread use of radiological imaging modalities.^[1] Most pheochromocytomas are localized to the adrenal glands as unilateral mass lesions and more frequently involve the right adrenal gland.^[2] Minimally invasive

surgery is increasingly being applied in the management of adrenal and renal masses, including laparoscopic^[3-7] and robot-assisted laparoscopic approaches.^[8-15] Here we present a challenging case of synchronously detected right adrenal and left renal masses resected via sequential robotic right adrenalectomy and zero ischemia off-clamp left partial nephrectomy.

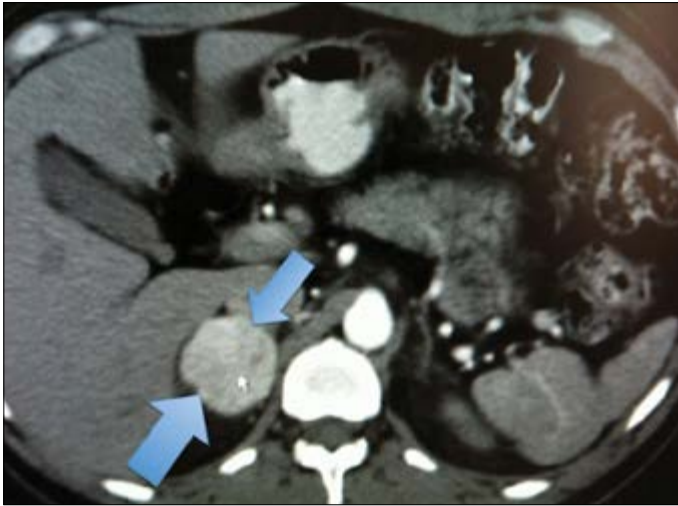


Figure 1. Appearance of a 5 x 4 cm right adrenal mass with contrast enhancement on abdominal computed tomography (arrow)

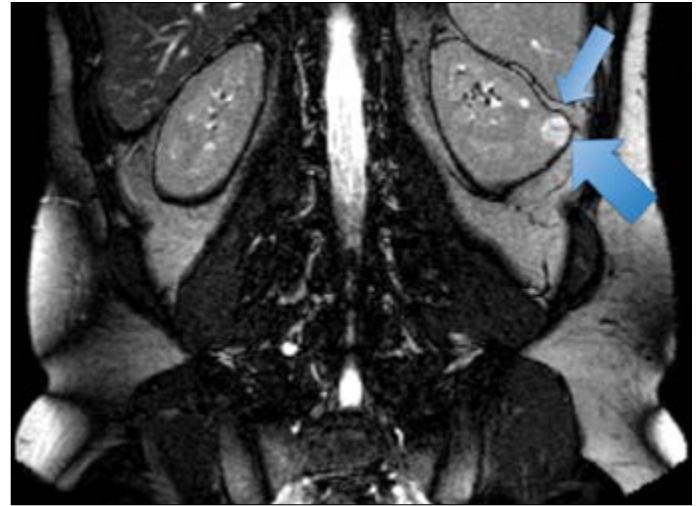


Figure 3. Appearance of a 19 x 13 mm exophytic left renal mass with contrast enhancement on magnetic resonance imaging (arrow)

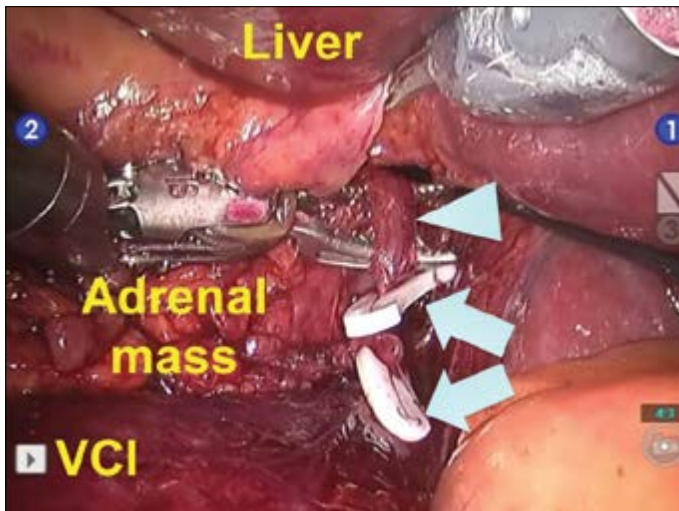


Figure 2. Appearance of robotic right adrenalectomy for pheochromocytoma

Arrowhead: adrenal vein; Arrows: polymer ligation endoclips; VCI: vena cava inferior

Case presentation

The patient provided written consent for use of his information in this report. A 47-year-old male patient who had a headache for 2 months underwent evaluation for hypertension at another institution. Abdominal ultrasound, computed tomography, and magnetic resonance imaging (MRI) with contrast enhancement revealed a 5 x 4 cm right adrenal mass and a 19 x 13 mm exophytic left renal mass (Figures 1-3). Vanillylmandelic acid, epinephrine, norepinephrine, metanephrine, and normetanephrine levels were elevated in blood and 24-h urine tests. The patient was admitted to our institution with a diagnosis of

right pheochromocytoma and a concomitant left renal mass and requested to undergo robotic surgery. His body mass index was 23.2 kg/m².

Initially, robotic transperitoneal right adrenalectomy was performed using the Da Vinci-S 4-arm surgical robotic system (Intuitive Surgical, Sunnyvale, CA, USA). Overall, 5 trocars were used (Figure 1). The adrenal mass was identified, and manipulation of the lesion was avoided to prevent intraoperative hypertension crisis. The adrenal vein draining into the vena cava inferior was identified, dissected meticulously, and cut after application of polymer ligation endoclips (Figure 1). Adrenalectomy was completed without any complications. Intraoperative blood loss was 50 cc. The postoperative follow-up was uneventful, and the patient was discharged on postoperative day 2. Histopathological diagnosis confirmed a 4-cm benign pheochromocytoma with clear surgical margins.

After 3 months, the patient was admitted for robotic left partial nephrectomy (RPN). Overall, 5 trocars were used including the 4-arm surgical robotic system (Figure 2). Initially, the renal vein and renal artery were dissected and encircled with vascular tape. An endoscopic bulldog clamp was prepared for use if needed. The renal mass was identified, and without clamping the renal pedicle, zero ischemia partial nephrectomy was completed successfully (Figure 4). A single absorbable polyglyconate barbed suture (3-0 V-Loc 180, 45 cm, 1/2 26-mm tapered needle, Covidien™) was used to perform internal and external renorrhaphy. Absorbable polyglactin suture clips (Lapra-Ty®, Ethicon Endo-Surgery) were used to anchor and secure each strand of the barbed suture on the renal capsule (Figure 5). The procedure was completed without any complications. Intraoperative blood

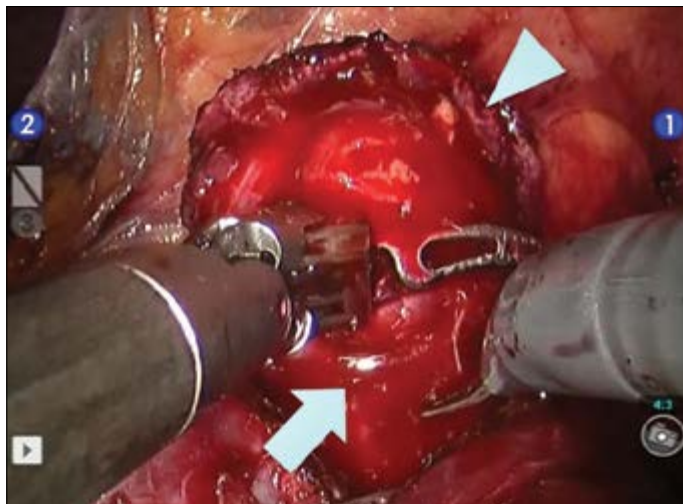


Figure 4. Zero ischemia off-clamp robotic surgical excision of the renal mass

Arrowhead: tumor; Arrow: tumor bed

loss was 100 cc. The postoperative follow-up was uneventful, and the patient was discharged on postoperative day 2. The histopathological diagnosis was clear cell renal cell carcinoma (RCC), Fuhrman grade II, 17 mm in size with clear surgical margins. At the 6-month postoperative follow-up, abdominal MRI demonstrated no tumor recurrence or any other lesion involving the left kidney as well as no abnormality in the right adrenalectomy area (Figure 6). The patient's blood pressure was within normal limits.

Discussion

Minimally invasive surgical approaches, including laparoscopic and robot-assisted laparoscopic approaches, are increasingly being applied in the surgical management of adrenal and renal masses. In our case, we used a robotic approach rather than laparoscopy because our patient particularly requested to undergo robotic surgery. However, we would like to state that adrenalectomy and partial nephrectomy procedures could have been performed via a laparoscopic approach. Regarding the laparoscopic approach, both procedures could be performed by either transperitoneal or retroperitoneal approaches depending on the surgeon's preference or patient factors. On the other hand, the robotic approach has the advantages of enabling quicker tissue dissection, reconstruction, and intracorporeal suturing with 3-dimensional optical magnification, dexterity in motion, and the ability to perform tremor-free and delicate movements with 3 independent robotic arms in addition to the camera arm for the console surgeon.

One could argue that in our case both procedures could be performed in the same session or in sequential sessions. We

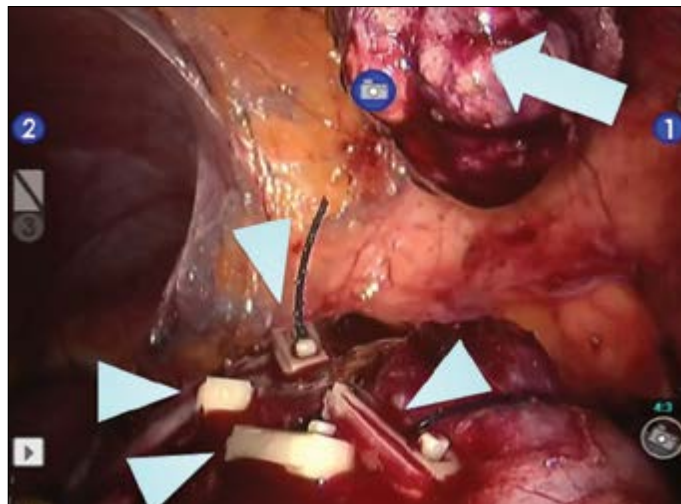

Figure 5. Completed zero ischemia robotic partial nephrectomy. An absorbable barbed suture was used for internal and external renorrhaphy, and absorbable polyglactin endoclips (arrowheads) were applied

Arrow: excised tumor

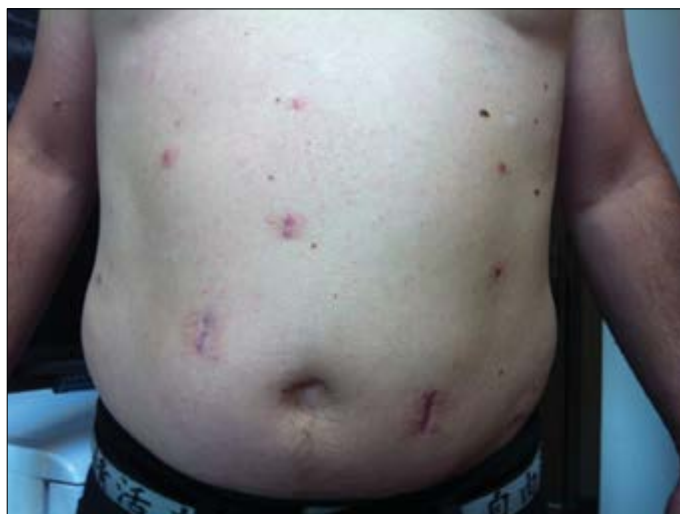

Figure 6. Appearance of the patient at the 6-month postoperative follow-up (note the healed abdominal port sites with scar tissue)

performed robotic adrenalectomy and RPN in sequential sessions, because we considered that it would be safer to perform these approaches sequentially. We believed that if postoperative bleeding occurred, it may be difficult to identify the bleeding site and thereby achieve the correct management. However, this decision also depends on the surgeon's preference. In our patient, both robotic procedures were performed by the same console surgeon (AEC). When lesions appear on the same side, such as an adrenal mass and a small renal mass located on the same side, one can perform the procedures in the same robotic

session. Performing adrenalectomy initially would be beneficial in order to obtain the desirable blood pressure before performing RPN, which would also prevent unnecessary bleeding.

More than one robotic procedure in the same robotic session has been shown to be feasible and safe in the literature. As an example, Malley et al.^[16] reported that synchronous robotic bilateral adrenalectomy is feasible and safe through a transperitoneal approach. Following completion of the procedure on one side, the patient was repositioned and the robot was dedocked in order to operate on the other side. On the other hand, Taskin et al.^[17] reported that adrenalectomy via a robotic bilateral posterior retroperitoneal approach is safe and feasible. Although successful outcomes have been reported for bilateral robotic adrenalectomy in the literature, it is not very easy to draw strict conclusions because almost all publications to date have been case reports. Successful outcomes for simultaneous bilateral RPN have also been reported in the literature, again in case reports.^[18,19] Our search found no reports related specifically to synchronous RPN and contralateral adrenalectomy in the same patient. We propose that the decision to perform these 2 procedures in the same robotic session depends on the surgeon's decision and patient factors. Certainly, simultaneous surgery would decrease the cost of the robotic approach, as cost is one of the disadvantages of robotic surgery.

The number of publications related to zero ischemia off-clamp RPN is increasing in the literature as this approach attracts attention. The zero ischemia approach avoids complete renal ischemia and is thus expected to have a positive impact on postoperative renal function. In our case, the tumor size was small (<2 cm) and the renal mass was exophytic. Therefore, the console surgeon decided to perform RPN without clamping the renal artery. The procedure was completed successfully with an intraoperative blood loss of 100 cc. The surgical robot enabled the console surgeon to perform tissue reconstruction and intracorporeal suturing easily, facilitating the procedure a great deal. However, the renal artery and vein were isolated before the surgeon began performing off-clamp RPN, and a laparoscopic bulldog clamp was ready to be applied in case any significant bleeding occurred. In a retrospective study comparing perioperative outcomes of superselective (n=58) versus main renal artery (n=69) control during RPN, Desai et al.^[20] stated that RPN with superselective vascular control enables tumor excision without any global renal ischemia. In their study, blood loss, complications, and positive surgical margin rates were low and similar to those with main artery clamping. Recently, a novel technique of eliminating renal ischemia during RPN using near-infrared fluorescence (NIRF) imaging was described.^[21] Targeted tertiary/higher-order tumor-specific arterial branches were controlled with robotic bulldog(s) or neurosurgical aneurysm micro-bulldog(s). Thereafter, indocyanine green dye was

given, and NIRF imaging was used to confirm superselective ischemia, defined as a darkened tumor/peritumor area with green fluorescence in the remaining kidney.^[21] This technique was suggested to be a safe alternative to conventional RPN with main renal artery clamping that eliminates global renal ischemia. Therefore, with the development of new technological advancements, zero ischemia RPN may be performed more frequently in suitable and selected cases.

Lastly, an excellent cosmetic outcome is another advantage of robotic surgery, particularly in comparison with open surgery, and our patient was very satisfied with the outcome of his robotic surgical experience. Although the operative areas, including those of right adrenalectomy and left partial nephrectomy, were clearly viewed via abdominal MRI at the 6-month postoperative follow-up examination in our patient, other less expensive abdominal imaging modalities, including ultrasound, also could be performed.

In conclusion, pheochromocytoma is one of the causes of hypertension that can be treated surgically, and robotic surgery is a minimally invasive surgical option. Incidentally detected small renal masses can be malignant, and both these diseases can occur simultaneously in the same patient. Zero ischemia off-clamp RPN appears to be a safe and feasible surgical approach in the surgical management of these tumors and offers the advantage of avoiding complete renal ischemia. Although synchronous robotic surgery could be applied, a sequential approach is safe and can be used depending on the surgeon's decision.

Informed Consent: Written informed consent was obtained from patient who participated in this study.

Peer-review: Externally peer-reviewed.

Author Contributions: Concept - A.E.C.; Design - A.E.C.; Supervision - A.F.A.; Funding - Ö.U.Ç.; Materials - K.E.; Data Collection and/or Processing - K.E., Ö.U.Ç.; Analysis and/or Interpretation - K.E., A.F.A.; Literature Review - Ö.U.Ç.; Writer - A.E.C.; Critical Review - A.F.A.

Conflict of Interest: No conflict of interest was declared by the authors.

Financial Disclosure: The authors declared that this study has received no financial support.

Hasta Onamı: Yazılı hasta onamı bu çalışmaya katılan hastadan alınmıştır.

Hakem değerlendirmesi: Dış bağımsız.

Yazar Katkıları: Fikir - A.E.C.; Tasarım - A.E.C.; Denetleme - A.F.A.; Kaynaklar - Ö.U.Ç.; Malzemeler - K.E.; Veri toplanması ve/veya

işlemesi - K.E., Ö.U.Ç.; Analiz ve/veya yorum - K.E., A.F.A.; Literatür taraması - Ö.U.Ç.; Yazıyı yazan - A.E.C.; Eleştirel İnceleme - A.F.A.

Çıkar Çatışması: Yazarlar çıkar çatışması bildirmemişlerdir.

Finansal Destek: Yazarlar bu çalışma için finansal destek almadıklarını beyan etmişlerdir.

References

1. Kirkali Z, Canda AE. Open partial nephrectomy in the management of small renal masses. *Adv Urol* 2008;309760.
2. Mannelli M, Ianni L, Cilotti A, Conti A. Pheochromocytoma in Italy: a multicentric retrospective study. *Eur J Endocrinol* 1999;141:619-24. [\[CrossRef\]](#)
3. Arslan M, Akin Y, Ates M, Degirmenci T, Kozacioglu Z, Ors B, et al. Changing surgical approaches for laparoscopic adrenalectomy: single-surgeon data of a 6-year experience. *Urol Int* 2013;91:304-9. [\[CrossRef\]](#)
4. Tuncel A, Balcı M, Köseoğlu E, Aslan Y, Güzel Ö, Keten T, et al. Transperitoneal laparoskopik adrenalectomi: Otuz beş hasta ile 5 yıllık deneyimimiz. *Turkish Journal of Urology* 2013;39:214-9. [\[CrossRef\]](#)
5. Erdem S, Tefik T, Mammadov A, Ural F, Oktar T, Issever H, et al. The use of self-retaining barbed suture for inner layer renorrhaphy significantly reduces warm ischemia time in laparoscopic partial nephrectomy: outcomes of a matched-pair analysis. *J Endourol* 2013;27:452-8. [\[CrossRef\]](#)
6. Tugcu V, Bitkin A, Sonmezay E, Polat H, Ilbey YO, Taşçi AI. Transperitoneal versus retroperitoneal laparoscopic partial nephrectomy: initial experience. *Arch Ital Urol Androl* 2011;83:175-80.
7. Turna B, Aron M, Gill IS. Expanding indications for laparoscopic partial nephrectomy. *Urology* 2008;72:481-7. [\[CrossRef\]](#)
8. Alkan E, Ozkanli O, Balbay D. Metachronous periadrenal Fatty tissue metastasis from contralateral renal cell carcinoma. *Case Rep Urol* 2013;2013:206078.
9. Taskin HE, Berber E. Robotic adrenalectomy. *Cancer J* 2013;19:162-6. [\[CrossRef\]](#)
10. Atug F, Kural AR. Robot-Assisted Partial Nephrectomy. *Türkiye Klinikleri J Urology-Special Topics* 2011;4:18-22.
11. Kural AR, Atug F, Tufek I, Akpınar H. Robot-assisted partial nephrectomy versus laparoscopic partial nephrectomy: comparison of outcomes. *J Endourol* 2009;23:1491-7. [\[CrossRef\]](#)
12. Boylu U, Güzel R, Turan T, Lee BR, Thomas R, Gümüş E. Predictive value of R.E.N.A.L. nephrometry score in robotic assisted partial nephrectomy. *Turkish Journal of Urology* 2011;37:81-5. [\[CrossRef\]](#)
13. Canda AE, Balbay MD. Robotic zero ischemia partial nephrectomy: step by step surgical technique with tips and tricks. *Robotic Surgery: Research and Reviews* 2014; 1: 1-9. [\[CrossRef\]](#)
14. Boylu U, Turan T. İskemisiz Robotik Parsiyel Nefrektomi Mümkün mü? *Endoüroloji Bülteni* 2013;6:165-7.
15. Bitkin A, Tuğcu V. Robot-assisted partial nephrectomy: step by step. *Üroonkoloji Bülteni* 2012;3:221-4.
16. Malley D, Boris R, Kaul S, Eun D, Muhletaler F, Rogers C, et al. Synchronous bilateral adrenalectomy for adrenocorticotrophic-dependent Cushing's syndrome. *JSLs* 2008;12:198-201.
17. Taskin HE, Aliyev S, Aksoy E, Hamrahian A, Siperstein A, Berber E. Bilateral posterior retroperitoneal robotic adrenalectomy for ACTH-independent Cushing syndrome. *Surg Laparosc Endosc Percutan Tech* 2014;24:e113-5. [\[CrossRef\]](#)
18. Giberti C, Gallo F, Schenone M, Cortese P. Simultaneous bilateral robotic partial nephrectomy: Case report and critical evaluation of the technique. *World J Clin Cases* 2014;2:224-7.
19. Jung JH, Arkoncel FR, Lee JW, Oh CK, Yusoff NA, Kim KJ, et al. Initial clinical experience of simultaneous robot-assisted bilateral partial nephrectomy and radical prostatectomy. *Yonsei Med J* 2012;53:236-9. [\[CrossRef\]](#)
20. Desai MM, de Castro Abreu AL, Leslie S, Cai J, Huang EY, Lewandowski PM, et al. Robotic partial nephrectomy with super-selective versus main artery clamping: a retrospective comparison. *Eur Urol* 2014;66:713-9. [\[CrossRef\]](#)
21. Borofsky MS, Gill IS, Hemal AK, Marien TP, Jayaratna I, Krane LS, et al. Near-infrared fluorescence imaging to facilitate super-selective arterial clamping during zero-ischaemia robotic partial nephrectomy. *BJU Int* 2013;111:604-10. [\[CrossRef\]](#)