

Prostatic adenocarcinoma with initial metastatic spread to the mandible

İlk metastaz yeri olarak mandibula tutulumu olan prostat kanseri olgusu

Özgür Çakmak¹, Hüseyin Tarhan¹, Ülkü Küçük², Yusuf Özlem İlbey¹

ABSTRACT

Prostate cancer is one of the commonest types of malignancy in males. Although prostate cancer has a propensity to metastasize to the bone, metastasis to the mandible is rare. Because of their uncommon incidence, the diagnosis of mandibular metastasis, especially those originating from the prostate, may represent a challenge both for urologists and dentists. Here we present a case of prostatic adenocarcinoma with initial metastatic spread to the mandible.

Keywords: Mandible; metastasis; prostate cancer.

ÖZ

Prostat kanseri erkeklerde sık görülen malignitelerden olup kemik metastazı yapmaya yatkın olmasına rağmen mandibula metastazı nadir görülen bir durumdur. Sık görülmemesi nedeniyle özellikle prostat kanseri orjinli mandibula metastazının teşhisi ürologlar ve diş hekimleri için sorun teşkil edebilir. Bu yazıda ilk metastaz yeri olarak mandibula tutulumu olan prostat kanseri olgusu sunmaktayız.

Anahtar kelimeler: Mandibula; metastaz; prostat kanseri.

Introduction

Prostate cancer is the second most frequently diagnosed cancer in man and 70 to 80% of men with metastatic prostate cancer have involvement of the bone.^[1-6] Although any skeletal site can be affected by prostate cancer metastasis, most metastatic lesions involve the ribs, thoracic and lumbar vertebrae, and ilium of the pelvis. However, the mandible is rarely affected by prostate cancer metastasis. Here we report a case of prostatic adenocarcinoma with initial metastatic spread to the mandible.

Case presentation

A 65-year-old male was admitted to our hospital with complaints of lower urinary tract symptoms. His laboratory findings revealed elevated serum prostate-specific antigen (PSA) levels (321 ng/mL) and the rectal examination revealed palpable nodule. Histopathological analysis of transrectal prostate biopsy confirmed prostate adenocarcinoma with a Gleason score 4 + 5 = 9. Bone scintigraphy and magnetic resonance imaging (MRI) did

not show any pathology. The patient was diagnosed with locally advanced prostate cancer without any metastasis (cT2cN0M0). His treatment was planned as a combination of radiation therapy with maximum androgen blockade. One year after the initiation of treatment nadir serum PSA level (0.66 ng/mL) was achieved. During the treatment period when his PSA level was elevated to 19.5 ng/mL despite hormonal manipulations such as antiandrogen withdrawal, bone scintigraphy was repeated and an increased uptake of the radiocontrast agent in the right mandibular region was observed (Figure 1). His physical examination also confirmed right mandibular bulging and swelling (Figure 2). The patient was admitted to Ege University Faculty of Dentistry with complaints of severe dental pain and right mandibular swelling. Regarding his past medical history, his dentist performed a biopsy procedure of the mandibular lesion, which did not respond to the medical treatment. Histopathological examination of the incisional biopsy of the mandible revealed adenocarcinoma with a Gleason score 3 + 4 = 7 (Figure 3). Chest computed tomography and abdominal MRI, performed after the biopsy,

¹Clinic of Urology, Tepecik Training and Research Hospital, İzmir, Turkey

²Clinic of Pathology, Tepecik Training and Research Hospital, İzmir, Turkey

Submitted:
27.10.2014

Accepted:
19.01.2015

Available Online Date:
18.06.2015

Correspondence:
Özgür Çakmak,
E-mail: drozgurcakmak577@yahoo.com

©Copyright 2015 by Turkish Association of Urology

Available online at
www.turkishjournalofurology.com

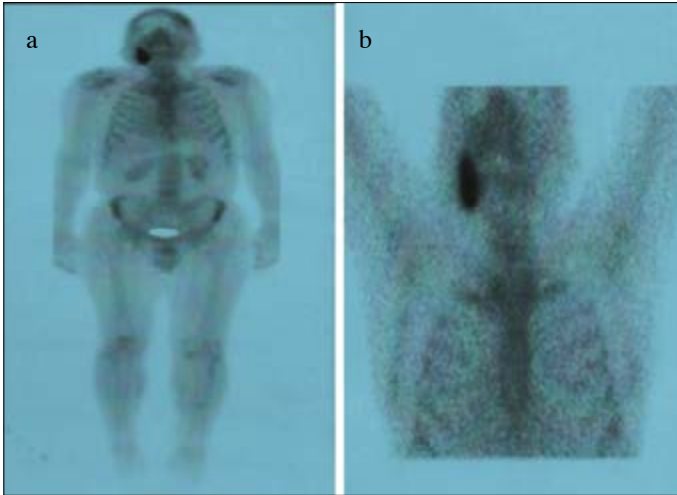


Figure 1. Bone scintigraphy images (a and b): Increased uptake of the radiocontrast agent in the right mandibular region

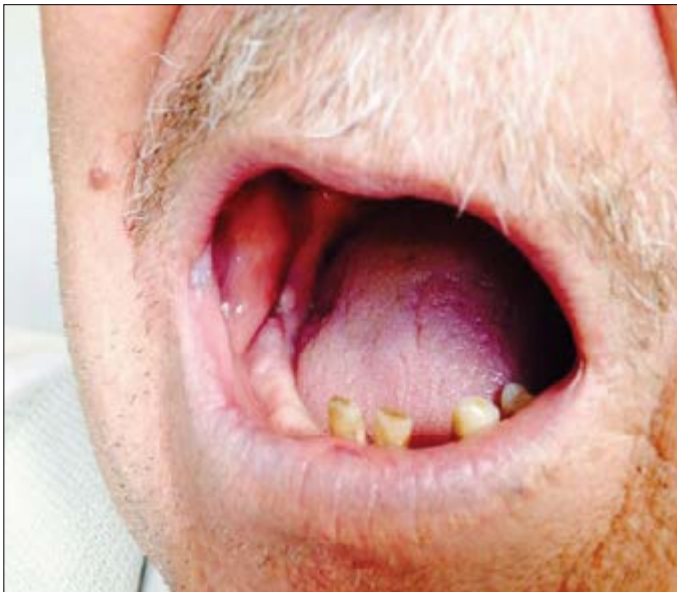

Figure 2. Photograph of the patient with right mandibular bulging and swelling

did not reveal any pathology or metastasis. After diagnosing mandibular metastasis, his treatment modality evolved to a combination of luteinizing hormone-releasing analog and bisphosphonates to prevent skeletal related events. Six months later, docetaxel-based chemotherapy was initiated because of disease progression to the castration resistant level. In addition to the mandibular metastasis, metastatic lesions in the thoracic 10th vertebrae and 10th rib were also observed on bone scintigraphy, which was repeated 1 year after the first one. The patient's current PSA level is 4.63 ng/mL, after receiving eight courses of docetaxel chemotherapy repeated at 3-week intervals.

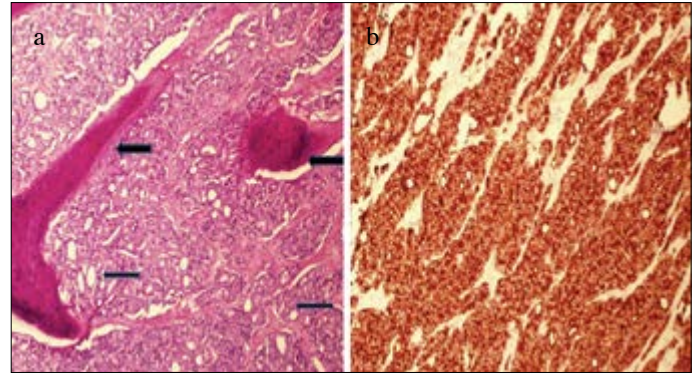


Figure 3. Small, irregular aciner configuration and an infiltrative growth pattern of tumor cells (thin arrow) between the bone trabecula (thick arrow) (H&E x100) (a). Diffuse membranous immunoreactivity with prostate-specific acid phosphatase (PSAP) (H&E x200) (b)

Discussion

Here we presented a case of prostatic adenocarcinoma with metastatic spread to the mandible. Although any skeletal site can be affected by prostate cancer, metastasis to the mandible, especially as an initial metastatic site, is not a common event.

When the metastasis is located in the mandible, the primary tumor is more likely to develop osseous metastases in other parts of the body.^[7,8] However, as observed in our case, it is also possible that the mandible is the first metastatic region of different types of malignancies.^[9] The four most common tumor sites that metastasize to the mandible in man are the lung, prostate, kidney, and liver, in descending order of frequency.^[10]

Metastasis to oral tissues are extremely rare and comprise about only 1% of all oral malignancies, whereas 61% of this type of malignancies involve the mandible.^[11,12] The presence of hematopoietic areas in the mandible can explain why the mandible is the most frequent site of metastasis among the oral tissues.^[7] In a study reviewing 390 oral cancers, Piattelli et al.^[13] stated that 22 cases (5.6%) were metastatic tumors to the jaw, prostate being the primary site of these tumors.

The clinical presentation of metastatic oral disease can vary from local swelling or pain to paraesthesia.^[14] The diagnosis of metastatic tumor of the mandible could also be challenging for dentists because the pathology can mimic the signs and symptoms of temporomandibular joint disorders.^[15,16] Any pathology, including infection, trauma, and previous dental disorders, may lead to an increased uptake of the radiocontrast agent in the mandibular region during bone scintigraphy; therefore, it is important to differentiate between bone metastasis and other pathologies in a patient with a history of prostate cancer. In the present case, although the patient's histopathological examina-

tion of prostate biopsy indicated prostate cancer, biopsy was performed of the mandibular lesion, which had not responded to medical treatment.

In conclusion, prostatic adenocarcinoma with initial metastatic spread to the mandible is a rare event. Diagnosis of metastatic tumor localized in the mandible could be challenging for urologist and dentists and it should be considered in cases with atypical symptoms, especially in patients with a history of malignant disease.

Informed Consent: Written informed consent was obtained from patient who participated in this case.

Peer-review: Externally peer-reviewed.

Author Contributions: Concept - Ö.Ç., H.T.; Design - Ö.Ç., H.T.; Supervision - Y.Ö.İ., H.T.; Funding - Y.Ö.İ., H.T., Ö.Ç.; Data Collection and/or Processing - Ö.Ç.; Analysis and/or Interpretation - Ö.Ç.; Literature Review - Ü.K.; Writer - Ö.Ç.; Critical Review - Y.Ö.İ.

Conflict of Interest: No conflict of interest was declared by the authors.

Financial Disclosure: The authors declared that this study has received no financial support.

Hasta Onamı: Yazılı hasta onamı bu olguya katılan hastadan alınmıştır.

Hakem Değerlendirmesi: Dış bağımsız.

Yazar Katkıları: Fikir - Ö.Ç., H.T.; Tasarım - Ö.Ç., H.T.; Denetleme - Y.Ö.İ., H.T.; Kaynaklar - Y.Ö.İ., H.T., Ö.Ç.; Veri toplanması ve/veya işlemesi - Ö.Ç.; Analiz ve/veya yorum - Ö.Ç.; Literatür taraması - Ü.K.; Yazıyı yazan - Ö.Ç.; Eleştirel İnceleme - Y.Ö.İ.

Çıkar Çatışması: Yazarlar çıkar çatışması bildirmemişlerdir.

Finansal Destek: Yazarlar bu çalışma için finansal destek almadıklarını beyan etmişlerdir.

References

- Center MM, Jemal A, Lortet-Tieulent J, Ward E, Ferlay J, Brawley O, et al. International variation in prostate cancer incidence and mortality rates. *Eur Urol* 2012;61:1079-92. [\[CrossRef\]](#)
- Jemal A, Bray F, Center MM, Ferlay J, Ward E, Forman D. Global cancer statistics. *CA Cancer J Clin* 2011;61:69-90. [\[CrossRef\]](#)
- Barlev A, Song X, Ivanov B, Settly V, Chung K. Payer costs for inpatient treatment of pathologic fracture, surgery to bone, and spinal cord compression among patients with multiple myeloma or bone metastasis secondary to prostate or breast cancer. *J Manag Care Pharm* 2010;16:693-702.
- Bruera ED, Sweeney C. Bone pain. In *Cancer Pain: Assessment and Management*. Edited by Bruera ED, Portenoy RK. New York: Cambridge University Press 2003;413-28. [\[CrossRef\]](#)
- Groot MT, Boeken Kruger CG, Pelger RC, Uyl-de Groot CA. Costs of prostate cancer, metastatic to the bone, in the Netherlands. *Eur Urol* 2003;43:226-32. [\[CrossRef\]](#)
- Lage MJ, Barber BL, Harrison DJ, Jun S. The cost of treating skeletal-related events in patients with prostate cancer. *Am J Manag Care* 2008;14:317-22.
- Hirshberg A, Leibovich P, Buchner A. Metastatic tumors to the jawbones: analysis of 390 cases. *J Oral Pathol Med* 1994;23:337-41. [\[CrossRef\]](#)
- Glaser C, Lang S, Pruckmayer M, Millesi W, Rasse M, Marosi C. Clinical manifestations and diagnostic approach to metastatic cancer of the mandible. *Int J Oral Maxillofac Surg* 1997;26:365-8. [\[CrossRef\]](#)
- Qiu YT, Yang C, Chen MJ, Qiu WL. Metastatic spread to mandibular condyle as initial clinical presentation: radiographic diagnosis and surgical experience. *J Oral Maxillofac Surg* 2013;71:809-20. [\[CrossRef\]](#)
- Kruse AL, Luebbers HT, Obwegeser JA, Edelmann L, Graetz KW. Temporomandibular disorders associated with metastases to the temporomandibular joint: A review of the literature and 3 additional cases. *Oral Surg Oral Med Oral Pathol Oral Radiol Endod* 2010;110:21-8. [\[CrossRef\]](#)
- Smolka W, Brekenfeld C, Büchel P, Iizuka T. Metastatic adenocarcinoma of the temporomandibular joint from the cardia of the stomach: A case report. *Int J Oral Maxillofac Surg* 2004;33:713-5. [\[CrossRef\]](#)
- Deeming G, Divakaran R, Butterworth D, Foster M. Temporomandibular region metastasis from cystosarcoma phyllodes: A case report and review of the literature. *J Craniomaxillofac Surg* 2003;31:325-8. [\[CrossRef\]](#)
- Piattelli A, Fioroni M, Rubini C. Gingival metastasis from a prostate adenocarcinoma: report of a case. *J Periodontol* 1999;70:441-4. [\[CrossRef\]](#)
- van der Waal RIF, Buter J, van der Waal I. Oral metastases: report of 24 cases. *Br J Oral Maxillofac Surg* 2003;41:3-6. [\[CrossRef\]](#)
- Mostafapour SP, Futran ND. Tumors and tumorous masses presenting as temporomandibular joint syndrome. *Otolaryngol Head Neck Surg* 2000;123:459-64. [\[CrossRef\]](#)
- Yanagi Y, Asaumi J, Maki Y, Murakami J, Hisatomi M, Matsuzaki H, et al. Incidentally found and unexpected tumors discovered by MRI examination for temporomandibular joint arthrosis. *Eur J Radiol* 2003;47:6-9. [\[CrossRef\]](#)