

Use of a microdebrider for corporeal excavation and penile prosthesis implantation in men with severely fibrosed corpora cavernosa: a new minimal invasive surgical technique

İleri derecede korporal fibrozis olgularında penil protez implantasyonu öncesi korpus kavernozum içini boşaltmak için mikrobebrider kullanımı: yeni bir minimal invaziv cerrahi teknik

İbrahim Halil Bozkurt¹, Tarık Yonguç¹, Özgü Aydoğdu¹, Tansu Değirmenci¹, Murat Arslan², Süleyman Minareci¹

ABSTRACT

Objective: To propose a new minimal invasive surgical technique using a microdebrider (shaver) to excavate the fibrosed corpora cavernosa for penile prosthesis implantation in patients with severe fibrosis.

Material and methods: Two patients with severe corporeal fibrosis were implanted with a penile prosthesis using this technique. In the first patient, fibrosis was due to neglected idiopathic ischemic priapism and the second patient had his prosthesis extruded because of erosion in another center. Both patients were counseled about the procedure and the possible complications related to the experimental nature of the technique. A written informed consent was obtained from both patients. Excavation of the corpora was performed using microdebrider in both patients.

Results: Both operations were performed successfully without any intraoperative complications, including urethral injury or perforation of the tunica. The mean operation time was 57 min. The postoperative period was uneventful without any infection, migration, erosion, or mechanical failure. The penile length was increased nearly 2 cm in both patients, and the penile girth was increased around 30% in the patient who underwent inflatable penile prosthesis implantation.

Conclusion: The microdebrider potentially provides an important advance in patients with severe corporeal fibrosis to excavate the fibrosed corpora cavernosa for penile prosthesis implantation. The main advantages include fast, safe, and effective excavation of fibrous corpora cavernosa adequate for a satisfactory penile prosthesis implantation.

Keywords: Corporeal fibrosis; microdebrider; penile prosthesis implantation; priapism.

ÖZ

Amaç: İleri derecede korporal fibrozisi olan hastalarda penil protez implantasyonu öncesi korpus kavernozum içindeki fibrotik dokunun boşaltılması için yeni bir minimal invaziv cerrahi yöntem olarak mikrobebrider tekniğini sunmak.

Gereç ve yöntemler: Bu teknik kullanılarak ileri derecede korporal fibrozisi olan iki hastaya penil protez implantasyonu gerçekleştirildi. İlk hastada fibrozis gecikmiş idiyopatik iskemik priapizme bağlı idi, ikinci hastada ise dış merkezde erozyon nedeni ile penil protezi çıkarılmıştı. Hastalar işlemin daha önce uygulanmamış bir teknik olduğu konusunda ve gelişebilecek komplikasyonlar hakkında bilgilendirildiler. Her iki hastadan da aydınlatılmış onam belgesi alındı. İki hastada da mikrobebrider kullanılarak korpora içindeki fibrotik doku boşaltıldı.

Bulgular: Her iki operasyon da tunika perforasyonu ve üretral yaralanma gibi herhangi bir intraoperatif komplikasyon olmaksızın başarılı bir şekilde gerçekleştirildi. Ortalama operasyon süresi 57 dakika idi. Postoperatif dönemde enfeksiyon, migrasyon, erozyon veya mekanik arıza gibi herhangi bir problem saptanmadı. Hastalarda penis uzunluğunda ortalama 2 cm artış saptandı, şişirilebilir penil protez takılan hastanın penis çevresinde ise yaklaşık %30 artış saptandı.

Sonuç: Mikrobebrider kullanımı ileri derecede korporal fibrozisi olan hastalarda penil protez implantasyonu öncesi korpus kavernozum içindeki fibrotik dokunun boşaltılmasında önemli avantajlar sunmaktadır. Bu tekniğin en önemli avantajı uygun penis protez implantasyonuna olanak sağlayacak şekilde korpus kavernozum içindeki fibrotik dokunun hızlı, güvenli ve etkili bir şekilde boşaltılabilmesidir.

Anahtar kelimeler: Korporal fibrozis; mikrobebrider; penil protez implantasyonu; priapizm.

¹Clinic of Urology, Bozyaka Training and Research Hospital, İzmir, Turkey

²Department of Urology, İzmir University Faculty of Medicine, İzmir, Turkey

Submitted:
19.02.2015

Accepted:
30.03.2015

Correspondence:
İbrahim Halil Bozkurt,
E-mail: ihalilbozkurt@yahoo.com

©Copyright 2015 by Turkish Association of Urology

Available online at
www.turkishjournalofurology.com

Introduction

Penile prosthesis implantation (PPI) is a well-established treatment modality for patients who do not respond to first- and second-line treatments or have found them unacceptable. This surgery can be extremely difficult in case of corporeal fibrosis due to a dilatation problem.^[1] Corporeal fibrosis may develop following the explantation of infected penile prosthesis, refractory low-flow priapism, severe penile trauma, penile irradiation, Peyronie's disease, and chronic intracavernosal injection of vasoactive drugs.^[1-6] In such cases, reinforcement of blind dilatation against a resistance may lead to perforation through the glans or urethra. Because of the problems mentioned above, most surgeons tend to implant smaller cylinders to minimize the complications that probably results in penile shortening of up to 4–6 cm.^[2] This may lead to a decrease in patient and partner satisfaction.

Over the years, multiple surgical techniques were described to remove the fibrous tissue from the corpora and facilitate penile prosthesis implantation in men with severe corporeal fibrosis. Traditionally, resection of the scar tissue via extensive corporotomies was used.^[7-9] Later, cavernotomies were introduced to excavate the scar tissue from the corpora with a smaller incision.^[10,11] The main limitations of these techniques include blind instrumentation without tactile feedback and extensive manipulation, which potentially causes a prolonged operative time and an increase in urethral injury, perforation, and postoperative infection rates. In 2007, Shaeer^[12] described optical corporotomy and trans-corporeal resection for the visually guided excavation of the fibrosed corpora cavernosa. The technique described by Shaeer et al.^[12] promised a force free and relatively safer penile prosthesis implantation.

In the present paper, we proposed a new minimal invasive surgical technique using a microdebrider (shaver) to excavate the fibrosed corpora cavernosa for penile prosthesis implantation in difficult cases with less complications and more favorable outcomes. To the best of our knowledge, our patients were the first to undergo the excavation of the fibrosed corpora cavernosa using the microdebrider device.

Materials and methods

Two patients with severe corporeal fibrosis were implanted with a penile prosthesis using this technique. In the first patient, fibrosis was due to neglected idiopathic ischemic priapism and the second patient had his prosthesis extruded because of erosion in another center. Physical examination revealed diffuse induration of the penis in both patients. On duplex examination, a heterogeneous hyperechoic tissue image along the whole corpora at both sides was detected. Severe fibrosis along both

corpora were observed in both magnetic resonance imaging and duplex ultrasonography.

Both patients were counseled about the procedure and the possible complications related to the experimental nature of the technique. A written informed consent was obtained from both patients.

Operation technique

The procedure was performed under general anesthesia in the supine position. The incision was infrapubic in first patient who was implanted with a semirigid prosthesis (Mentor® Acuforn®, Mentor Corp., Santa Barbara, CA, USA), where the incision was penoscrotal in the other who was implanted with an inflatable prosthesis (AMS Ambicor®, American Medical Systems, Minnetonka, Minnesota, USA).

Following urethral catheterization, the layers were sharply dissected and stay sutures were placed in the tunica albuginea on either side. A 1–1.5 cm incision was made to the corpora. A small tunnel was created inside the scar tissue using the Metzenbaum scissor. Hegar dilatation was not attempted because of the dense fibrotic tissue seen in the corpora. The microdebrider (Diego, Gyrus ACMI-ENT Division, Bartlett,

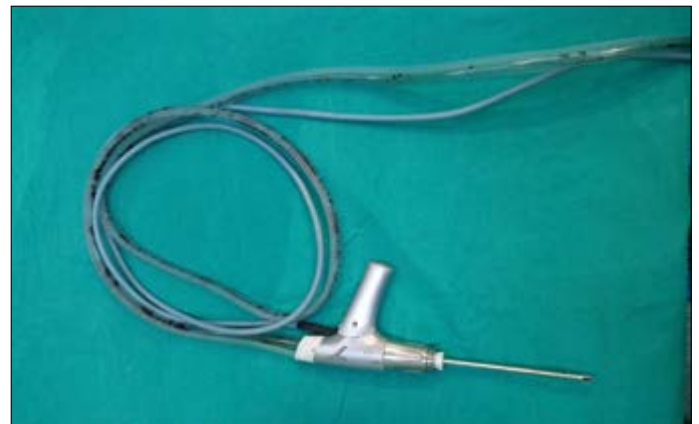

Figure 1. Microdebrider blade

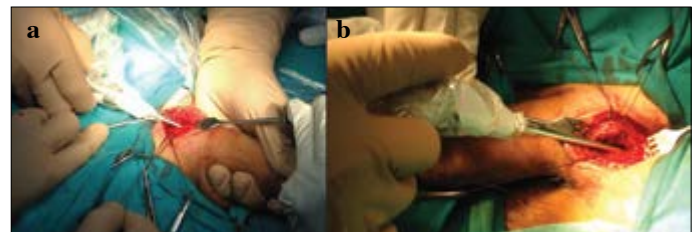


Figure 2. a,b. (a) Excavation of distal corpora. (b) Excavation of proximal corpora

Tennessee) blade (Figure 1) was introduced through the canal created with the Metzenbaum scissor, and resection was performed via the inward-outward and circular movement of the instrument (Figure 2). The morcellized pieces were sucked down through the instrument simultaneously. After creation of enough tunnel space in the corpora, the space was controlled with Hegar dilators and prosthesis was implanted.

The microdebrider (Figure 3) can be defined as a vacuum rotary dissector which spares adjacent mucosa during surgery and offers improved tactile precision and faster tissue removal without extensive manipulation. It is widely used in endoscopic sinus surgery and orthopedic surgery for arthroscopy. The microdebrider is a cylindrical, electrically powered shaver supplied with continuous suction. It consists of a console, a hand piece, and a tubing set. It basically consists of a hollow shaft with a rotating or oscillating inner cannula. Applied suction draws the soft tissue into a port on the side of the tip when it is open, and the trapped tissue is sheared off between the inner cannula and outer cannulas as the blade rotates or oscillates back. The slower the speed of the inner blade, the larger the tissue bites are because more tissue is able to be suctioned into the port before being cut off. Thus, faster the blade speed, the less aggressive the instrument. The morcellized pieces are small enough to be sucked down the instrument, aided by self-irrigating hand pieces, which provide a steady stream of saline

through a separate set of tubing. The microdebrider blades have different configurations. The straight-edged blades are less traumatic and more sparing of the adjacent tissue.

Results

Both operations were performed successfully without any intra-operative complications, including urethral injury or perforation of the tunica. The mean operation time was 57 min. The postoperative period was uneventful without any infection, migration, erosion, or mechanical failure. Both patients were discharged on the first postoperative day and resumed sexual activity within the first postoperative month. At follow-up visit after a year, both prostheses were functional and the patients were satisfied with their prosthesis. The penile length was increased nearly 2 cm in both patients, and the penile girth was increased around 30% in the patient who underwent inflatable penile prosthesis implantation.

Discussion

Penile prosthesis implantation in a patient with severe corporeal fibrosis remains a surgical challenge. The main drawbacks for this surgery are the increased rate of complications, including urethral injury, perforation of the tunica albuginea, and infection, as well as the prolonged and annoying nature of the surgical procedure. Furthermore, patient and partner satisfaction rates are low in this group because of a smaller postoperative penile girth or length.

Previously, several techniques, including complete exposure of the corpora cavernosa and excision of the scarred tissue, extensive corporotomies and the use of cavernotomes, Otis urethrotomes, and resection loops, were described for the dilatation of severely fibrotic corpora cavernosa. Forced dilatation is associated with the increased rate of complications and would only permit the implantation of a narrow malleable prosthesis. The inflatable prosthesis is not suitable in these cases because the rest scar tissue interferes with expansion. In addition, penile shortening cannot be overcome solely by corporeal dilatation and prosthesis implantation. Resection of the scar tissue is necessary in these circumstances to facilitate the implantation and achieve better outcomes, including the restoration of satisfactory penile length.

The traditional approach was the extensive wide excision of the scar tissue for the implantation of penile prosthesis in cases with severe corporeal fibrosis. In this technique, a wide corporotomy is performed, and the fibrotic corporeal tissue is dissected from the tunica albuginea. The reoperation, infection, and malfunction rates of the device were reported to be 30%-50%, 18%-30%, and 6%-12%, respectively.^[7,8,13-16] Wilson et al.^[17] reported

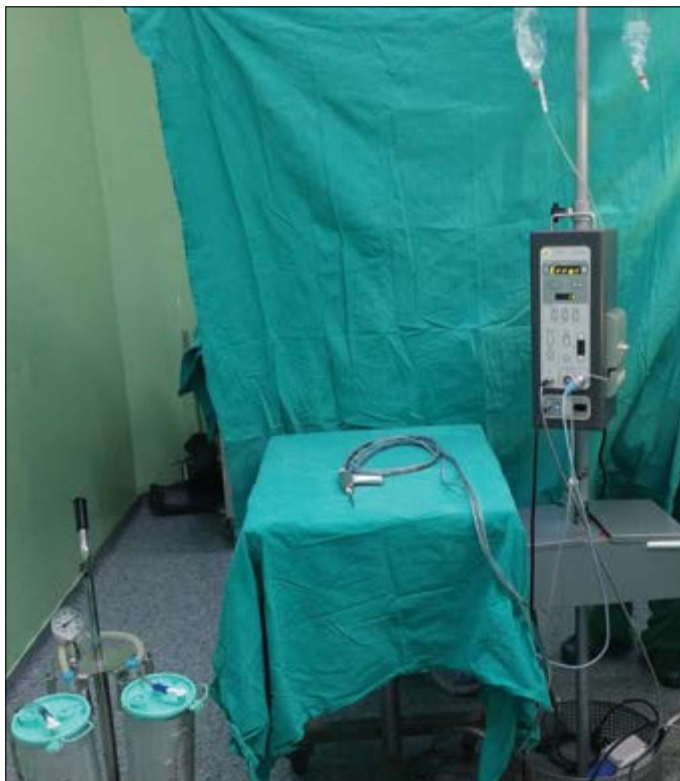

Figure 3. Microdebrider, general view

50% prosthesis survival at 1 year follow-up in 20 cases who were treated with extensive corporotomies, fibrotic tissue resection and frequent Gore-Tex grafting.

In 1999, Dhabuwala et al.^[18] reported a different technique with multiple small corporotomies and minimal scar tissue excision to enable the dilatation to be viewed under direct vision. Blunt-tipped Metzenbaum scissors, 7–11 gauge Hegar dilators, and/or Dilamezinsert dilators were used for dilatation. In this study, none of the patients developed infection after surgery; only one crural perforation was reported, which was subsequently repaired by Gore-Tex grafting.

Ghanem et al.^[19] described the corporeal counter incision technique in 2000. In this technique, a stepwise, laterally oriented dilatation was performed through corporeal counter incisions, one proximal and one distal, using Dilamezinsert and Hegar dilators. The authors stated that this technique is more suitable for the implantation of a malleable rod rather than an inflatable prosthesis because the limited and tight space may hinder inflation. Although the authors have not reported any infections postoperatively, the previous studies using blunt dilatation reported a higher rate of infection.^[20]

The corporeal excavation technique was introduced to completely excise the scar tissue.^[9,21] This technique is performed through a long corporotomy. Using Metzenbaum scissors, a plane is created between the tunica and fibrotic tissues and then the fibrotic tissue is transected from the glans to the crura. Nine patients were reported with a mean follow-up of 44 months using this technique. No intraoperative complication was reported, and the only postoperative complication was prosthesis replacement because of a cylinder failure after 46 months. Seven of nine patients required penile prosthesis with small diameter cylinders rather than standard diameter cylinders, and the mean cylinder length was correspondingly decreased (13.8 cm). The authors mentioned that an adequate preoperative counseling is critical because the decrease in penile size will not be reversed by this procedure. Although the corporeal excavation procedure seems to provide better access and easier penile prosthesis implantation, the technique is limited because of an extensive manipulation required for extended corporotomies and cutting the fibrous tissue by scissors. All of these factors negatively affect the postoperative outcomes, thereby increasing urethral injury, perforation, and infection rates.

Cavernotomes were designed to help the surgeon control the cutting and shaving action of the dilator within the confines of the corpora in cases with severe fibrosis. Cavernotomes come in a set of four or five different diameters. Cavernotomes have a smooth facet to protect the urethra and a scraping surface for

cavity development via shaving the fibrous tissue. Increasing diameters of the cavernotome are used until satisfactory dilatation is achieved. The most common complication reported with cavernotomes was tunical perforation due to blind instrumentation and extensive manipulation. Mooreville et al.^[11] reported 16 cases of penile prosthesis implantation using a cavernotome in which tunica perforation occurred in nine cases.

Park et al.^[22] described the use of electrical resection and evaporation utilizing the surgical unit for transurethral resection for excavation of the fibrous tissue in the corpora. This surgery was also performed through an extended corporotomy, which may potentially predispose to prosthesis infection and add to the operation time and effort. In addition, all extended corporotomy techniques require blind dissection, resulting in an increased risk of perforation because none of these procedures can reach deep down to the fibrous crural tissue.^[12]

In 2007, Shaeer^[12] introduced a new technique. In this technique, the same instruments and techniques were used as for endoscopic urethrotomy and transurethral resection. Firstly, an optical corporotomy is performed to create enough canal space for introducing the resectoscope. The corporotomy kit composed of a 0° or 30° lens and a blade attached on a working element within a 21 Fr sheath (diameter 6 mm). In two patients, the authors were required to use a cutting diathermy current via an appropriate tip where the fibrous tissue was too tough for the blade. After all the fibrotic tissue was resected using resectoscope under direct vision. In two patients, forceps were used to remove the resected tissues. Although they used a 26-Fr sheath (diameter 8.6 mm), they reported that the introduction of the instrument into the corpora was not difficult. The authors mentioned that the instruments were inserted through the track in a piecemeal fashion, i.e., whenever a segment was cleared, the instrument was inserted further. The authors did not report any complications, including urethral injury, perforation of the tunica, and infection. They also reported a 2-cm average increase of penile length and around 40% increase in penile girth.

Previous studies proved that undesirable postoperative outcomes may be observed because of forceful blind instrumentation, extensive exposure, prolonged operative time, devitalization of tissues resulting from persistent dilatation against resistance, and leaving unresected fibrous tissues behind.^[9,12,21,22] Therefore, we think that the ideal surgical technique that can be used in patients with severe corporeal fibrosis to excavate the fibrosed corpora cavernosa for penile prosthesis implantation should be safe, easy, fast, and effective. To the best of our knowledge, the recent study represents the first reported use of a microdebrider in patients with severe corporeal fibrosis to excavate the corpora for penile prosthesis implantation. We think our procedure is safe because the blade has a blunt tip,

and the oscillating blade is covered with a sheath that allows a controlled and safe shaving procedure. In addition, tactile feedback provided by the microdebrider instrument helps the surgeon to safely remove fibrous tissues. Moreover, the blades can be easily introduced into corpora because it is nearly half in diameter (4 mm) of the resectoscope that has been used in Shaeer's technique.^[12] The lack of the need to provide electrical energy for resection may avoid possible peripheral tissue damage. The main advantage of the microdebrider is its ability to continuously suck away blood and tissue fragments, thus proving to be a relatively easier and more expeditious procedure.^[23] In our experience, the microdebrider allows the surgeon to perform the procedure without any time lost by repeatedly switching instruments, thus decreasing the operative time. Because of the excavation of the fibrous tissue in the corpora, the length and the girth of penis were improved and surgery has become more satisfactory and effective for our patients. In the present study, the main limitation of the microdebrider was that it was used blindly without direct visualization. However, microdebriders that can be used with optics providing visualization are also available, and the use of these would probably further improve the operative time and safety. Lastly, the microdebrider was primarily designed for non-urolological surgeries and should be adapted to use for urological purposes.

In conclusion, the microdebrider potentially provides an important advance in patients with severe corporeal fibrosis to excavate the fibrosed corpora cavernosa for penile prosthesis implantation. The main advantages include fast, safe, and effective excavation of fibrous corpora cavernosa adequate for a satisfactory penile prosthesis implantation. Further studies are required to encourage the routine use of microdebriders for penile prosthesis implantation in men with severe corporeal fibrosis.

Ethics Committee Approval: Since this manuscript describes a novel surgical technique, an institutional review board was not obtained.

Informed Consent: Written informed consent was obtained from patient/patients who participated in this study.

Peer-review: Externally peer-reviewed.

Author Contributions: Concept - İ.H.B., S.M.; Design - İ.H.B., T.Y., S.M.; Supervision - Ö.A., T.D.; Funding - İ.H.B., T.D., S.M.; Materials - T.Y., Ö.A.; Data Collection and/or Processing - İ.H.B., T.Y., Ö.A.; Analysis and/or Interpretation - T.D., M.A., S.M.; Literature Review - İ.H.B., T.Y., Ö.A.; Writer - İ.H.B., T.Y., Ö.A.; Critical Review - T.D., M.A., S.M.

Conflict of Interest: The authors declared no conflict of interest.

Financial Disclosure: The authors declared that this study has received no financial support.

Etik Komite Onayı: Bu çalışma yeni bir cerrahi teknik kullanıldığından etik komite onayı alınmamıştır.

Hasta Onamı: Yazılı hasta onamı bu çalışmaya katılan hastalardan alınmıştır.

Hakem Değerlendirmesi: Dış bağımsız.

Yazar Katkıları: Fikir - İ.H.B., S.M.; Tasarım - İ.H.B., T.Y., S.M.; Denetleme - Ö.A., T.D.; Kaynaklar - İ.H.B., T.D., S.M.; Malzemeler - T.Y., Ö.A.; Veri toplanması ve/veya işlemesi - İ.H.B., T.Y., Ö.A.; Analiz ve/veya yorum - T.D., M.A., S.M.; Literatür taraması - İ.H.B., T.Y., Ö.A.; Yazıyı yazan - İ.H.B., T.Y., Ö.A.; Eleştirel inceleme - T.D., M.A., S.M.

Çıkar Çatışması: Yazarlar çıkar çatışması bildirmemişlerdir.

Finansal Destek: Yazarlar bu çalışma için finansal destek almadıklarını beyan etmişlerdir.

References

- Martinez-Salamanca JJ, Mueller A, Moncada I, Carballido J, Mulhall J. Penile prosthesis surgery in patients with corporal fibrosis: a state of the art review. *J Sex Med* 2011;8:1880-9. [\[Crossref\]](#)
- Wilson SK. Reimplantation of inflatable penile prosthesis into scarred corporeal bodies. *Int J Impot Res* 2003;15(Suppl 5):S125-8. [\[Crossref\]](#)
- Stember DS, Mulhall JP. Ischemic priapism and implant surgery with sharp corporal fibrosis excision. *J Sex Med* 2010;7:1987-90. [\[Crossref\]](#)
- Orvis BR, McAninch JW. Penile rupture. *Urol Clin North Am* 1989;16:369-75.
- Levine LA, Benson J, Hoover C. Inflatable penile prosthesis placement in men with Peyronie's disease and drug-resistant erectile dysfunction: A single center study. *J Sex Med* 2010;7:3775-83. [\[Crossref\]](#)
- Larsen EH, Gasser TC, Bruskewitz RC. Fibrosis of corpus cavernosum after intracavernous injection of phentolamine/papaverine. *J Urol* 1987;137:292-3.
- Goldstein I, Nehra A, Werner M. Technique and follow-up of sharp corporal tissue excision procedure for prosthesis implantation with bilateral severe diffuse corporeal fibrosis. *J Urol* 1995;4:360A.
- Knoll LD, Furlow WL. Corporeal reconstruction and prosthetic implantation for impotence associated with non-dilatable corporeal cavernosal fibrosis. *Acta Urol Belg* 1992;60:15-25.
- Montague DK, Angermeier KW. Corporeal excavation: new technique for penile prosthesis implantation in men with severe corporeal fibrosis. *Urology* 2006;67:1072-5. [\[Crossref\]](#)
- Rosello Barbara M, Carrion HM. Cavernotomy. *Arch Esp Urol* 1991;44:185-6.
- Mooreville M, Adrian S, Delk JR 2nd, Wilson SK. Implantation of inflatable penile prosthesis in patients with severe corporeal fibrosis: Introduction of a new penile cavernotomy. *J Urol* 1999;162:2054-7. [\[Crossref\]](#)

12. Shaeer OO, Shaeer AA. Corporoscopic excavation of the fibrosed corpora cavernosa for penile prosthesis implantation: Optical corporotomy and trans-corporeal resection, Shaeer's technique. *J Sex Med* 2007;4:218-25. [\[Crossref\]](#)
13. Knoll LD. Use of penile prosthetic implants in patients with penile fibrosis. *Urol Clin North Am* 1995;22:857-63.
14. Jarow JP. Risk factors for penile prosthetic infection. *J Urol* 1996;156:402-4. [\[Crossref\]](#)
15. Boyd S, Martin F. Simultaneous ultrex penile prosthesis re-implantation and Gore-Tex grafting corporoplasty functional outcome of a surgical challenge. *J Urol* 1995;153.
16. Fishman IJ, Scott FB, Light JK. Experience with inflatable penile prosthesis. *Urology* 1984;23:86-92. [\[Crossref\]](#)
17. Wilson SK, Terry T, Delk JR. Improved implant survival in patients with severe corporal fibrosis: A new technique without necessity of grafting. *J Urol* 1995;153.
18. Rajpurkar AA, Li H, Dhabuwala CB. Penile implant success in patients with corporal fibrosis using multiple incisions and minimal scar tissue excision. *Urology* 1999;54:145-7. [\[Crossref\]](#)
19. Ghanem HH, Ghazy SS, El-Melie AA. Corporeal counter incisions: a simplified approach to penile prosthesis implantation in fibrotic cases. *Int J Impot Res* 2000;12:153-6. [\[Crossref\]](#)
20. Fallon B, Ghanem H. Infected penile prosthesis: Incidence and outcomes. *Int J Impot Res* 1989;1:175-80.
21. Fishman IJ. Corporeal reconstruction procedures for complicated penile implants. *Urol Clin North Am* 1989;16:73-90.
22. Park JK, Kim HJ, Kang MH, Jeong YB. Implantation of penile prosthesis in a patient with severe corporeal fibrosis induced by cavernosal injection therapy. *Int J Impot Res* 2002;14:545-6. [\[Crossref\]](#)
23. Bruggers S, Sindwani R. Innovations in microdebrider technology and design. *Otolaryngol Clin N Am* 2009;42:781-7. [\[Crossref\]](#)