

Montelukast prevents testes against ischemia-reperfusion injury through suppression of iNOS expression

Montelukast testiste iskemi-reperfüzyona bağlı oluşan hasarı iNOS ekspresyonunu baskılayarak önlemektedir

Mesrur Selçuk Sılay¹, Hale Toklu², Ayşim Özağarlı³, Mustafa Aydın⁴, Şermin Tetik⁵, Göksel Şener², Cengiz Miroğlu⁴, Muammer Kendirci⁴

ABSTRACT

Objective: To elucidate the mechanism of a possible protective effect of montelukast against testicular ischemia/reperfusion (I/R) injury.

Material and methods: Fifty-one adult male Wistar-Albino rats were randomly assigned into 6 groups; sham + saline (S), sham + montelukast (M), I/R + S, I/R + S 30', I/R + M and I/R + M 30'. Saline or montelukast (10 mg/kg) was intraperitoneally administered 30 minutes prior to (S 30', M 30') and during detorsion (I/R + S, I/R + M) in the I/R groups. The I/R groups underwent 2 hours of ischemia followed by 4 hours (early-term) of reperfusion in unilateral testes. Half of the rats underwent 24 hours (late-term) of reperfusion to investigate long-term effects. Testicular tissue samples were examined for biochemical and histopathological parameters. Germ cell apoptosis was evaluated using apoptosis-activating factor 1 (Apaf-1). Inducible nitric oxide synthase (iNOS) activity was analyzed in late-term reperfusion groups. Spermatogenic functions were assessed for each testis based on the Johnsen criteria.

Results: Unilateral I/R caused a significant increase in serum TNF- α levels in the early-term group compared to the sham groups. Malondialdehyde levels and myeloperoxidase activity were found to be elevated in the I/R groups and accompanied with a significant decrease in glutathione levels when compared to the sham groups. I/R significantly increased iNOS activity and germ cell apoptosis compared to the sham groups. Montelukast treatment significantly reversed all of these parameters and achieved comparable results with the sham groups. Finally, spermatogenic indices were similar for the bilateral testes between all groups.

Conclusion: Montelukast exerts protective effects against testicular I/R injury by inhibiting neutrophil activity, reversing the oxidative stress markers, decreasing iNOS activity and attenuating apoptosis.

Key words: Ischemia; montelukast; reperfusion; testis; torsion.

ÖZET

Amaç: Montelukast, sisteinil lökotrien-1 reseptörünü spesifik ve geri dönüşümlü olarak inhibe eden, selektif bir lökotrien D-4 reseptör antagonistidir. Çalışmamızda montelukastın iskemi-reperfüzyon (I/R) sonucu testiste oluşan oksidatif hasar üzerine olan etkilerini araştırmayı amaçladık.

Gereç ve yöntemler: Sekiz haftalık 51 adet erişkin erkek Wistar-Albino sıçan randomize edilerek 6 gruba ayrıldı; sham + serum fizyolojik (SF), sham + montelukast (M), I/R + SF, I/R + SF 30', I/R + M ve I/R + M 30'. I/R gruplarında SF veya montelukast, detorsiyondan 30 dakika önce (SF 30', M 30') veya detorsiyon esnasında (I/R + SF, I/R + M) 10 mg/kg intraperitoneal olarak verildi. Dokulardaki iNOS düzeyleri ve apoptoz dereceleri de immünohistokimyasal yöntemlerle belirlendi. Spermatojenik fonksiyonlar Johnsen kriterlerine göre değerlendirilerek her testis için ortalama skorlar hesaplandı. Elde edilen tüm ordinal, numerik ve nominal veriler, Mann-Whitney U, Dunn testi ve Kruskal Wallis testleriyle yerine göre karşılaştırıldı.

Bulgular: Montelukast tedavisi verilmeyen I/R gruplarında, sham gruplarına kıyasla TNF- α düzeylerinin istatistiksel anlamlı olarak arttığı ve montelukast tedavisinin bu artışı anlamlı şekilde önleyerek sham gruplarına benzer düzeye getirdiği tespit edildi. Malondialdehit (MDA) ve miyeloperoksidaz (MPO) düzeylerinin, montelukast tedavisi verilmeyen I/R gruplarında sham gruplarına kıyasla anlamlı olarak yükseldiği saptanırken, bu parametrelerin montelukast tedavisiyle düşürüldüğü belirlendi (p<0,05). Ayrıca glutatyon (GSH) düzeylerinin, montelukast tedavisi verilmeyen I/R gruplarında sham gruplarına kıyasla anlamlı olarak düştüğü gözlenirken montelukast tedavisinin bu durumu önlediği saptandı (p<0,05). İmmünohistokimyasal olarak değerlendirilen iNOS ekspresyon skorlarının, I/R SF 30' grubunda sham gruplarına kıyasla anlamlı olarak arttığı izlenirken, montelukast tedavisinin bu değerleri sham gruplarına benzer düzeylere indirdiği belirlendi. İmmünohistokimyasal olarak değerlendirilen germ hücre apoptozunun bütün parametrelerinin, montelukast tedavisi verilmeyen I/R gruplarında sham gruplarına kıyasla anlamlı olarak yükseldiği saptanırken, montelukast tedavisinin istatistiksel anlamlı olarak apoptozu önlediği saptandı (p<0,05).

Sonuç: Montelukast, testiste I/R'ye bağlı olarak gelişen hasarı azaltmaktadır. Bu deneysel çalışmanın verileri, montelukast tedavisinin testis torsiyonunda kullanılabilirliğinin araştırılması gerektiğini ortaya koymaktadır.

Anahtar kelimeler: İskemi; montelukast; reperfüzyon; testis; torsiyon.

¹Department of Urology, Bezmialem Vakıf University Faculty of Medicine, İstanbul, Turkey

²Department of Pharmacology, Marmara University School of Pharmacy, İstanbul, Turkey

³Department of Pathology, Şişli Etfal Training and Research Hospital, İstanbul, Turkey

⁴Department of Urology, Şişli Etfal Training and Research Hospital, İstanbul, Turkey

⁵Department of Biochemistry, Marmara University Faculty of Medicine, İstanbul, Turkey

Submitted:
09.06.2014

Accepted:
21.08.2014

Correspondence:
Mesrur Selçuk Sılay,
Department of Urology,
Bezmialem Vakıf University
Faculty of Medicine,
İstanbul, Turkey
Phone: +90 505 645 40 05
E-mail: selcuksilay@gmail.com

©Copyright 2014 by Turkish Association of Urology

Available online at
www.turkishjournalofurology.com

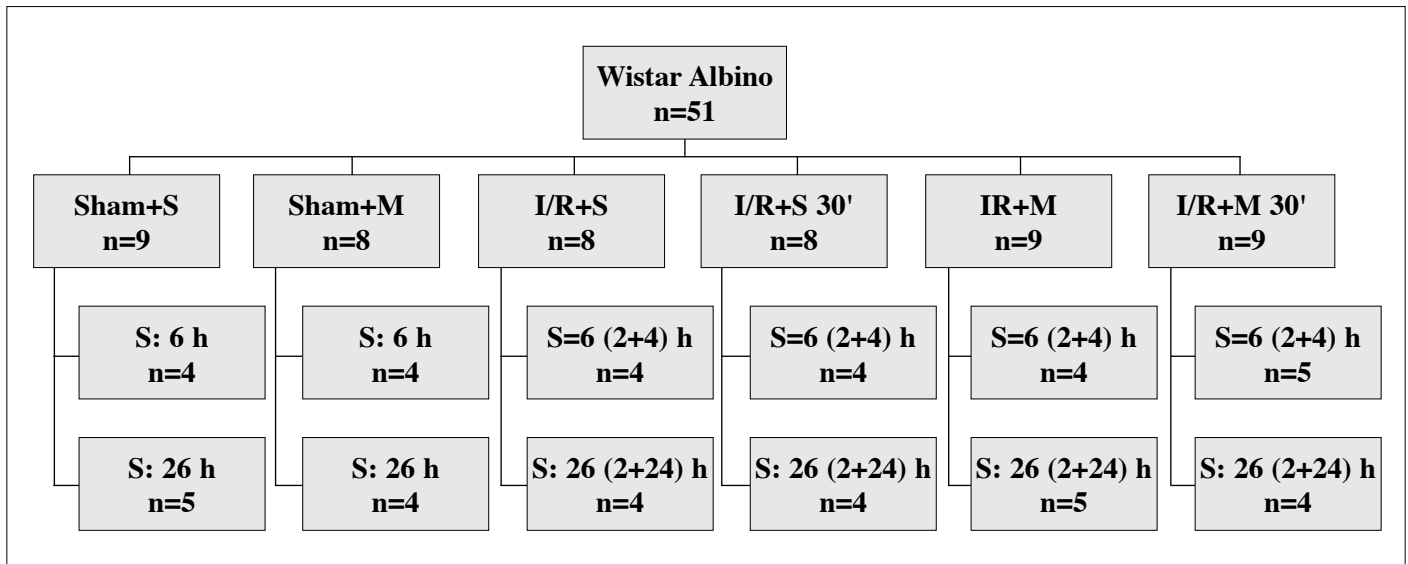


Figure 1. The scheme of the study groups

+S: saline; +M: montelukast; S: sacrifice time; R: reperfusion time

*Ischemia period was 2 hours for the I/R groups

Introduction

Testicular torsion is a surgical emergency affecting male newborns, children and adolescents. The incidence has been reported as high as 1/4000 in males up to 25 years old.^[1] Early recognition and treatment of the disease is of the utmost importance to preserve testicular function and save the testis from orchiectomy. However, even after surgical detorsion of the testis, the salvage rates are between 42 and 88%, and the long-term function of these testes are unknown.^[2] Therefore, many pharmaceutical agents are under investigation that can be used as an adjunct to surgery in order to improve the testicular salvage rates.^[3-8]

Montelukast is a selective antagonist of cysteinyl leukotriene receptor 1 (CystLT1) and an anti-oxidant used as an anti-asthmatic drug in the clinical setting. It has been previously reported in experimental studies that it preserves the kidney and the bladder from ischemia/reperfusion damage.^[9,10] However, there has been no appropriately designed study regarding the effect of montelukast on testicular torsion models. We aimed to elucidate the exact mechanism of the possible protective effect of montelukast on testicular ischemia/reperfusion injury in an experimental model.

Material and methods

The study was approved by the animal care and use committee of our institution. Fifty-one male adult Wistar albino rats (300-350 g) were randomly assigned into 6 groups:

1. Sham + saline (S),
2. Sham + montelukast (M),
3. Ischemia-reperfusion (I/R) + S.
4. I/R + S 30',
5. I/R + M,
6. I/R + M 30'.

The scheme of the study protocol is summarized in Figure 1. Animals were placed in an air-conditioned room with 12-h light and dark cycles. The temperature ($22\pm 2^\circ\text{C}$) and the humidity (65-70%) of the room were standardized.

Surgical procedure

Anesthetized (ip. ketamine and xylazine; 75 mg/kg and 10 mg/kg, respectively) rats were positioned in a supine position. Under sterile conditions, the left testis was exteriorized through a median raphe incision. The gubernaculum was divided and the left testis was rotated 720° in counterclockwise direction. Then, the testis was fixed to the scrotum with a 5.0 prolene suture. The incision was closed, and the testis was left in this torsion position for 2 hours. Afterwards, the torsion was repaired by opening the incision and counterrotating the testis to the natural position and joining the gubernacular stumps. At the time of repair, the testis was examined to ensure that it had remained in torsion. In addition, the testes were examined 5 minutes after the counter-rotation to evaluate the quality of detorsion. The testes remained stable within the scrotum until the time of tissue collection. Rats were decapitated 4 or 24 hours after reperfusion according to the randomization groups. Then, the trunk blood was collected, and tissue from both testes was removed for analysis.

Saline or montelukast (10 mg/kg) was intraperitoneally administered 30 minutes prior to (S 30', M 30') or during detorsion (I/R + S, I/R + M) in the I/R groups. The I/R groups underwent 2 hours of ischemia followed by a 4 hour (early-term) reperfusion in the unilateral testes. Moreover, half of the rats underwent a 24 hour (late-term) reperfusion for further analyses. Testicular tissue samples were examined for biochemical and histopathological parameters. Germ cell apoptosis was evaluated using apoptosis-activating factor 1 (Apaf-1). Inducible nitric oxide synthase (iNOS) activity was analyzed in the late-term reperfusion groups. Spermatogenic functions were assessed for each testis based on the Johnsen criteria.

Biochemical analyses

Serum TNF- α and IL-1 β were quantified using enzyme-linked immunosorbent assay (ELISA) kits (Biosource International, Nivelles, Belgium). Tissue samples were homogenized with ice-cold 150 mM KCl for the determination of malondialdehyde (MDA) and glutathione (GSH) levels. The MDA levels are expressed as nmol MDA/g of tissue.^[11] GSH was determined by a spectrophotometric method, and the results are expressed as μ mol GSH/g tissue.^[12] Myeloperoxidase (MPO) activity in tissues was measured by Hillegas method.^[13] For this purpose, tissue samples were homogenized in 50 mM potassium phosphate buffer with a pH of 6.0 and centrifuged at 41,400 g for 10 min. After several standardized procedures, MPO activity was calculated as U/g tissue.

Histopathological analyses

All of the tissue samples were evaluated by a competent uro-pathologist (AO) who was aware of the studies' objectives but blind to the randomized groups. Histological investigations were performed in order to determine the tissue damage. Germ cell apoptosis was evaluated using apoptosis-activating factor 1 (Apaf-1). Inducible nitric oxide synthase (iNOS) activity was analyzed in late-term reperfusion groups. Spermatogenic functions were evaluated in each testis according to the Johnsen criteria.^[14]

The testicular tissue samples were fixed in Bouin solution and embedded into paraffin blocks. Then, they were stained with hematoxylin & eosin, and all the tubules were inspected under a light microscope. These samples were used to assess the morphological status of the testicular tissues and graded from 1 to 10 according to the maturation degrees.

Immunohistochemical analyses were performed for assessing apoptosis and iNOS levels. Apaf-1 (Apoptosis protease activating factor-1, neomarkers, rabbit polyclonal, prediluted) was used for incubation over the night. Additionally, 30 minutes of incubation was performed with iNOS (Neomarkers, rabbit polyclonal, prediluted). The sections underwent a standard washing

process. The immunohistochemical staining results were evaluated according to a previously described system.^[15] Accordingly, for both Apaf-1 and iNOS, the intracytoplasmic staining density and the ratio of positive cells were determined. Expression scores were calculated by multiplying those two components.

Statistical analyses

All of the variables were analyzed using Mann-Whitney U, Dunn and Kruskal Wallis tests (SPSS 13.0, Inc., Chicago, IL, USA). The values are provided as the mean \pm standard deviation of the mean (SD). A p value of <0.05 was considered statistically significant. In multiple comparisons, a z value of $z > 1.96$ was considered statistically significant.

Results

At the assigned times following torsion and detorsion (T/D), all of the histopathological and molecular parameters were compared among the groups. Unilateral I/R caused a significant increase in serum TNF- α levels in the early-term group when compared to the sham groups ($p < 0.05$). Montelukast treatment significantly decreased these levels and achieved comparable results with the sham groups. However, IL-1ss levels were found to be comparable among all groups ($p > 0.05$).

The oxidative stress markers, including the malondialdehyde (MDA) level and myeloperoxidase (MPO) activity, detected in the tissue samples were found to be elevated in the I/R groups and accompanied by a significant decrease in the glutathione level compared to the sham groups ($p < 0.001$). The results remained constant for the early and late term reperfusion groups. Montelukast treatment reversed these parameters and brought them to the same levels as the sham groups ($p > 0.05$). Figure 2 shows the comparison of the oxidative stress markers between the 6 groups.

The immunohistochemical analyses of the ischemic testes in the late-term group indicated that I/R significantly increased the iNOS expression levels when compared to sham groups ($p < 0.05$). Moreover, the montelukast treatment decreased these levels and achieved comparable results to the sham groups ($p > 0.05$). Figure 3 demonstrates the immunohistochemical staining with iNOS of all of the groups. Accordingly, iNOS staining was significantly predominant in the I/R groups compared to the sham groups. Montelukast treatment significantly decreased the iNOS staining density and generality.

The other immunohistochemical analyses in the early-term group for germ cell apoptosis demonstrated that I/R significantly increased all of the apoptotic markers in the ischemic testes compared to the sham groups, and this effect was significantly decreased with the administration of montelukast

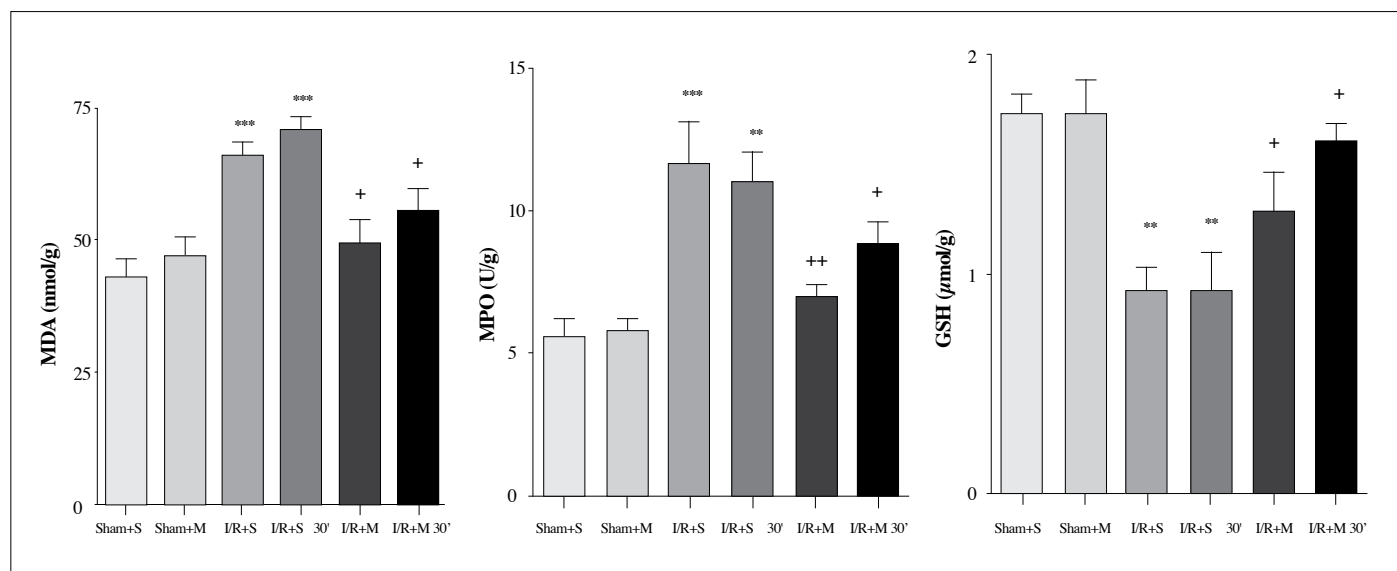


Figure 2. Comparison of the study groups for the different oxidative stress markers

MDA: malondialdehyde; MPO: myeloperoxidase; GSH: glutathione

*p<0.05, **p<0.01, ***p<0.001, comparison with the sham groups

+p<0.05, ++p<0.01, +++p<0.001, comparison of the treatment groups with the I/R groups

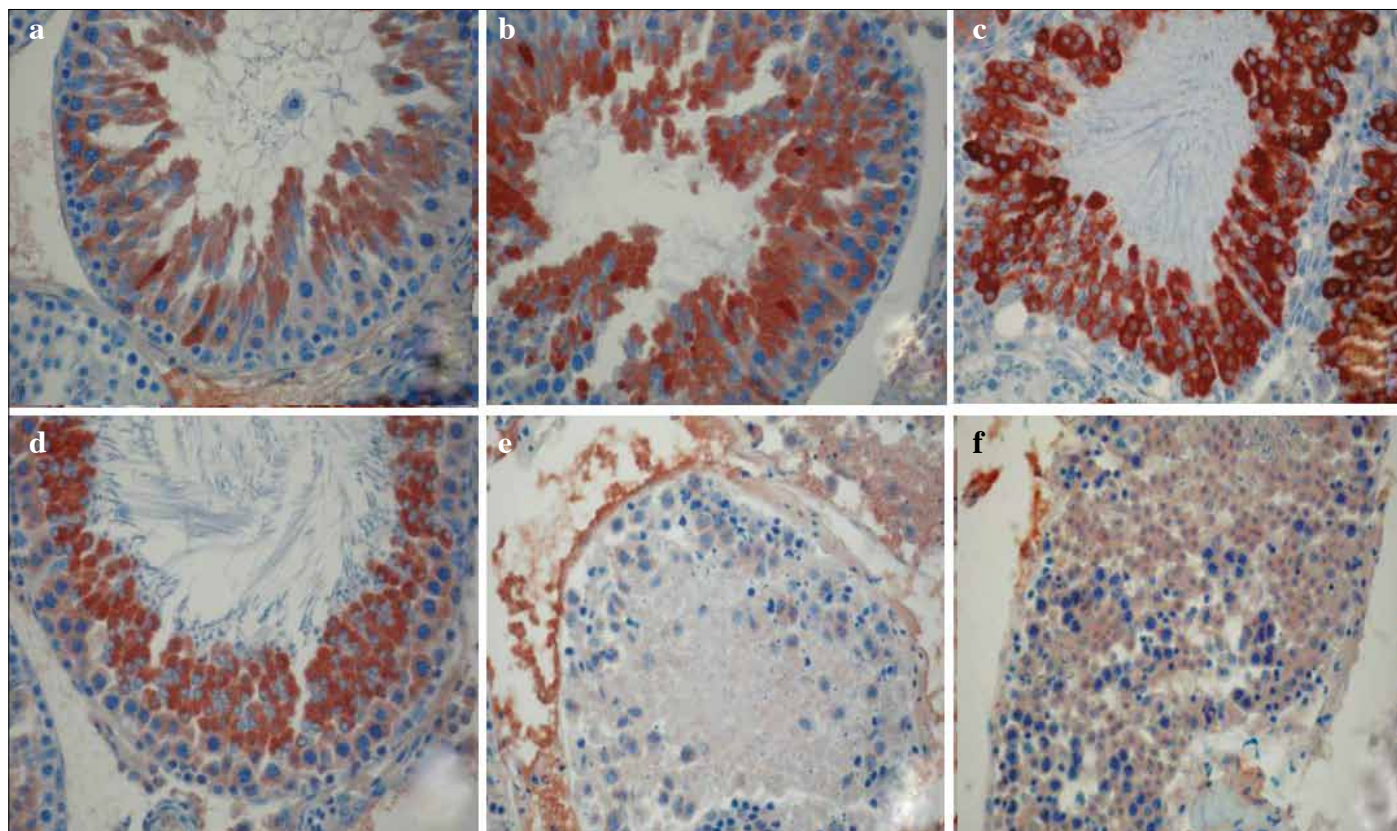


Figure 3. Immunohistochemical staining of the seminiferous tubules with iNOS. x40

a: Sham + SF; b: Sham + M; c: I/R + SF; d: I/R + SF 30'; e: I/R + M; f: I/R + M 30'

The bold stained cytoplasm of the cells represents the iNOS activity. The untreated I/R groups (c, d) have predominant staining compared to the sham groups. This indicates that the montelukast treatment significantly decreases the iNOS staining

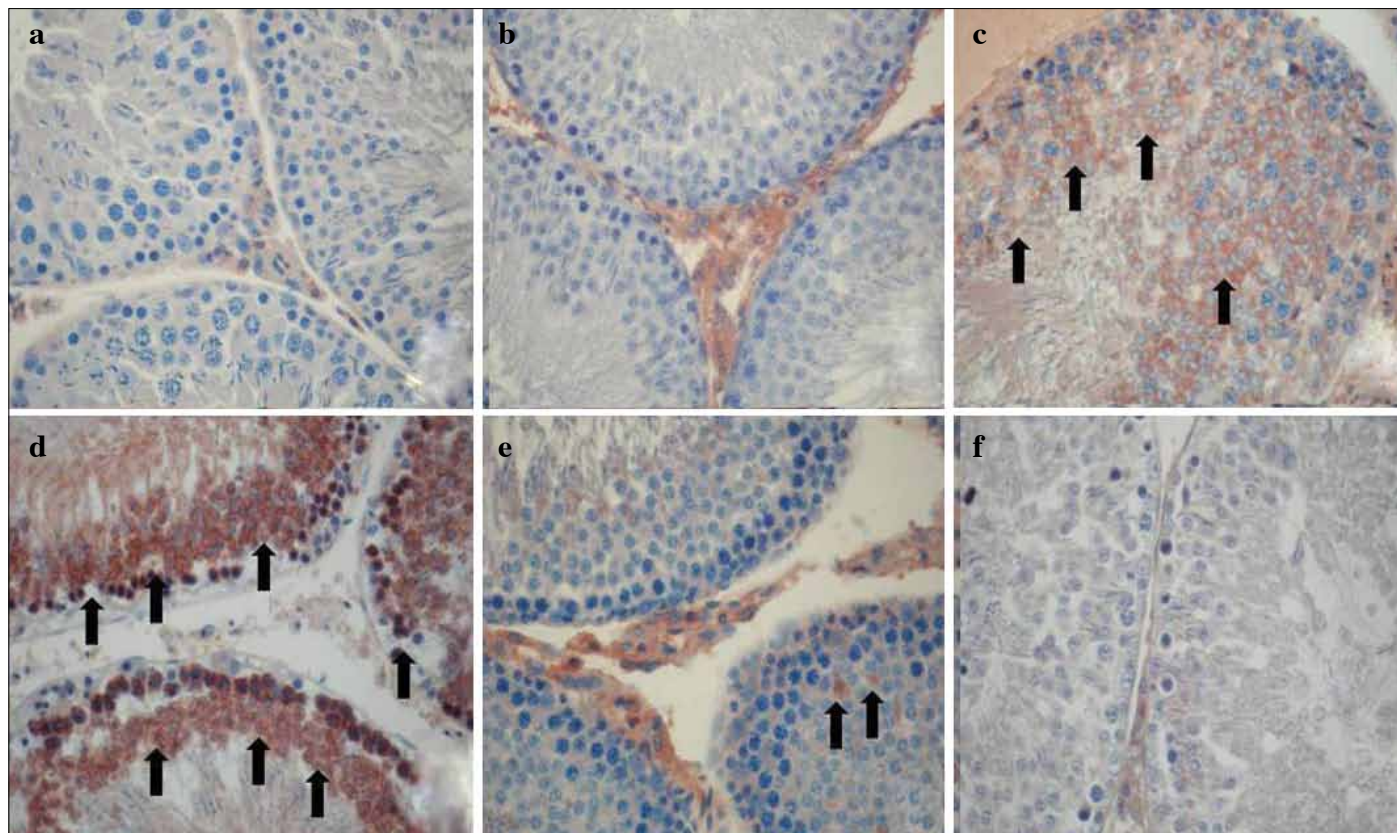


Figure 4. Immunohistochemical staining of seminiferous tubules with Apaf-1. x40

a: Sham + SF; b: Sham + M; c: I/R + SF; d: I/R + SF 30'; e: I/R + M; f: I/R + M 30'

The areas with arrows indicate the brown-stained cell cytoplasm stained with Apaf-1 and indicate apoptosis

($p < 0.05$). Figure 4 demonstrates the immunohistochemical staining of Apaf-1 of all groups. Accordingly, Apaf-1 staining is significantly predominant in I/R groups when compared to the sham groups. Montelukast treatment significantly decreases the Apaf-1 staining density and generality. Finally, similar results were achieved for the bilateral testes of all of the groups regarding spermatogenic indices, as determined by the Johnsen criteria ($p > 0.05$).

Discussion

Our results demonstrate that montelukast has protective effects on testicular tissue after I/R injury. In the study groups in which montelukast was not administered, the oxidative stress markers both in the blood and tissue were significantly worse. Additionally, an elevation of iNOS activity and germ cell apoptosis were also detected. Montelukast reversed all of these harmful effects and reduced the testicular damage related to I/R injury.

Testicular torsion is a surgical emergency affecting young men and adolescents. The incidence is reported as 1/158 in males under 24 years old.^[1,2] Immediate detorsion should be performed

in order to prevent testicular damage. However, even after a successful surgery, atrophy may occur, and this may lead to infertility. Therefore, it is important to develop treatment strategies that decrease testicular damage and prevent oxidative stress. There are several reported anti-oxidative treatment options, but the main concern is the balance between the risk and the benefits. These medications, including trimetazidine, erythropoietin, taurine and curcumin, have been shown to decrease the apoptotic index and free radicals within the testicular tissue after I/R.^[5-8] However, due to extensive side effects, none of them are currently in clinical use, and the trials are considered experimental.

Montelukast specifically inhibits the CystLT1 receptor and is a selective leukotriene D-4 antagonist. It is in clinical use as an anti-asthmatic drug due to its effects decreasing eosinophilic inflammation in the lungs. It has also been demonstrated that montelukast has inhibitory effects on neutrophil migration and has positive effects on the oxidative system. Therefore, in some organs, the effects of montelukast have been previously studied. In one study, the investigators demonstrated that montelukast increases the viability of skin flaps when compared to the control group.^[16] In another trial focusing on the liver, it was demonstrated that montelukast reversed the histopathological altera-

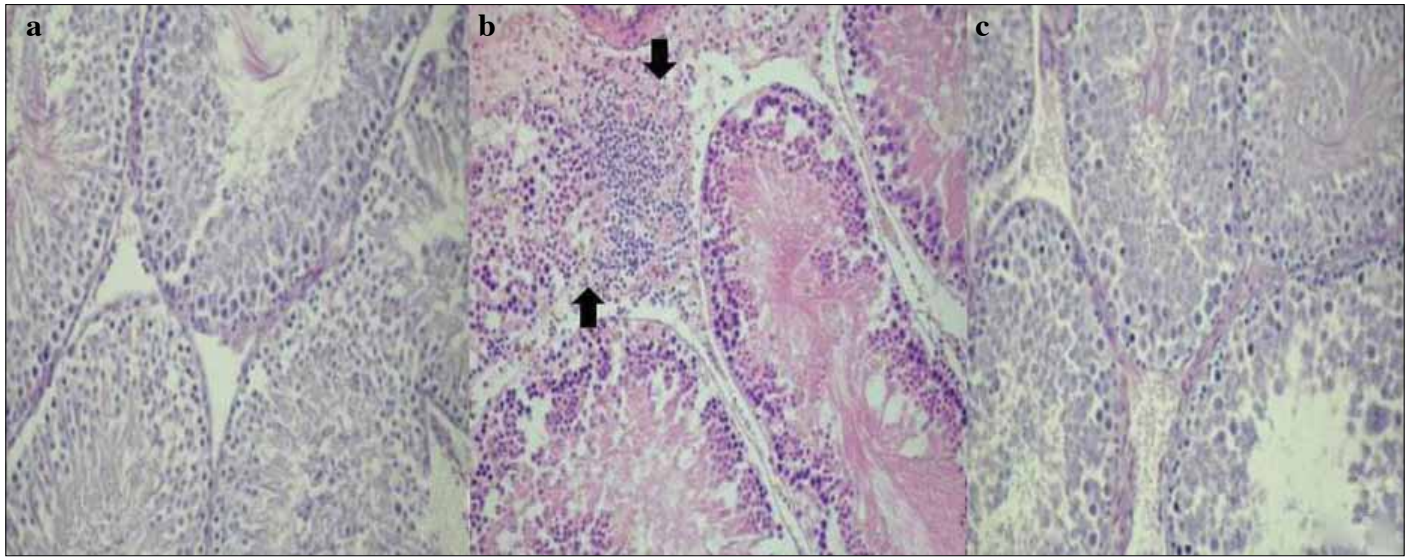


Figure 5. Hematoxylin & eosin staining of seminiferous tubules. x20

a: Sham + SF; b: I/R + SF; c: I/R + M

The areas with the arrows indicate the neutrophilic accumulation into the interstitial area

tions and protected from the tissue from damage due to I/R injury.^[17] The results were similar both in kidney and bladder tissues, and the protective effects of montelukast have been proven.^[9,10]

Montelukast has also been studied previously in testicular torsion models.^[18,19] However in both of these models, there were severe methodological errors, and the mechanism of montelukast had not yet been explored. Therefore, in our study, we aimed to demonstrate the effect of montelukast by assessing not only apoptosis but also several other parameters, including iNOS activity, neutrophil migration, spermatogenetic functions and oxidative stress markers, both in the blood and tissue samples.

NO is the end product of NOS, and it is physiologically found in low concentrations in tissues. In the case of I/R, its concentration dramatically increases, and after combining with oxygen, and peroxynitrite is formed. Finally, it causes DNA damage and apoptosis. Many studies have shown that testicular iNOS levels increase after I/R, which is one of the major causes of tissue damage.^[20,21] It has been previously demonstrated using Western blotting that the iNOS levels are significantly increased 24 hours after I/R.^[21] In that study, the investigators noted that the iNOS levels were not detectable before 24 hours. Therefore, we evaluated the iNOS levels in rats that were sacrificed 24 hours after the detorsion period. Finally, we demonstrated that I/R significantly increased the iNOS expression levels compared to the sham groups. In addition, the montelukast treatment decreased the iNOS levels and achieved comparable results to the sham groups. This evaluation is an important parameter in understanding the mechanism for the protective effect of montelukast in testicular torsion. Our study is the first to evaluate this parameter after montelukast administration.

Several reports have demonstrated that the exact mechanism for apoptosis in germ cells after torsion is extensive neutrophil migration and the subsequent elevation of ROS. In our study, the montelukast administration 30 minutes prior to detorsion and during detorsion significantly decreased the migration of neutrophils to the testis, as shown in Figure 5. We believe that this inhibition is the major cause for the decrease in apoptosis in germ cells.

Spermatogenesis is among the other parameters that are negatively affected after testicular torsion. There is no consensus on the period for the worsening of this parameter, and many studies have demonstrated various results depending on the Johnsen criteria. This period is subject to change, and the range is as wide as between 2 hours and 3 months.^[22]

In our study, we evaluated the spermatogenetic functions histopathologically using the Johnsen criteria. Spermatogenesis was evaluated in both testes in the groups sacrificed 24 hours after detorsion. However, the results did not demonstrate any significant difference among the groups, and the Johnsen scores were similar. After evaluating the literature, this is an expected finding that may be attributed to the timing of the sacrifice, which was a relatively short period after detorsion.

In this study, aimed to elucidate the possible protective effect of montelukast in unilateral testicular T/D, and the following results were found: testicular torsion/detorsion increased the inflammatory mediators in venous blood samples and resulted in significantly increased iNOS activity in the unilateral testis. Additionally, I/R caused an imbalance in oxidative mechanisms,

resulting in germ cell apoptosis in the ischemic testis. All of the parameters above can be potentially reversed with the administration of systemic montelukast. Montelukast exerts protective effects against testicular I/R injury via inhibiting neutrophil activity, decreasing the iNOS levels and attenuating apoptosis. Further investigations are needed to prove that montelukast is a useful therapeutic adjunct to surgical repair in cases of human testicular torsion.

Ethics Committee Approval: Ethics committee approval was received for this study from the ethics committee of Şişli Etfal Training and Research Hospital.

Peer-review: Externally peer-reviewed.

Author Contributions: Concept - M.S.S.; Design - M.S.S., M.K., H.T.; Supervision - C.M., G.Ş., M.K.; Funding - M.S.S., H.T.; Materials - H.T., G.Ş., Ş.T.; Data Collection and/or Processing - M.S.S., M.A., A.Ö.; Analysis and/or Interpretation - M.S.S., H.T., Ş.T., M.A., A.Ö.; Literature Review - M.S.S., M.K., G.Ş.; Writer - M.S.S., H.T.; Critical Review - C.M., G.Ş., A.Ö.; Other - M.A., Ş.T., A.Ö.

Conflict of Interest: No conflict of interest was declared by the authors.

Financial Disclosure: The authors declared that this study has received no financial support.

Etik Komite Onayı: Bu çalışma için etik komite onayı Şişli Etfal Eğitim ve Araştırma Hastanesi'nden alınmıştır.

Hakem değerlendirmesi: Dış bağımsız.

Yazar Katkıları: Fikir - M.S.S.; Tasarım - M.S.S., M.K., H.T.; Denetleme - C.M., G.Ş., M.K.; Kaynaklar - M.S.S., H.T.; Malzemeler - H.T., G.Ş., Ş.T.; Veri toplanması ve/veya işlemesi - M.S.S., M.A., A.Ö.; Analiz ve/veya yorum - M.S.S., H.T., Ş.T., M.A., A.Ö.; Literatür taraması - M.S.S., M.K., G.Ş.; Yazıyı yazan - M.S.S., H.T.; Eleştirel inceleme - C.M., G.Ş., A.Ö.; Diğer - M.A., Ş.T., A.Ö.

Çıkar Çatışması: Yazarlar çıkar çatışması bildirmemişlerdir.

Finansal Destek: Yazarlar bu çalışma için finansal destek almadıklarını beyan etmişlerdir.

References

1. Barada JH, Weingarten JL, Cromie WJ. Testicular salvage and age-related delay in the presentation of testicular torsion. *J Urol* 1989;142:746-8.
2. Cattolica EV, Karol JB, Rankin KN, Klein RS. High testicular salvage rate in torsion of the spermatic cord. *J Urol* 1982;128:66-8.
3. Mogilner JG, Lurie M, Coran AG, Nativ O, Shiloni E, Sukhotnik I. Effect of diclofenac on germ cell apoptosis following ischemia-reperfusion injury in a rat. *Pediatr Surg Int* 2006;22:99-105. [\[CrossRef\]](#)
4. Ozkan KU, Boran C, Kiliç M, Garipardıç M, Kurutaş EB. The effect of zinc aspartate pretreatment on ischemia-reperfusion injury and early changes of blood and tissue antioxidant enzyme activities after unilateral testicular torsion-detorsion. *J Ped Surg* 2004;39:91-5. [\[CrossRef\]](#)
5. Pekcetin C, Ergur BU, Kiray M, Bagriyanik A, Tugyan K, Erbil G, et al. The protective effects of trimetazidine on testicular ischemia and reperfusion injury in rats. *Pediatr Surg Int* 2007;23:1113-8. [\[CrossRef\]](#)
6. Ergur BU, Kiray M, Pekcetin C, Bagriyanik HA, Erbil G. Protective effect of erythropoietin pretreatment in testicular ischemia-reperfusion injury in rats. *J Pediatr Surg* 2008;43:722-8. [\[CrossRef\]](#)
7. Wei SM, Yan ZZ, Zhou J. Beneficial effect of taurine on testicular ischemia-reperfusion injury in rats. *Urology* 2007;70:1237-42. [\[CrossRef\]](#)
8. Wei SM, Yan ZZ, Zhou J. Curcumin attenuates ischemia-reperfusion injury in rat testis. *Fertil Steril* 2009;91:271-7. [\[CrossRef\]](#)
9. Sener G, Sehirli O, Velioglu-Ogünç A, Cetinel S, Gedik N, Caner M, et al. Montelukast protects against renal ischemia/reperfusion injury in rats. *Pharmacol Res* 2006;54:65-71. [\[CrossRef\]](#)
10. Sener G, Sehirli O, Toklu H, Ercan F, Alican I. Montelukast reduces ischaemia/reperfusion-induced bladder dysfunction and oxidant damage in the rat. *J Pharm Pharmacol* 2007;59:837-42. [\[CrossRef\]](#)
11. Beuge JA, Aust SD. Microsomal lipid peroxidation. *Methods Enzymol* 1978;52:302-11. [\[CrossRef\]](#)
12. Beutler E. Glutathione in red blood cell metabolism. *A Manual of Biochemical Methods*, Grune&Stratton, New York 1975:112-4.
13. Hillegas LM, Griswold DE, Brickson B, Albrightson-Winslow C. Assesment of myeloperoxidase activity in whole rat kidney. *J Pharmacol Methods* 1990;24:285-95. [\[CrossRef\]](#)
14. Johnsen SG. Testicular score biopsy count-a method for registration of spermatogenesis in human testes: normal values and results in 335 hypogonadal males. *Hormones* 1970;1:2-25. [\[CrossRef\]](#)
15. Leo C, Horn LC, Rauscher C, Hentschel B, Richter CE, Schütz A, et al. Lack of apoptotic activating factor-1 expression and resistance to hypoxia induced apoptosis in cervical cancer. *Clin Cancer Res* 2007;13:1149-53. [\[CrossRef\]](#)
16. Gideroglu K, Yilmaz F, Aksoy F, Bugdayci G, Sağlam I, Yılmaz F. Montelukast protects axial pattern rat skin flaps against ischemia/reperfusion injury. *J Surg Res* 2009;157:181-6. [\[CrossRef\]](#)
17. Daglar G, Karaca T, Yüksek YN, Gozalan U, Akbiyik F, Sokmensuer C, et al. Effect of montelukast and MK-886 on hepatic ischemia-reperfusion injury in rats. *J Surg Res* 2009;153:31-8. [\[CrossRef\]](#)
18. Ozturk H, Ozturk H, Gideroglu K, Terzi H, Bugdayci G. Montelukast protects against testes ischemia/reperfusion injury in rats. *Can Urol Assoc J* 2010;4:174-9. [\[CrossRef\]](#)
19. Isikdemir F, Kurcer Z, Dengiz GO, Sipahi EY, Banoglu ZN, Baba F, et al. Effects of montelukast and zileuton on testicular torsion/detorsion injury in rats. *Andrologia* 2012;doi: 0.1111/and.12042.
20. Gower JD, Healing G, Fuller BJ, Simpkin S, Green CJ. Protection against oxidative damage in cold-stored rabbit kidneys by desferrioxamine and indomethacin. *Cryobiology* 1989;26:309-17. [\[CrossRef\]](#)
21. Shiraishi K, Naito K, Yoshida K. Nitric oxide promotes germ cell necrosis in the delayed phase after experimental testicular torsion of rat. *Biol Reprod* 2001;65:514-21. [\[CrossRef\]](#)
22. Pentayala S, Lee J, Yalamanchili P, Vitkun S, Khan SA. Testicular torsion. A review. *J Low Urin Tract Dis* 2001;5:38-47. [\[CrossRef\]](#)