

Fibrous pseudotumors of the testis: The balance between sparing the testis and preoperative diagnostic difficulty

Testisin fibröz pseudotümörü; ameliyat öncesi tanı zorluğuna karşılık testis korunması arasındaki denge

Şeref Başal¹, Ercan Malkoç¹, Emin Aydur², İbrahim Yıldırım², Yusuf Kibar², Bülent Kurt³, Serdar Göktaş⁴

ABSTRACT

Objective: To determine a paradigm that will be helpful for urologists to manage fibrous pseudotumors, which are a very rare condition of the testis.

Material and methods: We retrospectively evaluated the patients with fibrous pseudotumors in our uro-pathological database from 1995 to 2013. Patients who had tumor markers and ultrasonography (USG) screening before surgery and a final pathology report of a fibrous pseudotumor were included in the study.

Results: In total, 838 patients with a testis mass were evaluated. Only 6 of these patients met the inclusion criteria. The mean age was 34 years (min: 20, max: 72). Serum tumor markers were in the normal range for all patients. The scrotal tumors were not clearly related to the testis parenchyma, and the radiologists could not definitively determine the nature of the masses (benign or malignant). A concomitant hydrocele was detected in 2 patients. After inguinal exploration, radical orchiectomy was performed in one patient with an ipsilateral atrophic testis, and biopsies were taken from the lesions for frozen section analysis in the other 5 patients. Pathologists reported benign tumors for all of these patients based on the frozen sections, and testicular sparing surgery was then performed in these 5 patients.

Conclusion: If scrotal tumors are detected by ultrasonography in patients with normal tumor markers, and the tumor cannot be clear distinguished from the testis, these patients might have a fibrous pseudotumor, and organ-sparing surgery can be performed on these patients.

Key words: Fibrous pseudotumor; testis; testicular sparing surgery.

ÖZET

Amaç: Çok nadir görülen testisin fibröz pseudotümörü ve bu tümöre yaklaşımın belirlenmesi.

Gereç ve yöntemler: 1995-2013 yılları arasında üropatoloji verilerimizden retrospektif olarak testisin fibröz pseudotümörü tanısını alan hastalar değerlendirmeye alındı. Tümör belirteçleri ve ameliyat öncesi ultrasonografi (USG) olan aynı zamanda final patolojisi fibröz pseudotümör olarak rapor edilen hastalar çalışmaya dahil edildi.

Bulgular: Toplam 838 testis kitlesi değerlendirildi. Bu hastalardan sadece 6 hasta dahil edilme kriterlerine sahipti. Hastaların yaş ortalaması 34 (minumum: 20, maksimum: 72) idi. Bütün hastaların tümör belirteçleri normaldi. Skrotal USG'de kitlenin testis parankimiyle ilişkisi net değildi ve kitlenin natürü hakkında kesin bir bulgu yoktu. 2 hastada eş zamanlı aynı tarafta hidrosel mevcuttu. İnguinal eksplorasyona müteakip atrofik testis olan hastaya radikal orşiektomi yapıldı. Diğer 5 hastadan ameliyat esnasında biyopsi alındı. Frozen patolojisinin benign gelmesi üzerine bütün hastalara testis koruyucu cerrahi uygulandı.

Sonuç: Tümör belirteçleri normal olup USG'de testisle ilişkisi net olarak değerlendirilemeyen scrotal kitlerde testisin fibröz pseudotümörü akla getirilmeli ve bu hastalarda organ koruyucu cerrahi düşünülmeli.

Anahtar kelimeler: Fibroz pseudotumor; testis; testis koruyucu cerrahi.

¹Department of Urology, Gülhane Military Medical Academy Haydarpaşa Training Hospital, İstanbul, Turkey

²Department of Urology, Gülhane Military Medical Academy, Ankara, Turkey

³Department of Pathology, Gülhane Military Medical Academy, Ankara, Turkey

⁴Department of Urology, Selçuk University Faculty of Medicine, Konya, Turkey

Submitted:
28.02.2014

Accepted:
26.05.2014

Correspondence:
Şeref Başal,
Department of Urology, Gülhane
Military Medical Academy
Haydarpaşa Training Hospital,
34668 İstanbul, Turkey
Phone: +90 505 486 39 60
E-mail: serefbasal@gmail.com

©Copyright 2014 by Turkish
Association of Urology

Available online at
www.turkishjournalofurology.com

Introduction

Intrascrotal lesions are common in the male population. While 95% of testicular lesions are malignant, most paratesticular lesions are benign. Usually paratesticular lesions are cystic in nature. Fibrous pseudotumors, the second

most common intrascrotal lesion after adenomatoid tumors, was first recognized in 1904 by Balloch.^[1] The term “fibrous pseudotumor” is generally accepted to include reactive benign lesions of the testicular tunics. They comprise only 6% of paratesticular lesions and can be observed at any age, while the incidence peaks

Table 1. Characteristics of patients

n	Age	Size of mass (cm)	Side	Concomitant pathology	Tumor markers (α -FP, β -HCG)	USG findings	Frozen section analysis (Malignancy +/-)	Final pathology	Tissue of origin
1	25	6	Right	Right atrophic testis	Normal	Paratesticular soft tissue hypoechoic and adjacent testicular tissue with atrophic testes	Not evaluated	FPT	Tunica albuginea
2	23	4.5	Left	Left hydrocele, left solitary testis	Normal	Echogenic soft tissue with borders cannot be distinguished from normal testes with increased scrotal liquid	-	FPT	Tunica albuginea
3	41	6	Left	-	Normal	Well-rounded, high blood-flow mass with a central appearance that mimics mediastinum testes at the proximal right testes	-	FPT	Tunica vaginalis
4	25	2.5	Right	-	Normal	Heterogenous, lobular hypoechoic mass that cannot be clearly distinguished from the testes	-	FPT	Tunica vaginalis
5	72	5	Right	Right hydrocele	Normal	Solid mass adjacent to the testis and epididymis. The mass is hypoechoic compared to the testis and demonstrates faint posterior shadowing	-	FPT	Tunica vaginalis
6	20	6	Left	-	Normal	At the superior aspect of the left testis, there is a thick soft tissue mass surrounding the testis	-	FPT	Tunica albuginea

FPT: fibrous pseudotumor of the testis; USG: ultrasonography

between the second and fourth decades of life.^[2] Because these tumors are benign, instead of radical orchiectomy, testis sparing surgery is important to preserve fertility in these patients.

A preoperative diagnosis of a fibrous pseudotumor is challenging. Distinguishing these masses from malignant tumors with clinical and radiological findings can be difficult. Thus, blind orchiectomy for testicular fibrous pseudotumors has always been reported in case reports not larger series. Thus, urologists must carefully evaluate this rare condition to prevent unnecessary testis removal.

We retrospectively evaluated our patients with fibrous pseudotumors in our urology department and aimed to determine a paradigm that will be helpful for urologists managing this rare condition.

Material and methods

We retrospectively evaluated our uropathological database over the last 18 years for fibrous pseudotumors of the testis among scrotal-testicular surgeries and their pathologic outcomes and clinical features. The study was conducted in accordance

with International Conference on Harmonization Good Clinical Practice guidelines and the Declaration of Helsinki. All subjects were provided written informed consent. The protocol was approved by the Ethics Committees at the Gülhane Military Medical Academy Haydarpaşa Training and Research Hospital (protocol no:1491-37-14/1539, date: 27.03.2014). Data, such as patient age, side of scrotal mass, concomitant pathology, ultrasonographic findings, surgical procedure, and macroscopic appearance of the mass, were extracted from patient files (Table 1).

Statistical analysis

The arithmetic mean and minimum and maximum values of age and tumor size were calculated using Statistical Package for the Social Sciences (SPSS Inc., Chicago, IL, USA) for Windows (version 15.0).

Results

In our urology department, the numbers of patients who underwent radical orchiectomy, simple orchiectomy and testis sparing surgery from 1995-2013 were 198, 628, and 12, respectively. The radical orchiectomy specimens were reported as primer testicular cancer in 144, granulomatous orchitis in

13, lymphoma metastasis in 9 and pseudotumor of the testis in one patient after histopathological examination. Of the 12 patients who underwent testis-sparing surgery, ectopic spleen was detected in 2 and a fibrous pseudotumor of the testis was detected in 5.

We found 6 patients with a fibrous pseudotumor of the testis. The mean age was 34 years (min: 23, max: 72). None of them had a causative factor before the diagnosis or a history of testicular infection. The nature of the masses could not be defined according to ultrasonographic features (Figure 1). Two patients had concomitant hydrocele, and one had an ipsilateral atrophic testis. The median mass size was 5 cm (min: 2.5, max: 6), and tumor markers for testicular cancer were in the normal ranges for all patients. Right radical orchiectomy was performed without frozen section analysis for one patient with an ipsilateral atrophic testis and a normal left testis. After obtaining informed consent, inguinal exploration was performed in 5 patients. After testis exploration, biopsies were taken from the masses for frozen section analysis. Pathologists reported benign tumors in all 5 patients. According to these histopathological results, testicular sparing surgery was performed for all 5 patients. The masses were excised completely (Figure 2) and sent for a final histopathological evaluation, and the surgical procedure was completed. The final pathology was a fibrous pseudotumor of the testis for all patients (Table 1 and Figure 3).

Discussion

Most benign intrascrotal lesions (adenomatoid tumor, fibrous pseudotumor, cystadenoma, spermatocele, hydrocele, varicocele and hernia, tunica albuginea cyst, testicular simple cyst, epidermoid cyst, tubular ectasia of the rete testis, intratesticular varicocele, and adrenal rest tumor and splenogonadal fusion) occur in paratesticular tissue and are cystic in nature. They are common in the male population. The fibrous pseudotumor was first reported in 1904 by Balloch and is the second most common intrascrotal lesion.^[1] Many names have been used for these lesions, including chronic proliferative periorchitis, inflammatory pseudotumor, nodular and diffuse fibrous proliferation, proliferative funiculitis, fibromatous periorchitis, fibroma, benign fibrous paratesticular tumor, fibrous mesothelioma, pseudofibromatous periorchitis, nonspecific paratesticular fibrosis, and reactive periorchitis.^[1-4] They are in benign nature and constitute 6% of paratesticular lesions.^[1-3] These lesions can affect the testis, testicular tunica, epididymis and spermatic cord. Benign fibrous pseudotumors can be observed at any age, while the incidence peaks between the second and fourth decades of life.^[2] Only 4 cases exist of patients younger than 18 years of age diagnosed with a fibrous pseudotumor after clinical evaluation.^[1] Four of our patients were in the second decade of life, one was in the fifth and one was in the eighth decade.

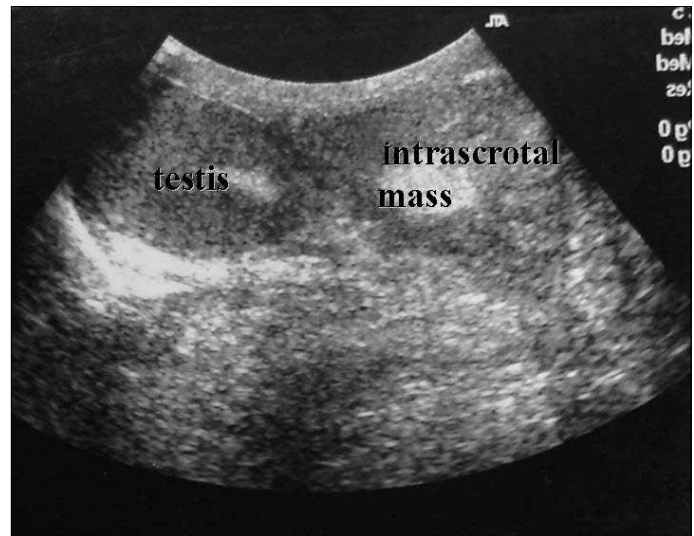


Figure 1. Ultrasonographic appearance of intrascrotal mass

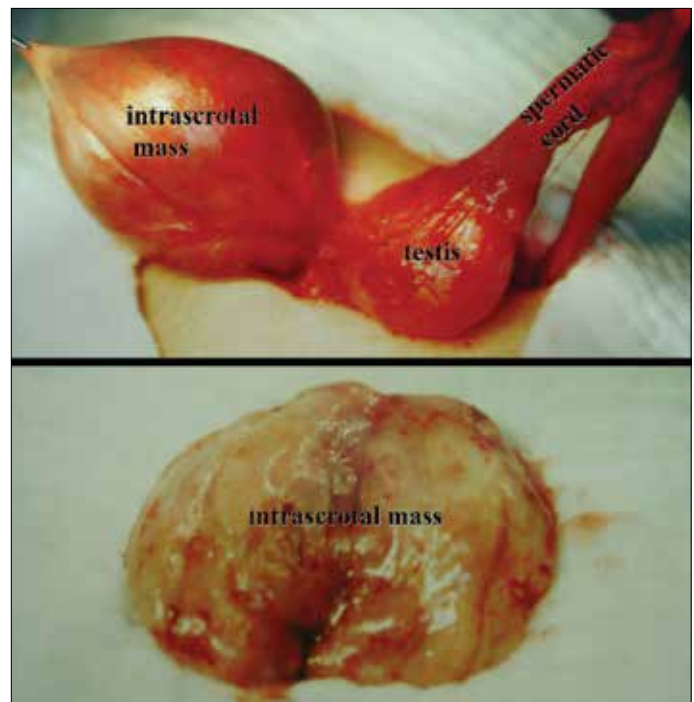


Figure 2. Macroscopic appearance of intrascrotal mass after scrotal exploration

Usually patients present with a small, circumscribed, firm, painless mass in the scrotum. The etiology is unknown. However, a reactive nature is suggested because some patients have history of trauma, surgery, infection or inflammatory hydrocele. *Schistosoma haematobium* infection has also been associated with fibrous pseudotumors. This infection was thought to contribute to this particular tumor's giant size and rapid growth, lending credit to the theory of the reactive nature of fibrous

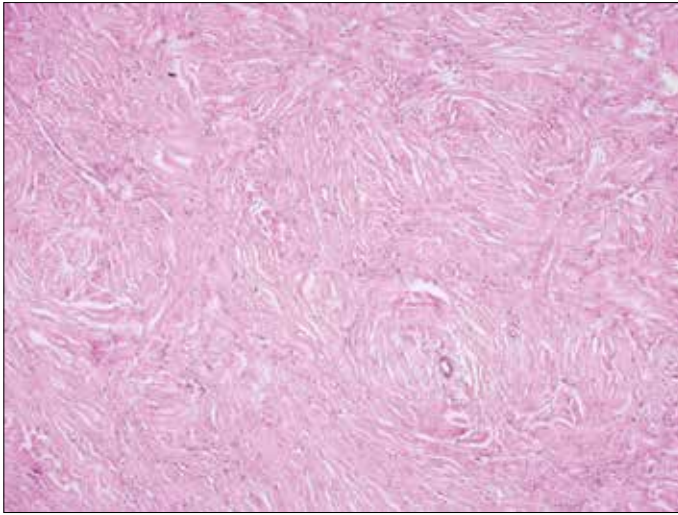


Figure 3. Well circumscribed nodule with lymphocytes

pseudotumors.^[4] However, for most cases, no etiological factor can be detected. Macroscopically, these nodules may be single or multiple and originate from the testicular tunics or epididymis and may involve the spermatic cord. The nodules are well circumscribed and firm with a white-tan, whorled cut surface and range in size from 4 to 8 cm. Although mostly involving the tunics, nodular adherence to the dartos muscle and scrotal skin can occur.^[1,5] Occasionally, the nodules originate from the tunica surface and give rise to floaters or scrotal pearls in the tunical space.^[6] Most reported cases have involved the tunica vaginalis; rarely, the tumor is associated with the tunica albuginea, epididymis, or spermatic cord.^[1,3,5] Epididymal involvement is apparent in less than 10% of cases of fibrous pseudotumors.^[7] The lesions are asymptomatic, but almost 50% of cases are associated with a hydrocele.^[8] These masses can be quite large and mimic neoplasms. Three of our patients (50%) had tunica albuginea involvement, and the other 3 had tunica vaginalis involvement. In one patient with an atrophic testis and in 2 with a hydrocele, there was additional pathology in the testis. All six patients only had one mass with an average size of 5 cm.

Distinguishing the masses from malignant etiologies is difficult. Secondary to the inflammatory process, ultrasonography may show microcalcifications and which paratesticular structures are involved and fibrous, and the presentation is often complicated by cystic pathologic findings compatible with hydrocele.^[9] Due to the amount of collagen, calcification or fibroblasts, fibrous pseudotumors can be hyperechoic or hypoechoic on ultrasound without another specific appearance.^[10-13] Slight focal thickening of the tunica albuginea without abnormalities in the testicle may be detected by ultrasound. These lesions can be distinguished from most other testicular lesions according to ultrasound (US) findings, anatomic location, and negative tumor markers, but using these findings, determining the nature of these lesions

(benign or malignant) radiologically is difficult. Magnetic resonance imaging may prove to be more definitive for making a preoperative diagnosis, but experience is currently limited. A fibrous pseudotumor has intermediate to low signal intensity on T1-weighted images (similar to that of the testis) and low signal intensity on T2-weighted images. In those patients in whom gadolinium contrast was given, there was little to no enhancement.^[14-17] The ultrasonographic findings in our series are more consistent with the findings reported in the literature, and in this respect, the findings can be characterized as 'classical'. However, this result was not surprising because this appearance is not specific. Thus, imaging could not aid in the decision making schema for fibrous pseudotumors of the testis and testis sparing surgery.

Orchiectomy has been generally reported for testicular fibrous pseudotumors in case reports and not larger series. Jones and coworkers reported 9 patients with a fibrous pseudotumor of the testis. They perform radical orchiectomy in 8 patients and mass excision in 1 patient. They reported that the outcome was benign in the seven cases in whom follow-up information is available.^[18] Lately, testicular sparing surgery has become common for small testis tumors. There are studies using intraoperative ultrasonography (USG)^[19] or microscopy^[20] to evaluate the mass during surgery. Frozen section analyses were performed for all patients and compared with the final pathology.^[19-21] In these studies, the final pathology and frozen section pathology were found to be consistent with each other. In studies by Shilo and coworkers and Gentile and associates, 11 of 16 patients (69%) and 12 of 14 patients (86.7%), respectively, the final pathologies were reported as benign. Furthermore, in a study by De Stefani and coworkers, seminoma was found in only 2 of 23 patients. Radical orchiectomy was performed for patients whose biopsies were malignant, and no case of relapse was observed in follow up. Different from these studies, the testis tumors in our study were not small. In addition, these scrotal tumors were not clearly associated with the testis parenchyma. In our study, inguinal exploration was performed, and intraoperative frozen analyses were obtained to rule out malignancy in all patients except one patient who underwent orchiectomy without frozen tissue analysis because he had an atrophic testis. When the lesion was reported as benign by the pathologist, a testis sparing procedure was performed. The final pathology was reported as a fibrous pseudotumor for all cases. Using intraoperative frozen tissue analysis, we saved the testis in 5 of 6 patients.

This retrospective study has a few apparent shortcomings. Intraoperative USG was not used, and excisional biopsy was performed on the masses based on palpation. Intraoperative USG for control purposes after excision might be useful for these patients.

In conclusion, if a scrotal tumor is detected by USG in patients with normal tumor markers, and its relation with the testis cannot

be determined, these patients might have a fibrous pseudotumor. Blunt radical orchiectomy would be invasive in these patients. In suspected cases, using frozen section analysis during surgery, an organ-sparing strategy can be pursued in these patients.

Ethics Committee Approval: Ethics committee approval was received for this study from the ethics committee of Gülhane Military Medical Academy Haydarpaşa Training and Research Hospital (27.03.2014, Protocol no: 1491-37-14/1539).

Informed Consent: Written informed consent was obtained from patients who participated in this study.

Peer-review: Externally peer-reviewed.

Author Contributions: Concept - Ş.B.; Design - Ş.B., E.A.; Supervision - İ.Y., S.G.; Funding - E.M.; Materials - S.B., Y.K., İ.Y., B.K.; Data Collection and/or Processing - E.M.; Analysis and/or Interpretation - E.M., Ş.B., Y.K., E.A.; Literature Review - E.M.; Writer - Ş.B., E.M.; Critical Review - İ.Y., E.A., S.G., Y.K.; Other - B.K.

Conflict of Interest: No conflict of interest was declared by the authors.

Financial Disclosure: The authors declared that this study has received no financial support.

Etik Komite Onayı: Bu çalışma için etik komite onayı Gülhane Askeri Tıp Akademisi Haydarpaşa Eğitim ve Araştırma Hastanesi'nden (27.03.2014, Protokol no: 1491-37-14/1539) alınmıştır.

Hasta Onamı: Yazılı hasta onamı bu çalışmaya katılan hastalardan alınmıştır.

Hakem değerlendirmesi: Dış bağımsız.

Yazar Katkıları: Fikir - Ş.B.; Tasarım - Ş.B., E.A.; Denetleme - İ.Y., S.G.; Kaynaklar - E.M.; Malzemeler - S.B., Y.K., İ.Y., B.K.; Veri toplanması ve/veya işlemesi - E.M.; Analiz ve/veya yorum - E.M., Ş.B., Y.K., E.A.; Literatür taraması - E.M.; Yazıyı yazan - Ş.B., E.M.; Eleştirel inceleme - İ.Y., E.A., S.G., Y.K.; Diğer - B.K.

Çıkar Çatışması: Yazarlar çıkar çatışması bildirmemişlerdir.

Finansal Destek: Yazarlar bu çalışma için finansal destek almamışlardır.

References

- Seethala RR, Tirkes AT, Weinstein S, Tomaszewski JE, Malkowicz SB, Genega EM. Diffuse fibrous pseudotumor of the testicular tunics associated with an inflamed hydrocele. *Arch Pathol Lab Med* 2003;127:742-4.
- Williams G, Banerjee R. Paratesticular tumours. *Br J Urol* 1969;41:332-9. [CrossRef]
- Polsky EG, Ray C, Dubilier LD. Diffuse fibrous pseudotumor of the tunica vaginalis testis, epididymis and spermatic cord. *J Urol* 2004;171:1625-6. [CrossRef]
- Elem B, Patil PS, Lambert TK. Giant fibrous pseudotumor of the testicular tunics in association with Schistosoma haematobium infection. *J Urol* 1989;141:376-7.
- Rubenstein RA, Dogra VS, Seftel AD, Resnick MI. Benign intra-scrotal lesions. *J Urol* 2004;171:1765-72. [CrossRef]
- Mikuz G, Damjanov I. Inflammation of the testis, epididymis, peritesticular membranes, and scrotum. *Pathol Annu* 1982;17:101-28.
- Tobias-machado M, Corrêa Lopes Neto A, Heloisa Simardi L, Borrelli M, Wroclawski ER. Fibrous pseudotumor of tunica vaginalis and epididymis. *Urology* 2000;56:670-2. [CrossRef]
- Orland MS, Schlecker BA, Wein AJ. Benign diseases the testicle and para testicular tissues. *AUA Update Series* 1986;5:1-7.
- Parker PM, Pugliese JM, Allen RC Jr. Benign fibrous pseudotumor of tunica vaginalis testis. *Urology* 2006;68:427.e17-9.
- Sönmez K, Türkyilmaz Z, Boyacıoğlu M, Edali MN, Ozen O, Başaklar AC, et al. Diffuse fibrous proliferation of tunica vaginalis associated with testicular infarction: a case report. *J Pediatr Surg* 2001;36:1057-8. [CrossRef]
- al-Otaibi L, Whitman GJ, Chew FS. Fibrous pseudotumor of the epididymis. *AJR Am J Roentgenol* 1997;168:1586. [CrossRef]
- Mostofi FK, Price EB. Tumors of the male genital system, in Firminger HI (Ed): *Atlas of Tumor Pathology*. Washington DC, Armed Forces Institute of Pathology 1973.pp.151-3.
- Orosz Z, Besznyák I. Diffuse inflammatory pseudotumor of the testis, the epididymis and the spermatic cord. *Pathol Oncol Res* 1995;1:75-9. [CrossRef]
- Mehta AL, Dogra VS. Intratesticular varicocele. *J Clin Ultrasound* 1998;26:49-51. [CrossRef]
- Kutlu R, Alkan A, Soylu A, Sigirci A, Dusak A. Intratesticular arteriovenous malformation: color Doppler sonographic findings. *J Ultrasound Med* 2003;22:295-8.
- Jackson Jr. The histogenesis of the adenomatoid tumor of the genital tract. *Cancer* 1958;11:337-50. [CrossRef]
- Williams SB, Han M, Jones R, Andrawis R. Adenomatoid tumor of the testes. *Urology* 2004;63:779-81. [CrossRef]
- Jones MA, Young RH, Scully RE. Benign fibromatous tumors of the testis and paratesticular region: a report of 9 cases with a proposed classification of fibromatous tumors and tumor-like lesions. *Am J Surg Pathol* 1997;21:296-305. [CrossRef]
- Gentile G, Brunocilla E, Franceschelli A, Schiavina R, Pultrone C, Borghesi M, et al. Can testis-sparing surgery for small testicular masses be considered a valid alternative to radical orchiectomy? A prospective single-center study. *Clin Genitourin Cancer* 2013;11:522-6. [CrossRef]
- De Stefani S, Isgrò G, Varca V, Pecchi A, Bianchi G, Carmignani G, et al. Microsurgical testis-sparing surgery in small testicular masses: seven years retrospective management and results. *Urology* 2012;79:858-62. [CrossRef]
- Shilo Y, Zisman A, Raz O, Lang E, Strauss S, Sandbank J, et al. Testicular sparing surgery for small masses. *Urol Oncol* 2012;30:188-91. [CrossRef]