



Testis sparing surgery in a case of small unilateral testicular cancer *Tek taraflı küçük bir testis tümöründe testis koruyucu cerrahi*

Hakkı Uzun¹, Sabri Oğullar², İbrahim Şehitoğlu³, Gökem Akça¹, Orhan Ünal Zorba¹

ABSTRACT

A 22-year-old male presented at our institution with an incidentally ultrasound-detected testicular tumor. Magnetic resonance imaging showed a contrast-enhanced right intratesticular mass over 1 cm in size. The patient underwent testis sparing surgery. Pathologic examination revealed seminoma. A follow-up nine months later showed no residual tumor, a normal contour of the testis and no evidence of atrophy. Testis sparing surgery is an option for patients with small unilateral testicular tumors even in the presence of a healthy contralateral testis.

Key words: Partial orchidectomy; testicular cancer; testis sparing surgery.

ÖZET

Ultrasonografik olarak insidental testiküler tümör saptanmış 22 yaşında bir erkek hasta kliniğimize başvurdu. Manyetik rezonans görüntülemeye sağ testiste 1 cm'in üzerinde kontrast tutan intratestiküler bir kitle saptandı. Hastaya testis koruyucu cerrahi uygulandı. Patolojik inceleme sonucu seminoma olarak raporlandı. Dokuz aylık takip sonucunda rezidüel tümör saptanmadı, testis konturu normal olarak görüntülendi ve testiküler atrofi bulgularına rastlanmadı. Testis koruyucu cerrahi diğer testisi sağlıklı olan tek taraflı, küçük testiküler tümörlerde bir seçenek olabilir.

Anahtar sözcükler: Parsiyel orşiektomi; testis koruyucu cerrahi; testis tümörü.

¹Department of Urology,
Faculty of Medicine, Recep
Tayyip Erdoğan University,
Rize, Turkey

²Department of Radiology,
Rize Education and Research
Hospital, Rize, Turkey

³Department of Pathology,
Faculty of Medicine, Recep
Tayyip Erdoğan University,
Rize, Turkey

Submitted:
11.02.2013

Accepted:
15.05.2013

Correspondence:
Hakkı Uzun
Department of Urology, Faculty
of Medicine, Recep Tayyip Er-
doğan University, 53100 Rize,
Turkey
Phone: +90 464 214 04 92-1787
E-mail: hakuzun@yahoo.com

©Copyright 2013 by Turkish
Association of Urology

Available online at
www.turkishjournalofurology.com

Introduction

Testis sparing surgery, or partial orchidectomy, is now preferred for the treatment of bilateral testicular masses or in patients with a solitary testis.^[1] However, there is no absolute indication, and there are no data for resectable small unilateral testicular cancers with a healthy contralateral testis. Testis sparing surgery has several advantages including reducing the need for androgen substitution, preserving fertility and lessening psychological stress.^[2] Local adjuvant radiotherapy has been reported to ensure good oncologic control, but there is a high risk for reduced androgen production.^[1,2] We present a case of a 14 mm nonpalpable asymptomatic intratesticular tumor.

Case report

A 22-year-old male with a suspicious varicocele underwent Doppler scrotal ultrasound,

and a round solid mass was incidentally detected in his right testis (Figure 1a). Axial T1 weighted magnetic resonance imaging revealed a contrast-enhanced testicular tumor (Figure 1b). The patient was managed with testis sparing surgery. An inguinal surgical approach was used, and the incision point was determined with the aid of intraoperative ultrasound by placing the probe on the tunica albuginea. The tunica albuginea was horizontally incised, and the tumor was extirpated from the adjacent parenchyma (Figure 2a, b). No magnification was used. During the excision, the tumor was easily dissected from the adjacent parenchyma, and no significant bleeding was observed. The testicular tissue architecture was easily maintained. Frozen section analysis of the postresection tumor bed and adjacent parenchyma was negative with negative tumor margins. Additionally, intraoperative ultrasound was repeated to search for any remaining tumor (Figure 3). Postoperative pathology revealed pure seminoma. The patient was

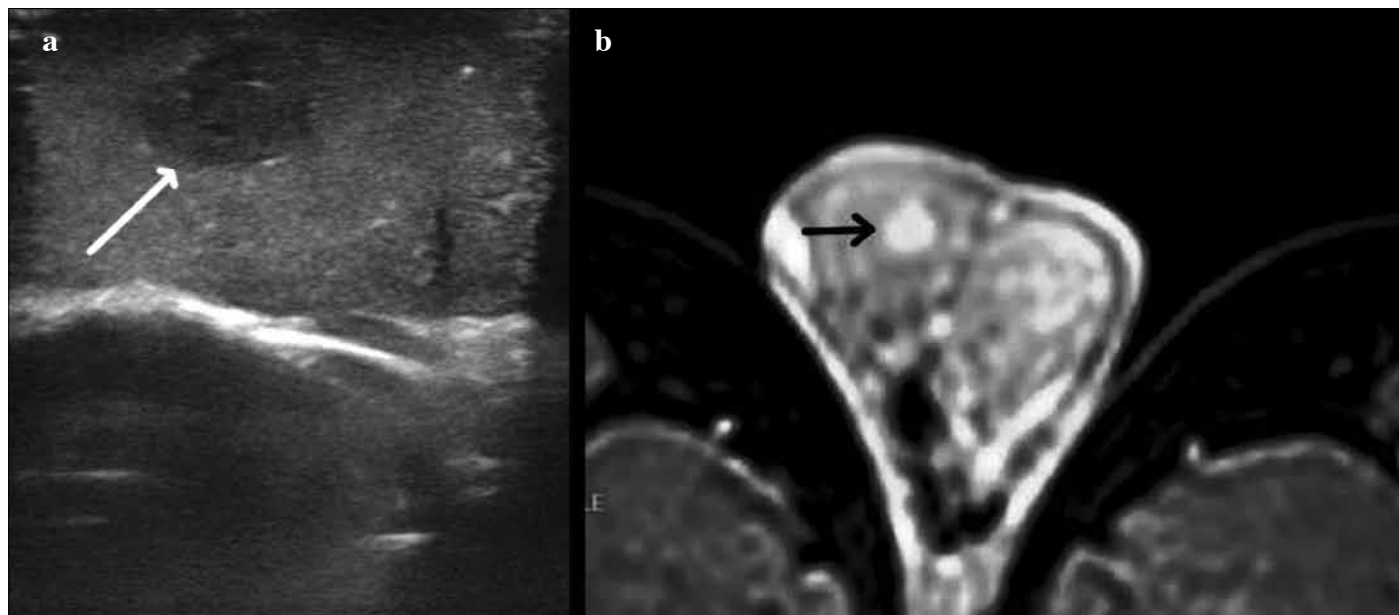


Figure 1. a. Preoperative ultrasound reveals a round, solid intratesticular mass. b) Axial T1 magnetic resonance imaging illustrates a contrast-enhanced hyperdense nodular area

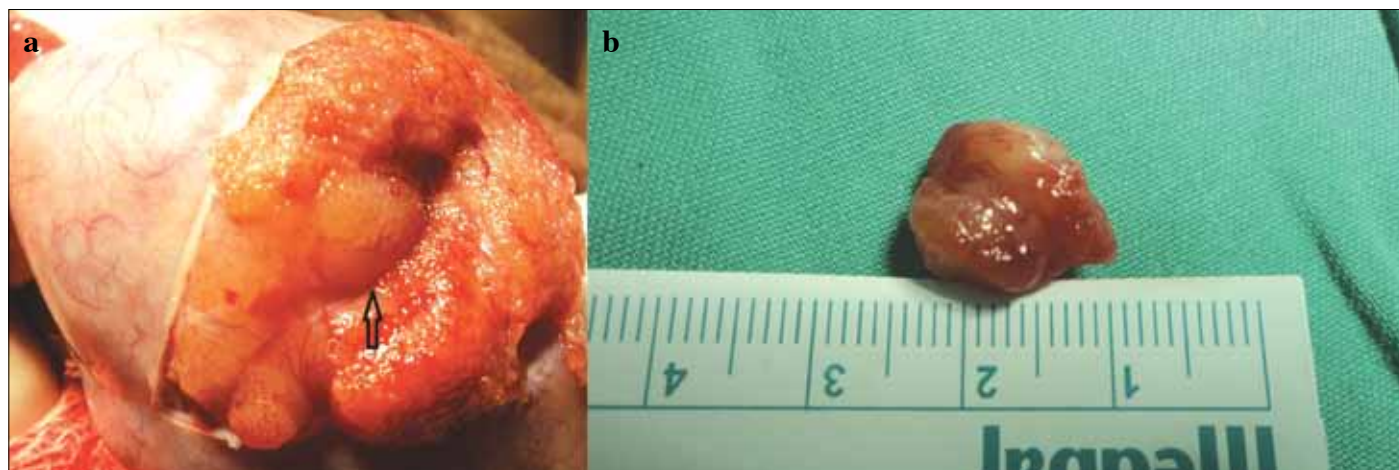


Figure 2. a. Intraoperative appearance of a well-demarcated testicular tumor. b) Gross appearance of the well-encapsulated 14 mm resected tumor

followed every three months with scrotal ultrasound. The nine-month follow-up revealed no residual tumor, a normal testicular contour and no evidence of atrophy. The patient provided written consent to use the information for the case report.

Discussion

Testicular sparing surgery is relatively indicated for testicular cancer within a solitary testis or bilateral testicular tumors. However, there is no recommendation for unilateral testicular cancers. Our case indicates that this procedure is also an option

for unilateral testicular cancers with a healthy contralateral testis.

Radical orchidectomy is known as the gold standard of malignant testicular cancer or tumors of unknown origin. The surgical approach in testis sparing surgery does not differ from that of radical orchidectomy. However, the inguinal surgical approach for testis sparing surgery has not been compared with a scrotal approach. It has been reported that 10% of testicular masses in radical orchidectomy specimens are benign.^[3,4] In addition, the survival of patients with testicular cancers has improved over the last two decades. The high rate of complete cure of testicular

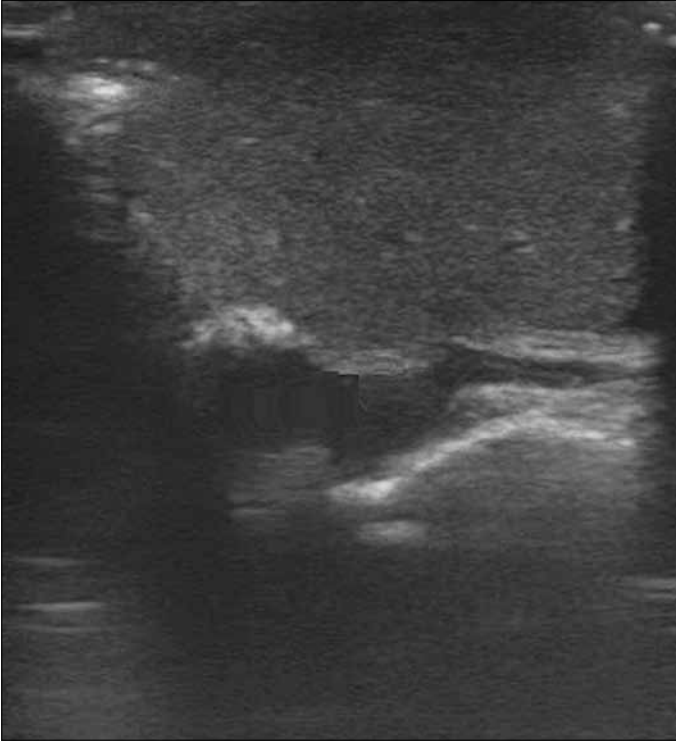


Figure 3. Intraoperative ultrasound imaging shows no visible residual tumor

cancer has resulted in a long life expectancy for these patients as healthy individuals. The surgical approach to testicular cancers is increasingly considered as having a potentially significant long-term effect on quality of life and endocrine and exocrine function of the testis. Thus, radical orchidectomy for cancer in a solitary testis or both testes greatly impacts quality of life, with the long-term significant adverse effect of hypogonadism. These patients also require life-long androgen substitution. However, in cases of malignancy of a small enucleable testicular tumor and a normal contralateral testis, testis sparing surgery could be considered as an alternative to radical orchidectomy. It could be assumed that radical orchidectomy in patients with a normal contralateral testis might also cause hypogonadism, particularly in the later stages of life, and reduce fertility. In one study, 11% of patients who underwent only radical orchidectomy without radiotherapy or chemotherapy had a subnormal level of testosterone. Additionally, in this group, 85% of patients were found to be fertile.^[5] Testis sparing surgery may decrease the number of patients that exhibit hypogonadism or infertility problems. Furthermore, psychosocial problems may become a major long-term complication of cancer treatment in a young age group.^[6] It is well known that testicular cancers are treated with a very high success rate, even for metastatic disease; we therefore believe that an organ-preserving strategy can be a reliable treatment option for resectable small unilateral testicular cancers.

Long-term follow-up of patients treated with testicular sparing surgery has a very high success rate. The German Testicular Cancer Study Group published their data from a large patient cohort with a mean follow-up of 8 years and a 99% disease-free survival rate in patients with bilateral testicular cancer or cancer in a solitary testis.^[7] Additionally, Carmignani et al.^[8] reported that 80% of non-palpable lesions are benign, and smaller testicular lesions (2 cm) are more likely to be benign.^[9]

We believe that the organ-preserving strategy should be considered and discussed with patients with unilateral testicular cancer and a healthy contralateral testis. Prospective larger studies with longer follow-up are needed to further demonstrate the utility of testis sparing surgery to treat small unilateral testicular tumors.

Conflict of Interest

No conflict of interest was declared by the authors.

Peer-review: Externally peer-reviewed.

Informed Consent: Written informed consent was obtained from patients who participated in this case.

Author Contributions

Concept - H.U., S.O.; Design - H.U., G.A.; Supervision - H.U.; Funding - H.U., İ.Ş.; Materials - H.U., S.O., İ.Ş.; Data Collection and/or Processing - H.U., S.O., İ.Ş., G.A.; Analysis and/or Interpretation - H.U.; Literature Review - H.U., O.Ü.Z.; Writer - H.U.; Critical Review - H.U., O.Ü.Z.

Çıkar Çatışması

Yazarlar herhangi bir çıkar çatışması bildirmemişlerdir.

Hakem değerlendirmesi: Dış bağımsız.

Hasta Onamı: Yazılı hasta onamı bu olguya katılan hastalardan alınmıştır.

Yazar Katkıları

Fikir - H.U., S.O.; Tasarım - H.U., G.A.; Denetleme - H.U.; Kaynaklar - H.U., İ.Ş.; Malzemeler - H.U., S.O., İ.Ş.; Veri toplanması ve/veya işlemesi - H.U., S.O., İ.Ş., G.A.; Analiz ve/veya yorum - H.U.; Literatür taraması - H.U., O.Ü.Z.; Yazıyı yazan - H.U.; Eleştirel inceleme - H.U., O.Ü.Z.

References

1. Giannarini G, Dieckmann KP, Albers P, Heidenreich A, Pizzocaro G. Organ-sparing surgery for adult testicular tumours: a systematic review of the literature. *Eur Urol* 2010;57:780-90. [\[CrossRef\]](#)
2. Zuniga A, Lawrentschuk N, Jewett MA. Organ-sparing approaches for testicular masses. *Nat Rev Urol* 2010;7:454-64. [\[CrossRef\]](#)
3. Passman C, Urban D, Klemm K, Lockhart M, Kenny P, Kolettis P. Testicular lesions other than germ cell tumours: feasibility of testis-sparing surgery. *BJU Int* 2009;103:488-91. [\[CrossRef\]](#)

4. Heidenreich A, Moul JW, Srivastava S, Engelmann UH. Synchronous bilateral testicular tumour:non-seminomatous germ cell tumours and contralateral benign tumours. *Scand Urol Nephrol* 1997;31:389-92. [\[CrossRef\]](#)
5. Huddart RA, Norman A, Moynihan C, Horwich A, Parker C, Nicholis E, et al. Fertility, gonadal and sexual function in survivors of testicular cancer. *Br J Cancer*, 2005;93:200-7. [\[CrossRef\]](#)
6. Heidenreich A and Hoffmann R. Quality of life issues in the treatment of testicular cancer. *World J Urol* 1999;17:230-8. [\[CrossRef\]](#)
7. Heidenreich A, Wei Bach L, Hörtl W, Albers P, Kliesch S, Köhrmann KU. Organ sparing surgery for malignant germ cell tumour of the testis. *J Urol* 2001;166:2161-5. [\[CrossRef\]](#)
8. Carmignani L, Gadda F, Gazzano G, Nerva F, Mancini M, Ferruti M, et al. High incidence of benign testicular neoplasm diagnosed by ultrasound. *J Urol* 2003;170:1783-6. [\[CrossRef\]](#)
9. Connolly SS, D'Arcy FT, Bredin HC, Callaghan J, Corcoran MO. Value of frozen section analysis with suspected testicular malignancy. *Urology* 2006;67:162-5. [\[CrossRef\]](#)