



Report of a boy with polyorchidism and a review of current knowledge regarding this unusual anomaly

Poliorşidi bulunan bir çocuğun sunumu ve bu nadir anomali ile ilgili güncel bilgiler

Hasan Salih Sağlam¹, Fikret Fatih Önoğlu², Egemen Avcı³, Akif Ergüven⁴

ABSTRACT

Polyorchidism is an extremely rare testicular malformation in children, and its etiology is unknown. There is an increased risk for testicular malignancy in these patients and a common association with other abnormalities, such as cryptorchidism, inguinal hernia, testicular torsion, hydrocele, and varicocele. There are insufficient data in the literature on the ideal management of polyorchidism. We report a 14-year-old boy with polyorchidism and review the current literature regarding this anomaly. Physical examination revealed a discrete, painless, left intrascrotal lump. α FP, β -hCG and LDH were normal. Scrotal ultrasound showed a well-circumscribed tissue in the left hemiscrotum measuring 2.5x2.0x1.3 cm and having the same echogenicity as the normal testes. Color Doppler study and magnetic resonance imaging also confirmed the tissue as a third testis with its own epididymis draining to a common vas. The testis was left in situ, and the patient was managed conservatively. Polyorchidism should be considered in the differential diagnosis of all scrotal masses. The etiology of polyorchidism is thought to be accidental division of the genital ridge before 8 weeks of gestation. The cases are divided into two categories according to anatomical properties, such as having drainage to an epididymis and vas deferens. The majority of cases are mainly encountered during evaluation for the other symptoms associated. Recent evidence supports that these cases may be followed conservatively when clinical findings and imaging techniques detect no complications or suspicion for malignancy, torsion, hernia, or cryptorchidism.

Key words: Management; polyorchidism; watchful waiting.

ÖZET

Poliorşidi çocuklarda son derece görülen nadir bir anomali olup etiyolojisi aydınlatılmış değildir. Bu hastalarda yüksek testis malignansı riski olup kriptorşidi, inguinal herni, testis torsiyonu, hidrosel ve varikozel gibi diğer sorunlarla birlikteliği yüksektir. İdeal tedavinin ne olduğuna dair yeterli literatür verisi mevcut değildir. Burada 14 yaşında bir poliorşidi vakası sunarak bu anomali hakkındaki güncel literatür bilgilerini gözden geçirdik. Fizik muayenede sol skrotumda testisten ayrı, ağrısız bir kitle görüldü. α FP, β -hCG ve LDH seviyeleri normaldi. Ultrasonda sol skrotumda iyi sınırlı, normal testisle aynı ekojeniteye sahip 2.5x2.0x1.3 cm boyutlarında bir doku saptandı. Renkli Doppler ve magnetik rezonans ile incelemede bu dokunun kendi epididimisi ve ana vas deferense bir drenajı olan üçüncü bir testis olduğu doğrulandı. Testis yerinde bırakıldı ve hasta konservatif olarak tedavi edildi. Poliorşidi tüm skrotal kitlelerin ayırıcı tanısında düşünülmelidir. Etiyolojisinde gebeliğin 8. haftasından önce genital kabartının hatalı olarak bölündüğü düşünülmektedir. Vakalar anatomik olarak epididim ve vaz deferens bulunmasına göre iki gruba ayrılmaktadır. Vakaların çoğu esas olarak birlikteki semptomların değerlendirilmesi esnasında fark edilir. Son kanıtlar klinik bulgu ve görüntüleme yöntemlerince tespit edilen her hangi bir komplikasyon, malignanite şüphesi, torsiyon, herni veya kriptorşidi olmadıkça vakaların takip edilebileceğini desteklemektedir.

Anahtar sözcükler: Gözlem; poliorşidi; tedavi.

Introduction

Polyorchidism is an extremely rare congenital anomaly of the urogenital system and is defined as the presence of more than two testes.^[1] Approximately 190 cases have been

reported since 1885.^[2,3] Furthermore, testicular malignancies are reported in 4% to 6% of these cases, and polyorchidism is most commonly encountered during exploration for other abnormalities, such as inguinal hernia, cryptorchidism, and testicular torsion, which requires

¹Department of Urology, Faculty of Medicine, Sakarya University, Sakarya, Turkey

²Clinic of Urology, Ümraniye Training and Research Hospital, Istanbul, Turkey

³Clinic of Urology, Memorial Ataşehir Hospital, Istanbul, Turkey

⁴Clinic of Radiology, Sakarya Training and Research Hospital, Sakarya, Turkey

Submitted:
03.02.2012

Accepted:
20.03.2012

Correspondence:
Hasan Salih Sağlam
Kemalpaşa Mah., Sağlık Sok.,
Seyirtepe Sitesi No: 3, Serdivan
54100 Sakarya, Turkey
Phone: +90 264 346 03 05
E-mail: hasanss@hotmail.com

©Copyright 2013 by Turkish Association of Urology

Available online at
www.turkishjournalofurology.com

pediatric urologists to become familiar with the diagnosis and management of this uncommon entity.^[1] We report a 14-year-old boy with polyorchidism and discuss our management in the light of current literature data, after obtaining a written consent from his parents.

Case report

A 14-year-old boy was admitted to the urology department with the complaint of a scrotal mass that was observed two months previously. There was no history of trauma, hernia, or undescended testes. On physical examination, two palpable, ovoid, mobile, non-tender masses with testicular sensation were detected in the left hemiscrotum. The two lumps were asymmetric in size, with the medial one being smaller, and their texture was similar to his normal right testis. Each lump had an attached soft tissue structure with the impression of epididymal shape and structure. Only one vas deferens was palpated on that side. Laboratory tests, including serum alpha-fetoprotein (aFP) and beta-human chorionic gonadotropin (HCG) levels, were within normal limits. Scrotal ultrasonography (US) showed a well-circumscribed accessory tissue in the left hemiscrotum measuring 2.5x2.0x1.3 cm and having the same echogenicity as the normal testes (Figure 1). The patient had no additional abnormal findings, such as hernia, hydrocele, or lymphadenopathy. Color Doppler study and magnetic resonance imaging (MRI) also confirmed the tissue as a third testis with its own epididymis draining to a common vas. Due to the age of the patient, a spermogram was not obtained. The testis was left in situ, and the patient was managed conservatively with US surveillance.

Discussion

Polyorchidism is an uncommon congenital defect that should be considered in the differential diagnosis of all scrotal masses. It may be associated with many other urological entities, including malignancy; therefore, it is important to be familiar with its potential diagnostic and therapeutic strategies. The etiology of polyorchidism is thought to be accidental division of the genital ridge before 8 weeks of gestation. The anomalous appropriation of cells, duplication or transverse vs. longitudinal division of the urogenital ridge, incomplete degeneration of a part of the mesonephros and development of peritoneal bands have been suggested, but none can explain all types of polyorchidism.^[2] Polyorchidism classification also shows considerable variation between reports.^[2-9] Leung grouped these cases according to anatomical variations based on their possible embryological basis and whether they had a shared or distinct epididymis or vas.^[7] Similarly, Singer et al.^[8] divided these cases according to anatomic and functional properties, such as having drainage to an epididymis and vas deferens,

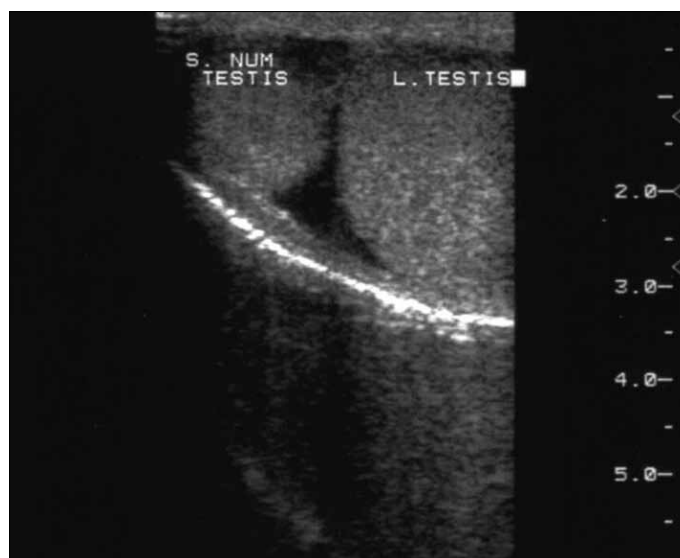


Figure 1. Ultrasonogram showing the supernumerary testicle having the same echogenicity as the normal testes located in the left hemiscrotum

which is suggestive of reproductive function. However, gross examination alone does not guarantee reproductive function because only half of the cases in the literature had age-related testicular tissue and spermatogenesis, whereas a quarter had no spermatogenesis.^[2] Nevertheless, management of the accessory tissue at least partially relies on the presence of an outflow drainage path.^[2,9]

Although previous reports suggested that most patients with polyorchidism presented with painless testicular or groin masses, recent analyses revealed that cases were mainly encountered during evaluation for other symptoms, such as acute scrotal pain or infertility.^[2,4-6] Our case presented with a painless scrotal lump, whereas most cases in the literature were diagnosed during exploration for inguinal hernia (24%), undescended testis (22%), and testicular torsion (15%).^[2] Only 7% presented with pain as the solitary symptom. As in the present case, left triorchidism was the most frequent presentation (65%), and the majority of supernumerary testes were found in the scrotal region (66%), followed by inguinal (23%) and abdominal (9%) locations.^[2,4,5] Thus, polyorchidism has no unique clinical presentation and should be considered in the differential diagnosis of any scrotal or inguinal mass or pain.

The management of polyorchidism has been the subject of controversy. With recent improvements in imaging studies, an increasing number of cases are diagnosed via US or MRI. Some of these cases have been left in situ and followed conservatively, as in the present case. However, even advanced high-resolution modalities may not always differ-

entiate between supernumerary testes and other intrascrotal lesions.^[2,10] Because testicular malignancy has been reported in as much as 6% of cases with polyorchidism and approximately 90% of these were detected in cryptorchid testes, all suspicious intrascrotal masses should be screened with serum markers and radiological techniques regardless of physical examination findings. Although there are no clear guidelines to determine which cases can be followed conservatively, recent data support watchful waiting in the absence of concomitant abnormalities and if testicular malignancy can be ruled out safely.^[2,4-6] In contrast, surgical exploration has the advantage of fixing the testis to prevent torsion and making biopsy easier if indicated.^[3,4,9,11] Further management depends on several factors, such as the position of the supernumerary testis [ie, orthotopic (scrotal) vs. ectopic (inguinal or abdominal)], the reproductive potential (whether it is attached to a draining epididymis and vas), its size and volume (normal or atrophic), the age of the patient (young or adult), and psychological aspects that are related to follow-up (ie, anxiety of the patient).^[5] Because most reported cases are detected during surgery for other urogenital symptoms, the question arises of whether the supernumerary testis should be left in situ (with orchiopexy if needed), biopsied for histological examination or removed. Recent studies suggest the removal of ectopic testes due to an increased risk of malignancy. Additionally, all undrained testes and drained testes complicated by symptoms requiring surgery or suspicious for malignancy should be biopsied through intraoperative frozen section (followed by orchiectomy or orchiopexy), and watchful waiting is recommended for scrotal testes without suspicion of malignancy or the need for surgery due to concomitant pathologies.^[2,5]

In conclusion, polyorchidism is a rare congenital anomaly that is unfamiliar to most urologists. To date, its management has generally involved surgery and removal. However, recent evidence supports that these cases may be followed conservatively when clinical findings and imaging techniques detect no complications or suspicion for malignancy, torsion, hernia, or cryptorchidism.

Conflict of Interest / Çıkar Çatışması

No conflict of interest was declared by the authors.

Yazarlar herhangi bir çıkar çatışması bildirmemişlerdir.

Peer-review: Externally peer-reviewed.

Hakem değerlendirmesi: Dış bağımsız.

Author Contributions / Yazar Katkıları

Concept / Fikir - H.S.S.; Design / Tasarım - F.F.O.; Supervision / Denetleme - F.F.O.; Analysis and/or Interpretation / Analiz ve/veya yorum - H.S.S., F.F.O.; Literature Review / Literatür taraması - E.A., A.E.; Writer / Yazıyı yazan - H.S.S.; Critical Review / Eleştirel İnceleme - F.F.O., A.E.

References

1. Sheah K, Teh HS, Peh OH. Supernumerary testicle in a case of polyorchidism. *Ann Acad Med Singapore* 2004;33:368-70.
2. Bergholz R, Wenke K. Polyorchidism: A meta-analysis. *J Urol* 2009;182:2422-7. [\[CrossRef\]](#)
3. Francesco A, Antonio NP, Salvatore A, Daniela V, Biagio Z, Giuseppe R. Immunohistochemistry: Additional armamentarium in the management of polyorchidism. *Pediatr Int* 2008;50:586-8. [\[CrossRef\]](#)
4. Hassan A, El-Mogy S, Mostafa T. Triorchidism: a case report and review of similar conditions. *Andrologia* 2008;40:265-9. [\[CrossRef\]](#)
5. Khedis M, Nohra J, Dierickx L, Walschaerts M, Soulié M, Thonneau PF, et al. Polyorchidism: presentation of 2 cases, review of the literature and a new management strategy. *Urol Int* 2008;80:98-101. [\[CrossRef\]](#)
6. Spranger R, Gunst M, Kuhn M. Polyorchidism: a strange anomaly with unsuspected properties. *J Urol* 2002;168:198. [\[CrossRef\]](#)
7. Leung AK, Wong AL, Kao CP. Duplication of the testis with contralateral anorchism. *South Med J* 2003;96:809-10. [\[CrossRef\]](#)
8. Singer BR, Donaldson JG, Jackson DS. Polyorchidism: functional classification and management strategy. *Urology* 1992;39:384-8. [\[CrossRef\]](#)
9. Bergholz R, Koch B, Spieker T, Lohse K. Polyorchidism: a case report and classification. *J Pediatr Surg* 2007;42:1933-5. [\[CrossRef\]](#)
10. Akbar SA, Sayyed TA, Jafri SZ, Hasteh F, Neill JS. Multimodality imaging of paratesticular neoplasms and their rare mimics. *Radiographics* 2003;23:1461-76. [\[CrossRef\]](#)
11. Bergholz R and Wenke K. Polyorchidism: A Meta-Analysis. *J Urol* 2009;182:2422-7. [\[CrossRef\]](#)