

Urinary bladder carcinosarcoma: a complete pathological response after neoadjuvant chemotherapy

Mesane karsinosarkomu: Neoadjuvan kemoterapi sonrası tam patolojik yanıt

Fadl Mohammed Tazi¹, Youness Ahallal¹, Amal Benlemlih², Abdelhak Khallouk¹, Mohammed Jamal Elfassi¹, Moulay Hassan Farih¹

ABSTRACT

Carcinosarcoma of the urinary bladder is a rare neoplasm that is composed of malignant epithelial and mesenchymal components. Fewer than 80 cases have been reported worldwide, usually as case reports or a small series. A series of 221 cases using the Surveillance, Epidemiology and End Results (SEER) Program database has been reported recently. We present one case of carcinosarcoma that was managed by neoadjuvant chemotherapy and that achieved a complete pathological response. A 57-year-old male patient presented with a 2-month history of hematuria. Ultrasonography revealed a 4 cm mass in the bladder dome. A transurethral resection of the bladder tumor (TURBT) revealed a carcinosarcoma. The patient underwent subsequent neoadjuvant chemotherapy and radiotherapy. The pathology specimen examination revealed no residual tumor. The patient had no evidence of recurrence after 20 months. This patient is the second reported case of carcinosarcoma of the urinary bladder that achieved a complete pathological response after neoadjuvant chemotherapy.

Key words: Bladder; carcinosarcoma; complete response; neoadjuvant chemotherapy; neoplasm.

ÖZET

Mesane karsinosarkomu malign epitelyal ve mezenkimal bileşenlerden oluşan ender bir neoplazmdir. Dünyada, genellikle olgu raporları ve küçük seriler şeklinde, 80'den az olgu bildirilmiştir. Yakın zamanda, Surveyans, Epidemiyoloji ve Son Bulgular (Surveillance, Epidemiology and End Results, SEER) Programı veritabanı kullanılarak 221 olgulu bir seri yayınlanmıştır. Biz neoadjuvan kemoterapi ile tedavi edilmiş ve tam bir patolojik yanıt sağlanmış bir karsinosarkom olgusunu sunmaktayız. 57 yaşında erkek hasta 2 aylık bir hematüri öyküsü ile başvurdu. Ultrasonografi mesane kubbesinde 4 cm'lik bir kitleyi ortaya çıkardı. Mesane tümörünün transüretal rezeksiyonu (TURBT) bir karsinosarkomu ortaya koydu. Hasta daha sonra neoadjuvan kemoterapi ve radyoterapi aldı. Örneklerin patolojik incelemesi rezidüel tümör olmadığını ortaya koydu. Hastada 20 ay sonra bir rekürrens belirtisi yoktu. Bu hasta, neoadjuvan kemoterapiden sonra tam bir patolojik yanıt sağlanan yayınlanmış ikinci mesane karsinosarkomu olgusudur.

Anahtar sözcükler: Mesane; neoplazm; karsinosarkom; neoadjuvan kemoterapi; tam yanıt.

Introduction

Carcinosarcomas are rare malignant neoplasms that contain malignant mesenchymal and epithelial elements.^[1] These tumors are more common in elderly men, in whom they are aggressive with an early progression.^[2] Immunohistochemistry is mandatory for diagnosis, and ideal treatment includes radical surgery and chemoradiotherapy.^[3]

This paper examined the clinical, therapeutic and histological features of this rare tumor

following an observation of carcinosarcoma in the urinary bladder.

Case history

A 57-year-old Moroccan male presented with a 2-month history of gross hematuria. The patient had no history of calculous disease or flank pain. He had smoked 40 cigarettes a day for the past 35 years. There was no history of contact with aniline dyes or other chemicals. Physical and paraclinical examinations were normal. Ultrasonography revealed a 4 cm heterogeneous mass in the bladder dome

¹Department of Urology, Hassan 2 Teaching Hospital, Fes, Morocco

²Department of Pathology, Hassan 2 Teaching Hospital, Fes, Morocco

Submitted: 07.09.2010

Accepted: 24.02.2011

Correspondence: Youness Ahallal
Department of Urology, Hassan 2 Teaching Hospital, Service d 30000 Fes, Morocco
Phone: +212661580158
E-mail: ahallalyouness@gmail.com

©Copyright 2012 by Turkish Association of Urology

Available online at www.turkishjournalofurology.com

(Figure 1). Cystoscopy revealed a 50×40×10 mm smooth polyp with papillary area on the bladder dome. Therefore, transurethral resection of the bladder was performed. An examination of the resection specimen revealed a mixed malignant tumor with epithelial (squamous cell carcinoma) and mesenchymal (rhabdomyosarcoma) elements, which is consistent with carcinosarcoma (Figure 2). Immunostaining was performed. Areas of squamous cell carcinoma stained positive for keratin and epithelial membrane antigen. The sarcomatous component stained positive for vimentin, desmin, and myoglobin. These results confirmed the carcinosarcoma diagnosis. Computed tomography was performed one month later and revealed a contrast-enhanced thickness of the bladder dome (Figure 3). The patient underwent neoadjuvant chemoradiotherapy. Radiation therapy (XRT) of 40 Gy was administered with carboplatin (100 mg/m³

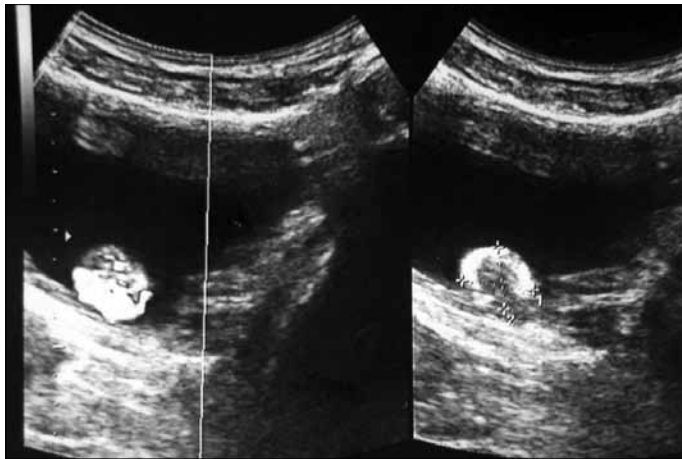

Figure 1. Ultrasonography revealing a 4 cm size heterogeneous mass in the bladder dome.

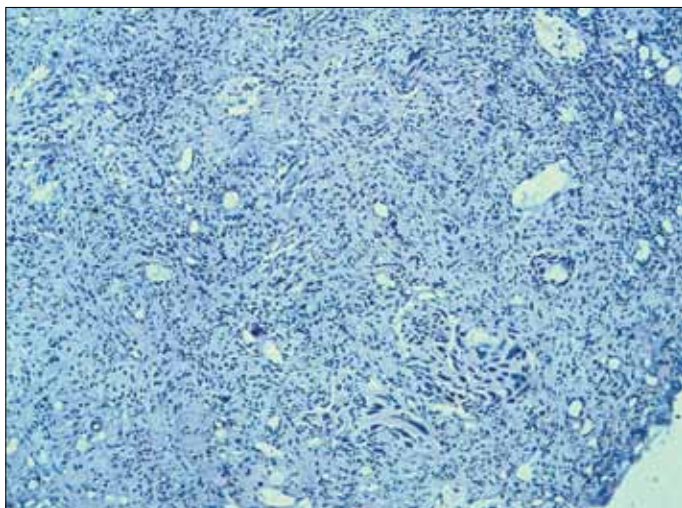


Figure 2. Mixed malignant tumor with epithelial (squamous cell carcinoma) and mesenchymal (rhabdomyosarcoma) elements consistent with carcinosarcoma.

on the first day of XRT). Gemcitabine was administered on days 1, 8 and 15 at 600 mg/m². Total cystectomy and extended pelvic lymph node dissection were performed. The final histological examination revealed no residual tumors and confirmed the pT0N0 diagnosis. The postoperative course was uneventful, and the patient was disease-free at a 20-month follow-up.

Discussion

Carcinosarcoma of the bladder is extremely rare and represents only 0.11% of all primary bladder tumors.^[2] Carcinosarcoma is a highly aggressive neoplasm with a malignant epithelial (e.g., transitional, squamous, glandular, or undifferentiated type) and sarcomatous component (e.g., rhabdomyosarcoma, osteosarcoma, or chondrosarcoma).^[4-6] The histogenesis of carcinosarcoma is controversial. This type of tumor can occur in patients with a history of radiotherapy or chemotherapy.^[7,8] Meyer (1920) classified carcinosarcomas into three histogenetic groups: 1) collision tumors in which carcinoma and sarcoma arise simultaneously in proximity and subsequently invade each other, 2) combination tumors in which both tumors derive from pluripotent cells, and 3) composition tumors in which the components arise from the same tissue.^[9] Willis restricted the term carcinosarcoma by excluding collision tumors.^[10]

The histological features of bladder carcinosarcoma vary. Tumors are generally large and polypoidal or nodular with surface ulceration, necrosis and deep invasion of the bladder wall.^[9] Diagnosing carcinosarcoma is often difficult, but the immunohistochemistry of these tumors is particularly interesting.^[11] The epithelial component in our case included squamous cell carcinoma, which was keratin and epithelial membrane

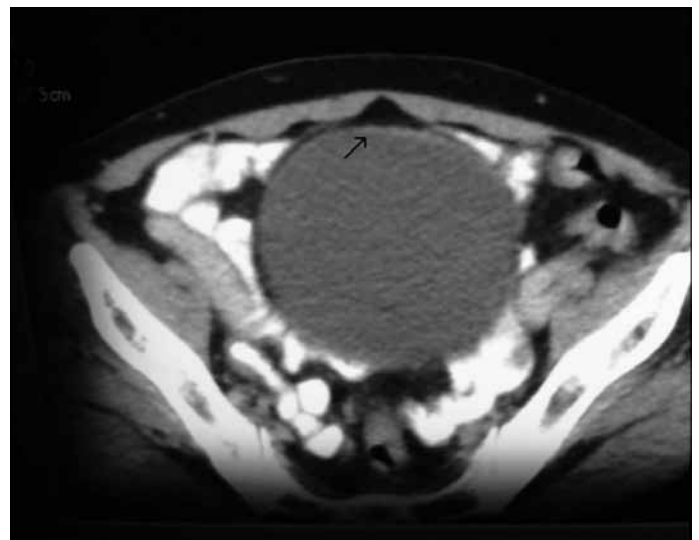


Figure 3. Computed tomography revealing a contrast-enhanced thickness of the of the bladder dome.

antigen positive, and the sarcomatous component, which stained positive for vimentin, desmin, and myoglobin.

Carcinosarcoma generally occurs in male patients aged 60 to 80 years with a median age of 75 years.^[2] The clinical presentation of carcinosarcoma is similar to transitional cell carcinoma of the bladder, and the most common presenting symptom is gross hematuria. The predominant location of carcinosarcomas is the bladder lateral wall, followed by the dome and the trigon.^[2] The tumors may be polypoid or sessile, and they may arise anywhere in the bladder. The location, size, shape, and multiplicity do not aid in the differentiation of carcinosarcomas from transitional cell carcinomas. Tekes et al.^[11] described the magnetic resonance (MR) imaging features of three carcinosarcoma patients and demonstrated that the carcinosarcomas, unlike transitional cell carcinomas, did not exhibit early strong arterial enhancement. The signal intensity of carcinosarcomas may also be heterogeneous on T2-weighted imaging.^[11]

The optimal treatment of carcinosarcomas is not certain. However, radical cystectomy is the treatment of choice for patients with carcinosarcoma of the urinary bladder, although many of these patients develop local recurrence after surgery. The majority of the patients in the SEER study received either TURB only (54.9%), cystectomy (35.7%) or surgery combined with radiation therapy (15.8%).^[2] Hoshi et al.^[3] presented a patient with bladder carcinosarcoma who achieved a complete response after neoadjuvant radiochemotherapy. Therefore, we applied this protocol to our patient and obtained the same result; our patient was disease-free 20 months after the surgery. Therefore, gemcitabine and carboplatin concomitant with irradiation is an efficient treatment modality for bladder carcinosarcoma patients. We used carboplatin instead of cisplatin because our patient exhibited impaired renal function. Carcinosarcomas are more highly aggressive tumors with higher recurrence rates and poorer prognosis compared to transitional cell carcinomas. The median cancer-specific survival in the SEER study was 14 months, and the 1-, 5-, and 10-year cancer-specific survival rates were 53.9%, 28.4% and 25.8%, respectively. Only tumor stage was a significant prognostic factor for disease-specific survival in a previous multivariate analysis.^[2]

Conclusion

Carcinosarcomas are more highly aggressive tumors with higher recurrence rates and a poorer prognosis compared to transitional

cell carcinomas. The most common presenting symptom of carcinosarcoma is gross hematuria, which is similar to transitional cell carcinoma. Immunohistochemistry is a useful diagnostic tool. Radical cystectomy with neoadjuvant chemoradiotherapy is the most efficient treatment modality. However, larger studies with long-term data would be valuable.

Conflict of interest

No conflict of interest was declared by the authors.

References

1. Baschinsky DY, Chen JH, Vadmal MS, Lucas JG, Bahnson RR, Niemann TH. Carcinosarcoma of the urinary bladder--an aggressive tumor with diverse histogenesis. A clinicopathologic study of 4 cases and review of the literature. *Arch Pathol Lab Med* 2000;124:1172-8.
2. Wang J, Wang FW, Lagrange CA, Hemstreet Iii GP, Kessinger A. Clinical features of sarcomatoid carcinoma (carcinosarcoma) of the urinary bladder: analysis of 221 cases. *Sarcoma* 2010;2010. pii: 454792. Epub 2010 Jul 18.
3. Hoshi S, Sasaki M, Muto A, Suzuki K, Kobayashi T, Tukigi M. Case of carcinosarcoma of urinary bladder obtained a pathologically complete response by neoadjuvant chemoradiotherapy. *Int J Urol* 2007;14:79-81. [\[CrossRef\]](#)
4. Perret L, Chaubert P, Hessler D, Guillou L. Primary heterologous carcinosarcoma (metaplastic carcinoma) of the urinary bladder: a clinicopathologic, immunohistochemical, and ultrastructural analysis of eight cases and a review of the literature. *Cancer* 1998;82:p.1535-49. [\[CrossRef\]](#)
5. Holtz F, JE Fox, MR Abell. Carcinosarcoma of the urinary bladder. *Cancer* 1972;29:294-304. [\[CrossRef\]](#)
6. Sen SE, Malek RS, Farrow GM, Lieber MM. Sarcoma and carcinosarcoma of the bladder in adults. *J Urol* 1985;133:29-30.
7. Lopez-Beltran A, Pacelli A, Rothenberg HJ, Wollan PC, Zincke H, Blute ML, et al. Carcinosarcoma and sarcomatoid carcinoma of the bladder: clinicopathological study of 41 cases. *J Urol* 1998;159:1497-503. [\[CrossRef\]](#)
8. Ogishima T, Kawachi Y, Saito A, Suzuki F, Ishi K, Tanaka T. Sarcomatoid carcinoma and carcinosarcoma of the urinary bladder. *Int J Urol* 2002;9:354-8. [\[CrossRef\]](#)
9. Swaminathan I, Yang TL, Ong BH. Carcinosarcoma of the urinary bladder--case report and literature review. *Ann Acad Med Singapore* 1995;24:640-3.
10. Willis RA. The unusual in tumour pathology. *Can Med Assoc J* 1967;97:1466-79.
11. Tekes A, Kamel IR, Szarf G, Chan TY, Schoenberg MP, Bluemke DA. Carcinosarcoma of the urinary bladder: dynamic contrast-enhanced MR imaging with clinical and pathologic correlation. *AJR Am J Roentgenol* 2003;181:139-42.