

Robotic-assisted laparoscopic surgery in pediatric urology: an update

Pediyatrik ürolojide robot yardımlı laparoskopik cerrahi: bir güncelleme

Yoshiyuki Kojima¹, Jacob Khurgin², Pasquale Casale²

ABSTRACT

Laparoscopic procedures for urological diseases in children, such as nephrectomy, pyeloplasty and orchiopexy, have proven to be safe and effective with outcomes comparable to open procedures. The main drawback has been the relatively steep learning curve for this procedure that is associated with technical difficulties such as suturing and anastomosis. More recently, robotic-assisted laparoscopic surgery (RAS) has gained enormous popularity in adult urology and is increasingly being adopted around the world; however, few pediatric urology series have been reported. RAS has several advantages over conventional laparoscopic surgery, mainly the simplification and precision of exposure and suturing. The robotic arms move in real time with an increased degree of freedom and a magnified, 3-dimensional view. These features render RAS ideal for complex reconstructive surgery in a pediatric urological population. This review discusses the role of RAS in pediatric urology, provides technical aspects of RAS and offers a critical summary of current knowledge on its indications and outcomes. Almost all operations that are classically performed as open or conventional laparoscopic reconstructive surgeries for children with urological anomalies could be replaced by RAS and this procedure may be established as an alternative minimally invasive surgery in the future.

Key words: Laparoscopy; minimally invasive surgery; pediatrics; robotics; urinary tract reconstruction; urology.

ÖZET

Çocuklarda nefrektomi, piyeloplasti ve orşiopeksi gibi ürolojik hastalıklar için laparoskopik prosedürlerin, açık prosedürlerle kıyaslanabilir sonuçlar ile birlikte, güvenli ve etkili olduğu kanıtlanmıştır. Bu prosedürlerin, sütür atma ve anastomoz gibi teknik zorluklarla ilişkili göreceli dik öğrenme eğrisi olması başlıca dezavantajı olmaktadır. Son zamanlarda, robot yardımlı laparoskopik cerrahi (RAS) erişkin ürolojisinde olağanüstü bir popülerlik kazanmıştır ve bütün dünyada giderek artan bir şekilde kabul görmektedir; buna karşın, bir kaç pediyatrik üroloji serisi yayınlanmıştır. RAS konvansiyonel laparoskopik cerrahiye kıyasla bir kaç avantaja sahiptir; bunların başlıcaları pozlama ve sütür atmanın kolaylığı ve hassasiyetidir. Robot kollar artmış bir serbestlik derecesinde ve büyütülmüş 3 boyutlu bir bakış açısıyla gerçek zamanlı olarak hareket etmektedir. Bu özellikler RAS'ı pediyatrik ürolojik popülasyonda kompleks rekonstrüktif cerrahi için ideal yapmaktadır. Bu derleme pediyatrik ürolojide RAS'ın rolünü tartışmakta, RAS'ın teknik yönlerini bildirmekte ve endikasyonları ve sonuçları hakkında güncel bilgilerin eleştirel bir özetini sunmaktadır. Ürolojik anomalisi olan çocuklar için açık veya konvansiyonel laparoskopik rekonstrüktif cerrahi şeklinde klasik olarak yapılan hemen hemen tüm operasyonların yerine RAS yapılabilir ve bu prosedür gelecekte alternatif bir minimal invaziv cerrahi olarak yerleşebilir.

Anahtar sözcükler: İdrar yolu rekonstrüksiyonu; laparoskopi; minimal invaziv cerrahi; pediatri; robotik; üroloji.

¹Department of Nephro-Urology, Nagoya City University Graduate School of Medical Sciences, Nagoya, Japan

²From the Division of Urology, the Children's Hospital of Philadelphia, University of Pennsylvania, Philadelphia, Pennsylvania

Submitted:
27.02.2012

Accepted:
07.03.2012

Correspondence:
Pasquale Casale
Children's Hospital of Philadelphia 34th Street and Civic Center Boulevard Wood Building, 3rd Floor PA 191 Philadelphia, United States
Phone: (267) 426-7012
E-mail: casale@email.chop.edu

©Copyright 2012 by Turkish Association of Urology

Available online at
www.turkishjournalofurology.com

Introduction

Recent advances in equipment and surgical techniques have made minimally invasive surgery (MIS) a well-tolerated and efficient technique. Laparoscopic surgery has gained acceptance as a feasible and reliable treatment option that is associated with minimal morbidity. MIS has several advantages

over standard open surgery, including: more rapid recovery, increased magnification for improved visualization, favorable cosmetic outcome, decreased postoperative pain with consequently lower analgesic requirements, and shorter hospital stays. Conventional laparoscopic procedures for urological diseases in children, such as nephrectomy, pyeloplasty and orchiopexy, have also proven to be safe

and effective with outcomes comparable to open procedures. The main drawback has been the relatively steep learning curve for this procedure that is associated with technical difficulties such as suturing and anastomosis.

Recently, robotic-assisted surgery (RAS) has gained enormous popularity in adult urology. This is especially notable in the increased adoption of robotic-assisted laparoscopic radical prostatectomies for patients with localized prostate cancer around the world.^[1] The da Vinci surgical system (Intuitive Surgical, Sunnyvale, CA, USA) provides several advantages, including the simplification and precision of exposure and suturing. The robotic arms move in real time with an increased degree of freedom and a magnified, 3-dimensional (3D) view. Therefore, RAS has the potential to overcome many of the impediments of conventional laparoscopic surgery and decrease the learning curve for MIS, especially in pediatric reconstructive procedures.^[2,3] RAS also allows the seasoned laparoscopist to become more proficient and refined, expanding the MIS “tool box” to progressively more complex reconstructive procedures (Table 1).^[4]

The RAS procedure most frequently performed in pediatric urology is pyeloplasty for ureteropelvic junction obstruction (UPJO). Recently, many other procedures have been performed robotically, such as ureteral reimplantation and nephrectomy, both total and partial.^[2,3] More difficult reconstructive proce-

dures such as appendicovesicostomy and bladder augmentation can also be performed in children. Long-term outcome analysis of pediatric urology series have remained largely unexplored as RAS is a recently developed technique yet to be established in the pediatric urological population. However, RAS is expected to have a greatly expanding role in the management of many pediatric urological anomalies.

This review discusses the role of RAS in pediatric urology, provides technical aspects of RAS and offers a critical summary of current knowledge on its indications and outcomes in the literature.

General techniques

Typically, an open access technique is used for the 12-mm camera port. The camera port is usually placed in the superior aspect of the umbilicus. The abdomen is insufflated with CO₂ at a pressure of 10–15 mmHg to observe the inside of the abdominal cavity clearly using a 12-mm, 0-degree telescope. A 5-mm endoscope is available; however, it is monocular and cannot provide the 3D image that is available with the larger scope. Two additional working 5-mm trocars are usually inserted. The robotic device is docked from the ipsilateral side in upper urinary tract surgery or the foot of the bed in lower urinary tract surgery and orchiopexy, and the robotic arms are engaged. The robot has instruments that are available in both 8- and 5-mm

Table 1. Procedures and indications for robotic-assisted laparoscopic surgery in pediatric urology

Procedure	Indications	Procedure	Indications
Nephrectomy	Nonfunctioning kidney	Ureteroureterostomy	Duplication anomalies (ectopic ureter or ureterocele)
	Multicystic dysplastic kidney	Pyelolithotomy	Functioning upper pole kidney
	Single-system ectopic ureter	Ureteral re-implantation	Kidney stone
	Malignancy		Vesicoureteral reflux
	Pediatric kidney recipient	Vesicoscopic approach	
Heminephroureterectomy (Partial nephrectomy)	Duplication anomalies (ectopic ureter or ureterocele)	Extravesical approach	Bladder outlet obstruction and dysfunction
	Nonfunctioning upper pole kidney	Appendicovesicostomy (With bladder augmentation)	Neuropathic bladder
	Cystic malformation of the upper pole kidney		Nonneurogenic neurogenic bladder
Pyeloplasty Ureterocalicostomy	Nonfunctioning refluxing lower pole kidney		Posterior urethral valves
	Ureteropelvic junction obstruction		Exstrophy-epispadias complex
	Ureteropelvic junction obstruction		
	Significant lower pole caliectasis	Bladder neck sling	Intrinsic sphincter deficiency
	Failed pyeloplasty	Orchiopexy	Nonpalpable testis (intra-abdominal testis)
	Minimal pelvis	Bladder diverticulectomy	Bladder diverticulum
	Exaggerated intrarenal pelvis		

sizes. A fourth arm is available for grasping and retraction. We utilize "Maryland bipolar forceps" as a grasper, and either a monopolar hook device or curved scissors during dissection. The robotic needle driver can make suturing easier. The techniques and technology have evolved, giving identical results and utilizing 5-0, 6-0, and 7-0 sutures as in open surgeries.

Indications, surgical techniques and outcomes in pediatric urology

1. Nephrectomy

Indication: Indications for nephrectomy may be a poor or non-functioning kidney related to UPJ obstruction due to stones or refluxing nephropathy, a multicystic dysplastic kidney, malignancy such as renal cell carcinoma or Wilms' tumor, and pediatric kidney recipients.^[5-7] Additionally, one of the most satisfying applications is in the diagnosis and therapy of the single-system ectopic ureter in girls presenting with urinary incontinence.^[8]

Surgical technique: Robotic-assisted simple nephrectomy may be somewhat of a technological overkill. However, robotic advantages such as 3D images, increased dexterity, and a decreased learning curve can be helpful for beginners.^[9] Nephrectomies can be performed using transperitoneal or retroperitoneal approaches. The transperitoneal operation is more readily accomplished due to the size of the ports and the arms, especially in the infant population. In the transabdominal approach, the patient is placed in a modified flank position with a 60° elevation of the flank. The camera port is placed in the umbilicus, and the working ports are placed in the midline above the umbilicus and the mid-clavicular line below the umbilicus. In infants, the upper working port should be placed subxiphoid in the midline, and the lower working port as lateral as possible to the rectus muscle. The robot is docked over the ipsilateral shoulder. The procedure is performed as described for the laparoscopic approach. The choice between the transperitoneal and retroperitoneal approaches depends on the surgeon's experience. It may be influenced by the need for additional procedures, such as complete nephroureterectomy or bladder access if ureteral reimplantation is required. Retroperitoneal access is distinct in port placement and patient positioning. Ports are placed posteriorly or laterally depending upon surgeon preference. The size of the robotic arms makes a posterior approach more difficult except in older children (i.e., over 12 years old).

Outcome: As described above, robotic-assisted nephrectomy is possible in children and has certain advantages. However, the expense currently limits its use.^[10] There are no reports available on the outcome of robotic-assisted nephrectomy, and little information is presently available in the literature regarding pediatric robotic-assisted nephrectomy.

2. Heminephroureterectomy (Nephron-sparing surgery)

Indication: Heminephroureterectomy (HNU) and nephron-sparing surgery may be performed for duplication anomalies, such as a nonfunctioning upper pole kidney with an ectopic ureter or ureterocele, cystic malformation of the upper pole kidney, or a nonfunctioning refluxing lower pole kidney.^[11] Because children with a duplication anomaly present with a clear vascular and anatomic plane between the upper and lower pole of the kidney, robotic-assisted HNU (RAHNU) is a good choice for these children.

Surgical technique: RAHNU may also be performed transperitoneally or retroperitoneally. Again, due to the size of the ports and robot arms, we prefer to use the transperitoneal approach. RAHNU is similar to a complete nephrectomy with regards to port placement and initial exposure of the ureters and hilum. The transection of the affected moiety may be performed with either the hook or scissor cautery. Prior to patient positioning, an open-ended ureteral catheter in the unaffected moiety is placed cystoscopically. This allows methylene blue to be injected after the diseased moiety has been transected to ensure no leakage is observed. The procedure is performed as described for the laparoscopic approach. The transperitoneal approach also offers bladder access should it be needed for repair. This typically requires the robot to be re-docked at the foot of the bed. A bladder catheter is kept in place overnight, and the patient can be discharged the same or next day.

Outcome: Pedraza et al.^[12] reported the first case of bilateral RAHNU. The patient was a 4-year-old girl who presented with recurrent urinary tract infections and urinary incontinence.^[12] Olsen et al.^[13] performed a RAHNU using the retroperitoneal approach for 14 girls with a median operative time of 176 minutes. In two patients, the procedure was converted to an open operation. Recently, Lee et al.^[11] reported on the safety and feasibility of RAHNU in children. In their series, RAHNU was completed successfully in nine cases with a mean operative time of 275 minutes, and an estimated blood loss of 49 mL. All patients had a normal remaining renal moiety after the operation. The only complication was an asymptomatic urinoma.

3. Pyeloplasty

Indication: UPJO is characterized by a functionally significant impairment of urinary transport caused by an intrinsic or extrinsic obstruction in the area where the ureter joins the renal pelvis. The main goals of treatment are the relief of symptoms and the preservation of renal function. Open pyeloplasty remains the standard surgical repair. However, laparoscopic pyeloplasty and robotic-assisted laparoscopic pyeloplasty (RAP) have recently been described as feasible reconstructive procedures in children with UPJO. RAP offers significant benefits because of precision with suturing.

Surgical technique: RAP can also be performed using a transperitoneal or retroperitoneal approach. We typically use 6-0 monofilament absorbable suture, but one can utilize any 5-0 or 6-0 suture depending on the size of the patient. We do not recommend anything larger than 6-0 for small children and infants. Positioning and robotic docking is the same as for nephrectomy. The UPJ is exposed trans-mesenterically on the left or by mobilizing the colon on the right. If one chooses colonic mobilization on the left, it must be taken medially over the aorta. The surgical procedures follow the same rules as the conventional laparoscopic approach. A hitch stitch is passed through the abdominal wall and is placed to elevate and stabilize the pelvis if so desired. We use a hitch stitch if a pyelolithotomy is necessary. After the pelvis is incised, the ureter is spatulated laterally and the anastomosis is performed using a running suture (Figure 1). A double pigtail stent is placed after the posterior wall closure is complete. This is performed by placing an 18 gauge angiocatheter through the anterior abdominal wall. A guide wire is then placed in an antegrade fashion. Next, the stent is passed over the guide wire. We recommend filling the bladder with saline or methylene blue so that one can observe the efflux of urine when there is access into the bladder by the stent. The stent can also be placed retrograde with a dangling string, allowing removal in the office setting. A urethral catheter is left for overnight bladder drainage and the double-J ureteral stent is taken out in 2 to 4 weeks.

Outcome: The results described in the literature show success rates of ~95%, similar to the “gold standard” open procedure.^[14-20] Atug et al.^[15] successfully performed RAP on seven children and demonstrated that no patient required additional procedures postoperatively. Additionally, Olsen et al.^[18] performed robotic-assisted retroperitoneoscopic pyeloplasty on 65 children with a success rate of 94%. There are also two reports comparing an age matched cohort of open pyeloplasty versus RAP in children for safety and efficacy.^[17,18] Yee et al. reported on 8 pediatric patients who underwent RAP and were matched by age group with patients undergoing open pyeloplasty. All RAP procedures were successful as determined by subjective data using pain scales and radiological data.^[17] Additionally, Lee et al.^[17] performed a retrospective case-control study of 33 patients undergoing RAP and 33 undergoing open pyeloplasties, reporting a 93.9% success rate with RAP. Of note, these reports demonstrated that RAP had the advantage of decreased hospital stays and decreased narcotics use in comparison with open pyeloplasty, although operative times were increased relative to open pyeloplasty.^[17,18] We previously presented our early experiences with RAP in infants, demonstrating that all nine infants, age 3 to 8 months old, successfully underwent RAP. A larger comparative study is necessary to fully evaluate the outcomes of this approach based on patient age^[19] because a smaller workspace may be a limitation for robotic performance

in laparoscopy.^[21] Additionally, robot-assisted laparoscopic “re-operative” pyeloplasty in children with persistent UPJO after open surgical correction is also reported to be a safe and effective option in the treatment of these challenging cases.^[22,23] Gargollo has reported an innovative “hidden incision endoscopic surgery” (HIDES) for performing pyeloplasty with elimination of visible scars.^[24] All ports are placed at the umbilicus or below the line of a Pfannenstiel incision. A total of 8 patients in the series underwent pyeloplasties or redo pyeloplasties with a mean surgery time of 150 minutes. Improved patient and parent cosmetic satisfaction is reported. The Children’s Hospital Boston experience with robotic pyeloplasty in 155 patients during 2002-2009 has been reported by Minnillo et al., demonstrating long-term surgical success and complication rates comparable to open surgery.^[25]

4. Ureterocalicostomy

Indication: Robotic-assisted ureterocalicostomy (RAUC) is a potential option in patients with UPJO and significant lower pole caliectasis, patients with failed pyeloplasty and a minimal pelvis, or patients with an exaggerated intrarenal pelvis.^[26]

Surgical technique: A transperitoneal approach is implemented. The colon is reflected, exposing the massively dilated kidney. The ureters are transected and ligated with absorbable sutures at the level of the renal pelvis or crossing vessels if the pelvis is not readily accessible. The ureters are spatulated before transection. The most dependent lower pole calyx is amputated with hot shears. There is a minimal amount of bleeding from the thinned parenchyma of the lower pole system, and the electrocautery of the hot shears easily controls any bleeding. The posterior anastomosis is performed with a 5-0 absorbable suture in a running fashion. The ureteral stent is then placed in the same fashion as in RAP, as described above. The anterior anastomosis

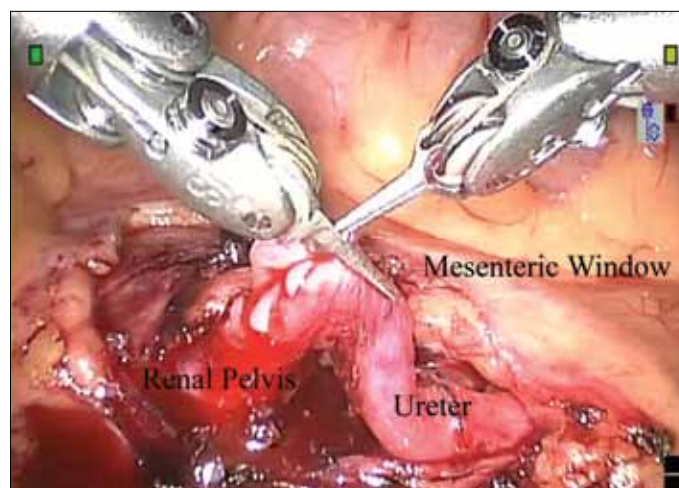


Figure 1. Spatulation of left ureter during robotic pyeloplast through a transmesenteric approach.

is performed in an interrupted manner; allowing visualization and approximation of the renal collecting system to the ureteral mucosa without placing tension on the renal parenchyma (Figure 2). The anterior sutures are then tied in groups, so that the last few suture placements are unobstructed and precise. The stent is removed 6 weeks after surgery with a retrograde ureteropyelogram to visualize the anastomosis.

Outcome: We performed RAUC for nine patients with UPJO (mean age 6.5 years). The mean operative time was 168 minutes, and the mean hospital stay was 21 hours.^[26] There was no evidence of obstruction following the operation in any patient.

5. Ureteroureterostomy

Indication: We perform robotic-assisted ureteroureterostomy (RAUU) on children with a duplicated collecting system showing an upper pole ectopic ureter with function in that moiety. Function is determined by pre-operative studies. Typically, a common sheath reimplantation, HNU or upper tract reconstruction seems to be the treatment of choice for ectopia. The choice of procedure depends on concomitant complications, such as the presence of lower pole reflux or the need for bladder neck reconstruction with ectopia.

Surgical techniques: Surgery is performed via a transperitoneal approach. All patients undergo cystoscopic evaluation with retrograde ureteropyelogram and open-ended ureteral catheter placement into the lower pole ureter prior to robotic intervention. The external portion of the ureteral catheter is secured to the urethral catheter and prepped into the operative laparoscopic field. Access to the open-ended ureteral catheter during the operation is paramount (Figure 3). The catheter is instilled with methylene blue as needed to ensure the integrity of the collecting system and the anastomosis. The ureteral catheter also assures access for placement of an indwelling stent after the posterior anastomosis is completed. The upper pole ectopic ureter is spatulated before transection. Re-approximations of the upper pole ureter to the lower pole ureter are performed with 6-0 absorbable suture in a running fashion. The entire distal ureteral segment to the vagina is removed at the level of the vagina. In boys, the upper pole ectopic ureter to the prostate is removed at the level of the prostate via the same transperitoneal approach. We do not leave ureteral stumps when we perform these procedures laparoscopically due to the relative ease of access with a transperitoneal approach.

Outcome: An earlier experience with complex upper tract reconstruction in children with duplicated systems found the approach to be easier to perform using the robotic procedure compared to a laparoscopic one with regards to both renal and bladder reconstructions.^[27] Passerotti et al.^[28] have reported that RAUU is a reliable and efficient technique for the correction of ureteral obstruction in children. The procedure can be applied to

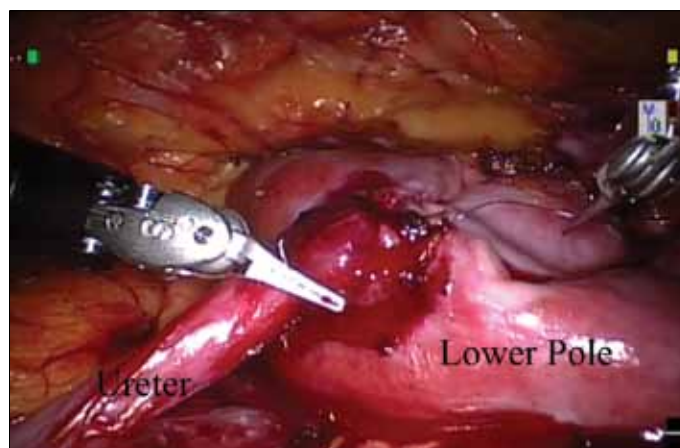


Figure 2. Robotic-assisted laparoscopic ureterocalicostomy completed anastomosis to the lower pole.

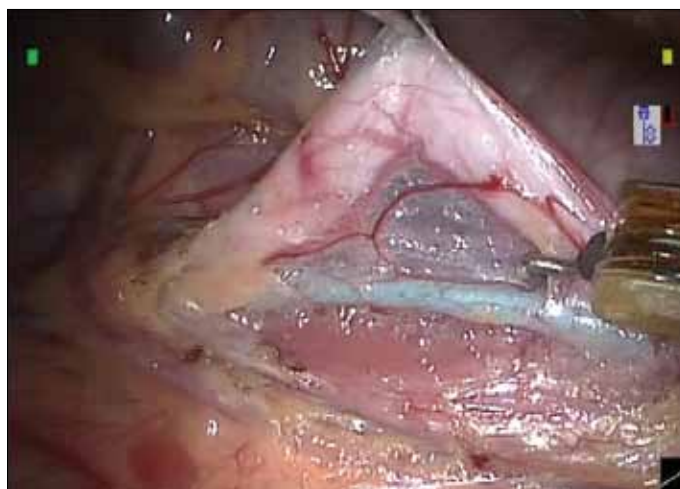


Figure 3. Robotic-assisted laparoscopic ureteroureterostomy. The visualization of the lower pole ureter is aided in this 6 month old infant by a 3 Fr whistle tip catheter placed cystoscopically prior to the robotic manipulation.

any pathology that requires ureteral reconstruction, whether it is a duplicated or a single system.

6. Ureteral Reimplantation

Indication: Primary vesicoureteral reflux (VUR) is a common anomaly affecting the vesicoureteric junction, and open ureteral reimplantation is the established procedure for managing them surgically. Indications for ureteral reimplantation include breakthrough infections, worsening reflux, and higher grade reflux. Sub-ureteral injection of implant materials has also shown much promise in recent years, with success rates approaching open surgery after 2 or more injections. Successful laparoscopic reimplantation has also been described.^[29] Robotics can be similarly implemented in the various ureteral reimplantation techniques, i.e., extravesical and vesicoscopic.^[30-34]

6. 1. Vesicoscopic approach

Surgical technique: The laparoscopic Cohen procedure using pneumovesicum was first described in a pig model in 2003.^[32] A description of its limitations has been described, and the authors do not advocate this approach in bladders that are less than 130 mL in voiding cystourethrogram studies. The patient is placed in a supine position with the legs apart. The bladder is filled with saline solution through the urethra. Using an open technique or visualization via a flexible pediatric cystoscope, the 12-mm camera port is placed in the midline at the bladder dome. A 3-0 absorbable suture secures the bladder wall and skin to the trocar. The working ports, either 8- or 5-mm, are positioned midway between the umbilicus and pubis at the mid-clavicular line. Ports are fixed to the abdominal wall using a stitch, which is also used to close the bladder. The bladder is filled with CO₂ to drain the saline and the robotic device is brought over the patient's feet. Similar to the open technique, ureteral dissection starts after placing a 6 cm segment of a 5 Fr feeding tube or a 4 Fr open-ended ureteral catheter and securing it to the ureter with a 4-0 absorbable suture. Mobilization of the ureters is performed as in the laparoscopic pneumovesical procedure using the hook or scissor cautery. The submucosal tunnels are created by scissor dissection from the original hiatus to the opposite side of the trigone, followed by incising the mucosa at the site of the new mucosal hiatus. Anastomosis of the ureters is performed after bringing the ureters through the mucosal tunnel. Anchoring sutures of 4-0 absorbable suture are used to secure the ureter to the bladder musculature and the mucosal cuff is attached with 5-0 absorbable suture. The mucosa over the original hiatus is closed with a running 5-0 absorbable suture. If the patient had previous injection therapy, it should be removed. The working ports are then removed, and the bladder holding stitches are tied. The flexible cystoscope is used to inspect the inside of the bladder. The port sites are also closed at the fascial level. The bladder catheter is kept in place overnight.

Outcome: There are few reports of this approach using conventional laparoscopy and only one using robotic assistance.^[29,33] Peters et al. described their 5-case experience with robotic-assisted transvesical cross-trigonal reimplantation (Cohen procedure). Maintaining pneumovesicum can be difficult, and trocar tweaking is necessary. Additionally, small capacity bladders are difficult to navigate. While this technique is extremely challenging, the visualization and control are excellent, and we must continue to develop this approach.

6. 2. Extravesical approach

Surgical technique: The extravesical approach can be performed unilaterally or bilaterally following the same steps as the open Lich-Gregoir technique. Cystoscopy is performed to place open-ended ureteral catheters to aid in the dissection. With the patient in the supine position, an open technique is used to place the first trocar and the 12-mm camera port in the umbilicus. The working ports, 8- or 5-mm, are positioned in the mid-clavicular

line bilaterally, approximately 1 cm below the umbilical line. If the child has a pubo-umbilical length less than 8 cm, then the midline camera port must be placed above the umbilicus between the xyphoid and umbilicus to prevent robotic arm collision. The robot is docked over the patient's feet. The technique that follows has the same steps as the Lich-Gregoir open procedure. After opening the peritoneum, the ureter is dissected anterior to the uterus and just over the posterior bladder wall. The ureter is freed from the surrounding tissue while keeping its vessels intact. The pelvic plexus is readily identified medial and caudal to the ureter. Care is taken in each case to identify the pelvic plexus, avoiding injury to the area and allowing ureteral mobilization at the hiatus. Approximately 4-5 cm is dissected to permit mobility and to prevent kinking as the bladder tunnel is created for the ureter. A hitch stitch through the posterior bladder wall can be used to improve the exposure of the ureteral hiatus if the bladder is large. A detrusor trough is created by incising the muscularis of the bladder for approximately 3 cm and developing flaps with the cautery scissors. Any perforations of the mucosa are closed using a 5-0 absorbable suture prior to trough closure. The bladder muscularis is then closed over the ureter, using a 4-0 absorbable interrupted suture. Care must be taken to avoid any kinking or excessive compression of the ureter to prevent obstruction (Figure 4). Closure is performed proximal to distal or vice versa. In the latter, the ureter is well visualized, but the needle must be passed under the ureter each time the suture is placed. We incorporate the adventitia of the ureter with each suture to ensure it does not slip back during the healing process. The urethral catheter is removed the next morning, and the child is discharged after voiding.

Outcome: Open extravesical ureteral reimplantation was reported to be an effective method for repairing reflux without ureteral obstruction. It can result in a high rate of transient postoperative urinary retention even when detrusor dissection is minimized.^[34] However, we reported a success rate of 97.6% for a total of 41 patients who underwent robotic-assisted laparoscopic extravesical re-implantation for bilateral VUR. This was accomplished without complications such as urinary retention or exacerbation of dysfunctional voiding.^[35] The improved visualization can avoid injury to the neurovascular plexus, which is situated immediately lateral to the ureteral hiatus, and may decrease the incidence of postoperative urinary retention. More recently, Kasturi et al.^[36] reviewed 150 patients who underwent bilateral robotic-assisted extravesical ureteral reimplantation for VUR with a 99.3% success rate and minimal morbidity, reaffirming the safety and efficacy of this procedure.

7. Appendicovesicostomy

Indication: Bladder outlet obstruction and dysfunction caused by a neuropathic bladder, a nonneurogenic neurogenic bladder, posterior urethral valves and the exstrophy-epispadias complex

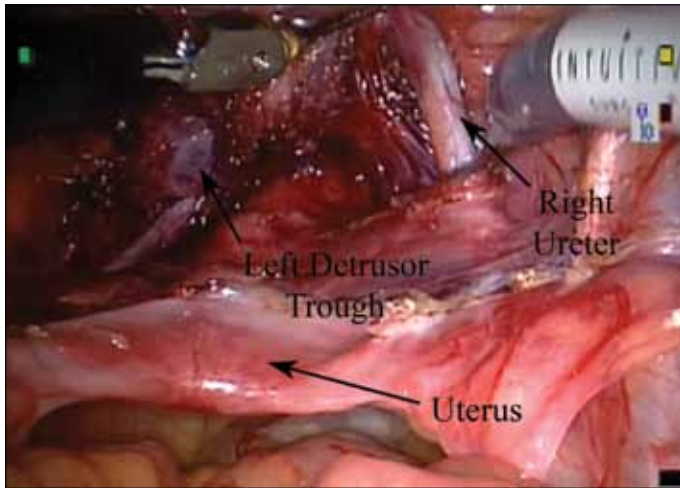


Figure 4. Robotic-assisted laparoscopic ureteral reimplantation (extravesical approach). A detrusor tunnel is created for an extravesical ureteral re-implant.

can often lead to urinary incontinence and renal dysfunction in children. Although some of these children can be treated medically or with minimally invasive intervention, the standard of care for most of them is augmentation cystoplasty with a continent catheterizable channel, usually an appendicovesicostomy.

Surgical technique: As authors of the purely laparoscopic procedure, we can honestly state that this procedure is facilitated extremely well with the robot. The patient is placed in the supine position and in Trendelenburg. Three ports are utilized. The 12-mm camera port is placed in the umbilicus and the other two 8-mm working ports on the right and left sides in the mid-clavicular line at the level of the anterior superior iliac spines. The procedure commences with cecal mobilization. Care is taken to protect the appendiceal mesentery and mobilize an adequate length. Once the cecum is mobilized, the appendix is separated from the cecum, leaving a small cuff of cecum with the appendix. The bladder is filled with saline and the optimal position is determined depending on the appendix length, the mobility of the bladder, and location of the stoma. A 4 cm detrusorrhaphy is made. The appendix is anastomosed to a small mucosal opening in the apex of the detrusor trough and the defect is closed using a 4-0 absorbable interrupted suture. The base of the appendix is brought up to reach the umbilicus or the right lower quadrant. We prefer using the right lower quadrant trocar site to create a catheterizable stoma using a V flap technique.

Outcome: There are several case reports of a robotic-assisted Mitrofanoff procedure in children,^[37-42] and one that has described a purely laparoscopic procedure. Pedraza et al.^[37] reported the first case of an appendicovesicostomy that was performed entirely laparoscopically using a robotic system.

Gundeti et al. have reported on a robotic-assisted laparoscopic Mitrofanoff appendicovesicostomy and augmentation ileocystoplasty.^[38] An expanded series of six patients demonstrates the feasibility of this procedure robotically, although one patient required conversion to an open ileal augmentation.^[39] Additionally, there are two cases of robot-assisted laparoscopy for simultaneous reconstruction of a continent urinary diversion using the Mitrofanoff principle and the antegrade continent enema.^[40,41,43]

8. Orchiopexy

Indication: Nonpalpable testes, which comprise approximately 20% of undescended testes, may include testicular agenesis, intra-abdominal testicular nubbin, intra-abdominal testis, vanishing testis, extra-abdominal testicular nubbin or intracanalicular testis that are not palpable despite careful physical examination. Laparoscopy was originally performed for diagnostic purposes and has now become more feasible in pediatric patients with nonpalpable testes. It allows for diagnosis and for adequate therapy, thus becoming the gold standard for managing nonpalpable testes.^[44,45] Once the testis has been identified intra-abdominally, laparoscopic orchiopexy or Fowler-Stephens orchiopexy is generally indicated for the intra-abdominal variant.^[46]

Surgical technique: The advantages of laparoscopic orchiopexy for intra-abdominal testes are the ability to start treatment as soon as a diagnosis is made with MIS. Improving upon the same skill set described in conventional laparoscopy, robotic surgery can be used in difficult cases, such as high intra-abdominal testes, particularly for staged surgeries. The patient is placed supine in the Trendelenburg position with the ipsilateral side elevated. We routinely empty the bladder to aid in access and visualization. Port placement mimics conventional laparoscopy with the camera port in the umbilicus and two working ports, one on the ipsilateral side of the testis in the mid-clavicular line above the umbilicus, and the other contralaterally below the umbilicus, also in the mid-clavicular line.

Outcome: Najmaldin and Antao performed bilateral orchiopexy and excision of a Müllerian remnant using robotic-assisted laparoscopic surgery for a boy.^[47] Although readily available, we have not found the robot to be useful in orchiopexies because reconstruction is not part of the procedure.

9. Bladder Diverticulectomy

Indication: Children with symptomatic congenital bladder diverticula (CBD) warrant surgical intervention. Symptoms may include voiding dysfunction, recurrent urinary tract infections and hematuria.^[48,49] A connective tissue disorder may be found in some patients with CBD.^[50-52] The presence of secondary bladder diverticula is attributed to bladder outlet obstruction. Proper diagnosis is based on voiding cystourethrogram,

although ultrasonography has a role in the initial evaluation and has even identified bladder diverticula prenatally.^[53] Further anatomic delineation of the diverticulum can be facilitated by magnetic resonance urogram or intravenous pyelogram.

Surgical technique: In our institution, robotic-assisted laparoscopy bladder diverticulectomy begins with a cystoscopic evaluation to note the location of the diverticulum and its relationship to the nearest ureteral orifice. A ureteral catheter is used to identify the ipsilateral ureter. The patient is then placed in a supine, Trendelenburg position with legs apart. A camera port is inserted at the umbilicus and two working ports are placed slightly caudal to the level of the umbilicus at each mid-clavicular line. Transperitoneal dissection begins by opening the peritoneal reflection at the posterior bladder and continuing down to the stalk of the diverticulum. Identification of the diverticulum can be aided by placing a catheter directly into the diverticulum and inflating the balloon (Figure 5). The light of a flexible cystoscope placed into the diverticulum may also be used to provide orientation to the site from within the peritoneum. After excising the diverticulum, the bladder is closed in two running layers of 4-0 absorbable suture. The ureteral and urethral catheters are maintained until the first postoperative day. Patients are discharged after completing a void trial.

Outcome: Laparoscopic bladder diverticulectomy was first described in 1992 via a transperitoneal approach followed by reports of extraperitoneal approaches.^[54,55] The current literature has several small robot-assisted laparoscopic diverticulectomy series in adults.^[56] Pediatric reports are scarce, with the only published robotic bladder diverticulum repair coming from Meeks et al. in 2009.^[57] Potential advantages are 3D visualiza-

tion and improved suturing and dissection dexterity. Our preliminary experience has shown operative times, complication rates and postoperative courses similar to those published for open and conventional laparoscopic bladder diverticulum repairs.

10. Others

A variety of other procedures have been performed using robotics in children, such as pyelolithotomy,^[58] correction of retrocaval ureter,^[59] adrenalectomy, bladder neck sling,^[60] ureteropyelostomy, excision of Müllerian duct remnants,^[47] and sacrocolpopexy just to name a few. In all cases, the procedure was completed successfully in operative times comparable to open approaches. The variety of these cases indicates that the potential flexibility of this system is vast and appropriate for challenging cases. This is of particular importance in pediatric urology as our patients require a wide range of surgical procedures for optimal care.

Postoperative Pain Management

Postoperative pain management is always an area for debate. Injection of the port sites aids in postoperative pain control. In our experience, an anti-inflammatory such as ketorolac has also been beneficial in pain control. We utilize intrathecal opioid injection for all patients undergoing robotic procedures at our institution. We have found that this results in a decreased length of stay and decreased postoperative pain.^[61] There are no intravenous rescues in the first 24 hours postoperatively. Ketorolac is our drug of choice for added pain management. On the other hand, Freilich et al.^[62] have recently reported that the administration of intraperitoneal aerosolized bupivacaine just prior to incising the perirenal fascia appears to be a simple, effective and low-cost method to reduce postoperative pain in children undergoing RAS.

Conclusion

RAS enables a revolutionary advance in pediatric urological surgery and provides great benefits for patients and surgeons. It allows in situ surgery with unparalleled exposure, surpassing visualization of an open approach even with a large incision. Robotic technology will certainly continue to evolve with or without us. We must embrace it and realize its limitations so we can help shape it. For the safety and well-being of our patients we, the ultimate users of such systems, must be actively involved in their evolution.

While further outcome studies and more prospective randomized comparison studies with open surgery or conventional laparoscopic surgery are needed, almost all operations that are classically performed as open or conventional laparoscopic reconstructive surgery for children with urological anomalies could be replaced by RAS and may be established as an alternative MIS in the future.

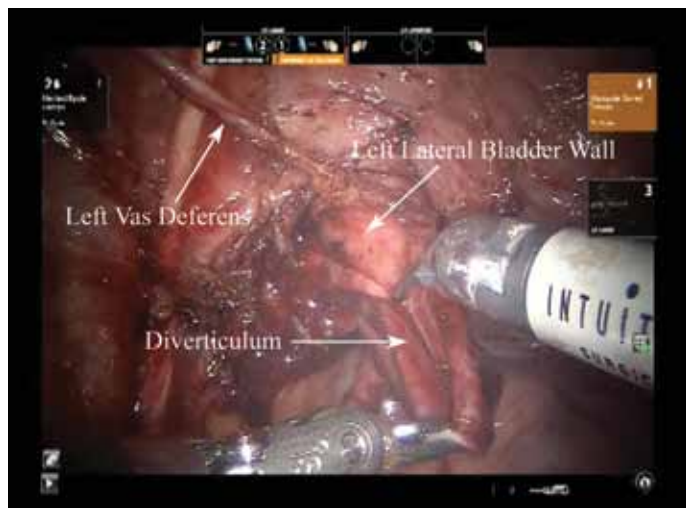


Figure 5. Robotic-assisted laparoscopic bladder diverticulectomy with visualization of the diverticulum.

Conflict of interest

No conflict of interest was declared by the authors.

References

- McCullough TC, Barret E, Cathelineau X, Rozet F, Galiano M, Vallancien G. Role of robotics for prostate cancer. *Curr Opin Urol* 2009;19:65-8. [\[CrossRef\]](#)
- Peters C. Laparoscopy in pediatric urology: adoption of innovative technology. *BJU Int* 2003;92:52-7. [\[CrossRef\]](#)
- Peters CA. Robotic assisted surgery in pediatric urology. *Pediatr Endosurgery Innovative Tech* 2003;7:403-13. [\[CrossRef\]](#)
- Peters CA. Robotically assisted surgery in pediatric urology. *Urol Clin North Am* 2004;31:743-52. [\[CrossRef\]](#)
- Yucel S, Brown B, Bush NC, Ahmad N, Baker LA. What to anticipate with experience in pediatric laparoscopic ablative renal surgery. *J Urol* 2008;179:697-702. [\[CrossRef\]](#)
- Basiri A, Simforoosh N, Heidari M, Moghaddam SM, Otookesh H. Laparoscopic v open donor nephrectomy for pediatric kidney recipients: preliminary report of a randomized controlled trial. *J Endourol* 2007;21:1033-6. [\[CrossRef\]](#)
- Cervellione RM, Gordon M, Hennayake S. Financial analysis of laparoscopic versus open nephrectomy in the pediatric age group. *J Laparoendosc Adv Surg Tech A* 2007;17:690-2. [\[CrossRef\]](#)
- Peters CA. Laparoscopy in pediatric urology. *Curr Opin Urol* 2004;14:67-73. [\[CrossRef\]](#)
- Koyle MA, Woo HH, Kavoussi LR. Laparoscopic nephrectomy in the first year of life. *J Pediatr Surg* 1993;28:693-5. [\[CrossRef\]](#)
- Harrell WB, Snow BW. Minimally invasive pediatric nephrectomy. *Curr Opin Urol* 2005;15:277-81. [\[CrossRef\]](#)
- Lee RS, Sethi AS, Passerotti CC, Retik AB, Borer JG, Nguyen HT, et al. Robot assisted laparoscopic partial nephrectomy: a viable and safe option in children. *J Urol* 2009;181:823-8. [\[CrossRef\]](#)
- Pedraza R, Palmer L, Moss V, Franco I. Bilateral robotic assisted laparoscopic heminephroureterectomy. *J Urol* 2004;171:2394-5. [\[CrossRef\]](#)
- Olsen LH, Jørgensen TM. Robotically assisted retroperitoneoscopic heminephrectomy in children: initial clinical results. *J Pediatr Urol* 2005;1:101-4. [\[CrossRef\]](#)
- Olsen LH, Jorgensen TM. Computer assisted pyeloplasty in children: the retroperitoneal approach. *J Urol* 2004;171:2629-31. [\[CrossRef\]](#)
- Atug F, Woods M, Burgess SV, Castle EP, Thomas R. Robotic assisted laparoscopic pyeloplasty in children. *J Urol* 2005;174:1440-2. [\[CrossRef\]](#)
- Yee DS, Shanberg AM, Duel BP, Rodriguez E, Eichel L, Rajpoot D. Initial comparison of robotic-assisted laparoscopic versus open pyeloplasty in children. *Urology* 2006;67:599-602. [\[CrossRef\]](#)
- Lee RS, Retik AB, Borer JG, Peters CA. Pediatric robot assisted laparoscopic dismembered pyeloplasty: comparison with a cohort of open surgery. *J Urol* 2006;175:683-7. [\[CrossRef\]](#)
- Olsen LH, Rawashdeh YF, Jorgensen TM. Pediatric robot assisted retroperitoneoscopic pyeloplasty: a 5-year experience. *J Urol* 2007;178:2137-41. [\[CrossRef\]](#)
- Kutikov A, Nguyen M, Guzzo T, Canter D, Casale P. Robot assisted pyeloplasty in the infant-lessons learned. *J Urol* 2006;176:2237-9. [\[CrossRef\]](#)
- Franco I, Dyer LL, Zelkovic P. Laparoscopic pyeloplasty in the pediatric patient: hand sewn anastomosis versus robotic assisted anastomosis is there a difference? *J Urol* 2007;178:1483-6. [\[CrossRef\]](#)
- Thakre AA, Bailly Y, Sun LW, Van Meer F, Yeung CK. Is smaller workspace a limitation for robot performance in laparoscopy? *J Urol* 2008;179:1138-42. [\[CrossRef\]](#)
- Passerotti CC, Nguyen HT, Eisner BH, Lee RS, Peters CA. Laparoscopic reoperative pediatric pyeloplasty with robotic assistance. *J Endourol* 2007;21:1137-40. [\[CrossRef\]](#)
- Hemal AK, Mishra S, Mukharjee S, Suryavanshi M. Robot assisted laparoscopic pyeloplasty in patients of ureteropelvic junction obstruction with previously failed open surgical repair. *Int J Urol* 2008;15:744-6. [\[CrossRef\]](#)
- Gargollo PC. Hidden incision endoscopic surgery: description of technique, parental satisfaction and applications. *J Urol* 2011;185:1425-31. [\[CrossRef\]](#)
- Minnillo BJ, Cruz JAS, Sayao RH, Passerotti CC, Houck CS, Meier PM, et al. Long-Term Experience and Outcomes of Robotic Assisted Laparoscopic Pyeloplasty in Children and Young Adults. *J Urol* 2011;185:1455-60. [\[CrossRef\]](#)
- Casale P, Mucksavage P, Resnick M, Kim SS. Robotic ureterocalicostomy in the pediatric population. *J Urol* 2008;180:2643-8. [\[CrossRef\]](#)
- Kutikov A, Nguyen M, Guzzo T, Canter D, Casale P. Laparoscopic and robotic complex upper tract reconstruction in the child with duplex collecting system. *J Endourol* 2007;21:619-22. [\[CrossRef\]](#)
- Passerotti CC, Diamond DA, Borer JG, Eisner BH, Barrisford G, Nguyen HT. Robot-assisted laparoscopic ureteroureterostomy: description of technique. *J Endourol* 2008;22:581-4. [\[CrossRef\]](#)
- Yeung CK, Sihoe JD, Borzi PA. Endoscopic cross-trigonal ureteral reimplantation under carbon dioxide bladder insufflation: a novel technique. *J Endourol* 2005;19:295-9. [\[CrossRef\]](#)
- Hayn MH, Smaldone MC, Ost MC, Docimo SG. Minimally invasive treatment of vesicoureteral reflux. *Urol Clin North Am* 2008;35:477-88. [\[CrossRef\]](#)
- Lendvay T. Robotic-assisted laparoscopic management of vesicoureteral reflux. *Adv Urol* 2008;732942.
- Olsen LH, Deding D, Yeung CK, Jorgensen TM. Computer assisted laparoscopic pneumovesical ureter reimplantation a.m. Cohen: initial experience in a pig model. *APMIS* 2003;109:23-5.
- Peters CA, Woo R. Intravesical robotically assisted bilateral ureteral reimplantation. *J Endourol* 2005;19:618-1. [\[CrossRef\]](#)
- Lipski BA, Mitchell ME, Burns MW. Voiding dysfunction after bilateral extravesical ureteral reimplantation. *J Urol* 1998;159:1019-21. [\[CrossRef\]](#)
- Casale P, Patel RP, Kolon TF. Nerve sparing robotic extravesical ureteral reimplantation. *J Urol* 2008;179:1987-9. [\[CrossRef\]](#)
- Kasturi S, Sehgal SS, Christman MS, Lambert SM, Casale P. Prospective Long-term Analysis of Nerve-sparing Extravesical Robotic-assisted Laparoscopic Ureteral Reimplantation. *Urology* 2011 Dec 23 [Epub ahead of print]
- Pedraza R, Weiser A, Franco I. Laparoscopic appendicovesicostomy (Mitrofanoff procedure) in a child using the da Vinci robotic system. *J Urol* 2004;171:1652-3. [\[CrossRef\]](#)
- Gundeti MS, Eng MK, Reynolds WS, Zagaja GP. Pediatric robotic-assisted laparoscopic augmentation ileocystoplasty and Mitrofanoff appendicovesicostomy: complete intracorporeal--initial case report. *Urology* 2008;72:1144-7. [\[CrossRef\]](#)

39. Gundeti MS, Acharya SS, Zagaja GP, Shalhav AL. Paediatric robotic-assisted laparoscopic augmentation ileocystoplasty and Mitrofanoff appendicovesicostomy (RALIMA): feasibility of and initial experience with the University of Chicago technique. *BJU Int* 2011;107:962-9. [\[CrossRef\]](#)
40. Thakre AA, Yeung CK, Peters C. Robot-assisted Mitrofanoff and Malone antegrade continence enema reconstruction using divided appendix. *J Endourol* 2008;22:2393-6. [\[CrossRef\]](#)
41. Lendvay TS, Shnorhavorian M, Grady RW. Robotic-assisted laparoscopic Mitrofanoff appendicovesicostomy and antegrade continent enema colon tube creation in a pediatric spina bifida patient. *J Laparoendosc Adv Surg Tech A* 2008;18:310-2. [\[CrossRef\]](#)
42. Storm DW, Fulmer BR, Sumfest JM. Laparoscopic robot-assisted appendicovesicostomy: an initial experience. *J Endourol* 2007;21:1015-7. [\[CrossRef\]](#)
43. Casale P, Feng WC, Grady RW, Joyner BD, Lee RS, Mitchell ME. Intracorporeal laparoscopic appendicovesicostomy: a case report of a novel approach. *J Urol* 2004;171:1899-900. [\[CrossRef\]](#)
44. Radmayr C, Oswald J, Schwentner C, Neururer R, Peschel R, Bartsch G. Long-term outcome of laparoscopically managed nonpalpable testes. *J Urol* 2003;170:2409-11. [\[CrossRef\]](#)
45. Gatti JM, Ostlie DJ. The use of laparoscopy in the management of nonpalpable undescended testes. *Curr Opin Pediatr* 2007;19:349-53. [\[CrossRef\]](#)
46. Casale P, Canning DA. Laparoscopic orchiopexy. *BJU Int* 2007;100:1197-1206. [\[CrossRef\]](#)
47. Najmaldin A, Antao B. Early experience of tele-robotic surgery in children. *Int J Med Robot* 2007;3:199-202. [\[CrossRef\]](#)
48. Rawat J, Rashid, KA, Kanojia RP. Diagnosis and management of congenital bladder diverticulum in infancy and childhood: experience with nine cases at a tertiary health center in a developing country. *Int Urol Nephrol* 2009;41:237-42. [\[CrossRef\]](#)
49. Bogdanos J, Paleodimos I, Korakianitis G, Stephanidis A, Androulakakis PA. The large bladder diverticulum in children. *J Pediatr Urol* 2005;1:267-72. [\[CrossRef\]](#)
50. Babbitt DP, Dobbs J, Boedecker RA. Multiple bladder diverticula in Williams "Elfin-Facies" syndrome. *Pediatr Radiol* 1979;8:29-31. [\[CrossRef\]](#)
51. Daly WJ, Rabinovitch HH. Urologic abnormalities in Menkes' syndrome. *J Urol* 1981;126:262-4
52. Levard G, Aigrain Y, Ferkadji L, Elghoneimi A, Pichon J, Boureau M. Urinary bladder diverticula and the Ehlers-Danlos syndrome in children. *J Pediatr Surg* 1989;24:1184-6. [\[CrossRef\]](#)
53. Gaudet R, Heim N, Merviel P, Lemercier D, Dumont A, Audry G, et al. Prenatal diagnosis of a congenital bladder diverticulum. Case report and benefits of prenatal diagnosis. *Fetal Diagn Ther* 1999;14:301-5. [\[CrossRef\]](#)
54. Parra RO, Jones JP, Andrus CH, Hagood PG. Laparoscopic diverticulectomy: preliminary report of a new approach for the treatment of bladder diverticulum. *J Urol* 1992;148:869-71.
55. Nadler RB, Pearle MS, McDougall EM, Clayman RV. Laparoscopic extraperitoneal bladder diverticulectomy: initial experience. *Urology* 1995;45:524-7. [\[CrossRef\]](#)
56. Moreno Sierra J, Galante-Romo I, Ortiz-Oshiro E, Castillon-Vela IT, Fernandez-Perez C, Silmi-Moyano A. Bladder Diverticulum Robotic Surgery: Systematic Review of Case Reports. *Urol Int* 2010;85:381-5. [\[CrossRef\]](#)
57. Meeks JJ, Zhao L, Greco KA, Macejko A, Nadler RB. Pediatric robotic-assisted laparoscopic diverticulectomy. *Urology* 2009;73:323-7. [\[CrossRef\]](#)
58. Lee RS, Passerotti CC, Cendron M, Estrada CR, Borer JG, Peters CA. Early results of robot assisted laparoscopic lithotomy in adolescents. *J Urol* 2007;177:2306-9. [\[CrossRef\]](#)
59. Gundeti MS, Duffy PG, Mushtaq I. Robotic-assisted laparoscopic correction of pediatric retrocaval ureter. *J Laparoendosc Adv Surg Tech A* 2006;16:422-4. [\[CrossRef\]](#)
60. Storm DW, Fulmer BR, Sumfest JM. Robotic-assisted laparoscopic approach for posterior bladder neck dissection and placement of pediatric bladder neck sling: initial experience. *Urology* 2008;72:1149-52. [\[CrossRef\]](#)
61. Ganesh A, Kim A, Casale P, Cucchiario G. Low-dose intrathecal morphine for postoperative analgesia in children. *Anesth Analg* 2007;104:271-6. [\[CrossRef\]](#)
62. Freilich DA, Houck CS, Meier PM, Passerotti CC, Retik AB, Nguyen HT. The effectiveness of aerosolized intraperitoneal bupivacaine in reducing postoperative pain in children undergoing robotic-assisted laparoscopic pyeloplasty. *J Pediatr Urol* 2008;4:337-40. [\[CrossRef\]](#)