

An unusual foreign body in the urinary bladder: beading awl

Mesanede nadir bir yabancı cisim: Tığ

Uğur Balcı, Mustafa Ozan Horsanalı, Mahir Kartalmış, Cengiz Girgin, Çetin Dinçel

Atatürk Research and Training Hospital, First Urology Clinic, İzmir, Turkey

Abstract

Many different foreign bodies have been found in the urinary bladder. Usually, these foreign bodies were self-inserted for autoeroticism, frequently in patients with psychiatric disorders. Here we report the case of a 34-year-old female patient who inserted a beading awl through the urethra into the bladder during sexual intercourse and was treated with open surgery.

Key words: Female; foreign bodies; urinary bladder.

Özet

Mesanede çok farklı yabancı cisimler bulunmuştur. Bu yabancı cisimler genellikle cinsel amaçlı olarak kişinin kendisi tarafından mesaneye sokulmaktadır ve sıklıkla psikiyatrik bozukluklu olan hastalarda görülmektedir. Burada cinsel ilişki esnasında üretradan mesanesine tığ sokan ve açık cerrahi ile tedavi edilen 34 yaşındaki kadın hastayı sunduk.

Anahtar sözcükler: Kadın; mesane; yabancı cisimler.

Submitted (Geliş tarihi): 16.05.2010

Accepted after revision (Düzeltilme sonrası kabul tarihi): 23.08.2010

Several different types of foreign bodies have been identified in the urinary bladder and urethra. The insertion of metallic objects, electric wire, pocket battery, telephone cable, and little fish has been reported in the literature.^[1-5] Usually, these foreign bodies are self-inserted for masturbation, frequently in patients with psychiatric disorders. Some cases were iatrogenic or occurred accidentally after treatment attempts for the removal of urethral or ureteral catheter fragments.^[6] Sometimes foreign bodies such as intrauterine devices migrate to the bladder from adjacent organs.^[7] In this case report, we present a 34-year-old female patient who inserted a beading awl through the urethra into the bladder during sexual intercourse.

Case report

A 34-year-old female patient presented to the emergency room with vaginal and suprapubic pain. Her history included self-insertion of a beading awl through the urethra into the bladder during sexual intercourse with her husband a few hours prior to presentation at the clinic. She reported that it was not their first experience with the use of foreign bodies

for sexual purposes. She also had a history of major depression, and she had used sertraline 50 mg daily for one year. No orgasmic problem was detected in the patient. Physical examination was normal. Routine laboratory findings were within the normal range. Urine analysis showed microscopic hematuria. Cystography revealed a radiopaque foreign body approximately 5 cm in length, and there was no bladder perforation (Fig. 1). Ultrasonography demonstrated that the foreign body was longer than 10 cm. We performed cystoscopy under spinal anesthesia. Cystoscopic examination showed a beading awl with plastic handle approximately 15 cm in length that was penetrated into the mucosa. We could not remove the beading awl endoscopically because of its length, smooth metallic surface and extensive submucosal penetration. We performed mini-laparotomy and cytotomy, and the foreign body was removed without complication (Fig. 2). Antibiotherapy and tetanus prophylaxis were initiated after the operation. The patient was referred for psychiatric evaluation and discharged from the hospital on the second day post-operatively.

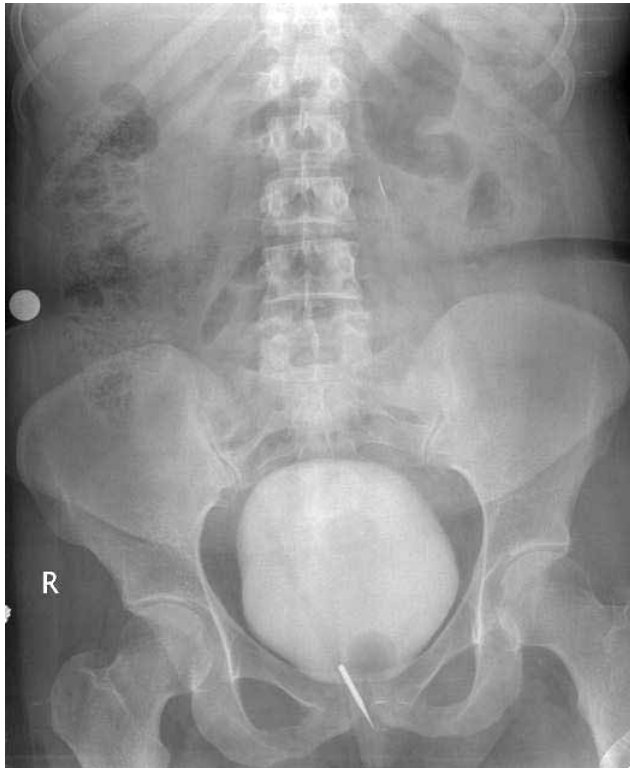


Figure 1 Cystography demonstrated a radiopaque foreign body. There was no perforation.

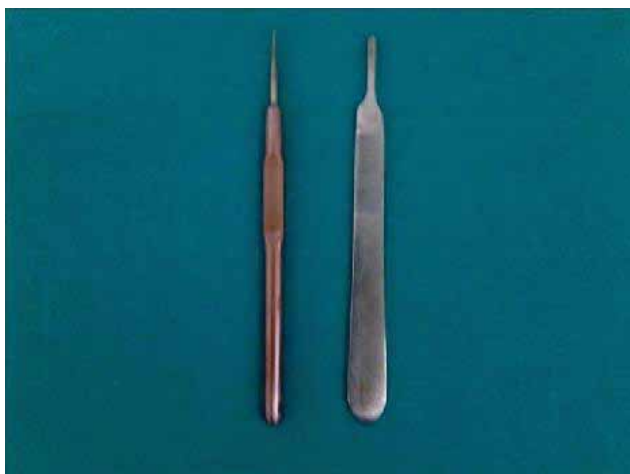

Figure 2 Beading awl after removal as compared to a scalpel.

Discussion

A foreign body in the urinary bladder or urethra is a urologic emergency. Foreign bodies are most commonly introduced for masturbation, sexual stimulation, and hygienic aims. Most of the cases are associated with psychiatric disorders. The main symptoms reported in the literature are pollakiuria, dysuria, hematuria, urinary retention, abdominal or

pelvic pain, and recurrent urinary tract infection.^[1,6] Migration of the foreign bodies from neighboring organs is frequently iatrogenic or traumatic in origin. Intrauterine devices, suture materials, gauze, chicken, and fish bones have been reported as migrated objects in the bladder.^[6-8] On the other hand, Cury et al.^[9] presented a case of a ballpoint pen self-inserted via the urethra into the bladder in a female patient; the object was discovered in the retroperitoneum years later. That was the first case in the English literature describing retroperitoneal migration of a foreign body from the urinary bladder.

Clinical history and radiographics are usually enough for the diagnosis of foreign bodies in the urinary tract. The diagnosis of some foreign objects should be done by ultrasonography, cystography, and computed tomography.^[4] Certain suspected cases require advanced investigation such as cystoscopy for diagnosis.^[6] We performed cystography for diagnosis in the presented case because we suspected perforation of the bladder. The cystography revealed the presence of a foreign body in the bladder, but there was no extravasation or suspicion of bladder perforation.

A foreign body in the bladder is not a rare condition. The main aims of management involve the diagnosis of complications and complete extraction of the foreign body with minimal trauma to the bladder and urethra.^[1,2,4,10] Most foreign bodies can be removed by cystoscopy, but sometimes open surgery is required. Kochakarn and Pummanagura^[6] reported on their 20 years of experience with vesical foreign bodies in females. They assessed seventy-eight patients. Endoscopic treatment could be performed in 74 cases, and only four cases were treated by open surgery. In our case, we tried to remove the beading awl cystoscopically with foreign-body forceps, but this was not possible due to the smooth surface of the object and its penetration of the mucosa. We then performed cystotomy and removed the object.

Various foreign bodies have been found in the bladder. Vezhaventhan and Jeyaraman^[5] reported a remarkable case two years ago. A fish had been self-inserted into the bladder of a male individual. The authors successfully treated him cystoscopically. The diagnosis and treatment of foreign bodies in the urinary tract depend primarily on the type of object. Cystography, ultrasonography, and computed tomog-

raphy can be used for diagnosis. Cystoscopy is both a diagnostic and treatment tool for addressing the insertion of foreign bodies in the bladder. As in the reported case, when cystoscopic extraction is not possible, open surgery is the only method of choice for treatment after the insertion of foreign objects.

Although the use of foreign objects for sexual gratification is a rare condition, foreign bodies can be self-inserted for masturbation, frequently in patients with psychiatric disorders. Examination of the urinary bladder and urethra is very important in psychiatric patients with urinary symptoms and pelvic pain. Therefore, all cases must be sent for psychiatric counseling. Psychiatric evaluation and treatment are necessary to obviate repeated cases.

Conflict of interest

No conflict of interest was declared by the authors.

References

1. Sukkarieh T, Smaldone M, Shah B. Multiple foreign bodies in the anterior and posterior urethra. *Int Braz J Urol* 2004;30:219-20. [\[CrossRef\]](#)
2. Pal DK, Bag AK. Intravesical wire as foreign body in urinary bladder. *Int Braz J Urol* 2005;31:472-4. [\[CrossRef\]](#)
3. Ayyildiz A, Gurdal M, Nuhoglu B, Ersoy E, Huri E, Germiyanoglu C. A foreign body self-inserted via the urethra into the bladder: pocket battery. *Int Urol Nephrol* 2003;35:251-2. [\[CrossRef\]](#)
4. Trehan RK, Haroon A, Memon S, Turner D. Successful removal of a telephone cable, a foreign body through the urethra into the bladder: a case report. *J Med Case Reports* 2007;1:153. [\[CrossRef\]](#)
5. Vezhaventhan G, Jeyaraman R. Unusual foreign body in urinary bladder: a case report. *The Internet Journal of Urology* 2007;4:2.
6. Kochakarn W, Pummanagura W. Foreign bodies in the female urinary bladder: 20-year experience in Ramathibodi Hospital. *Asian J Surg* 2008;31:130-3. [\[CrossRef\]](#)
7. Mustafa M. Erosion of an intrauterine contraceptive device through the bladder wall causing calculus: management and review of the literature. *Urol Int* 2009;82:370-1. [\[CrossRef\]](#)
8. van Ophoven A, deKernion JB. Clinical management of foreign bodies of the genitourinary tract. *J Urol* 2000;164:274-87. [\[CrossRef\]](#)
9. Cury J, Coelho RF, Srougi M. Retroperitoneal migration of self-inflicted ballpoint pen via urethra. *Int Braz J Urol* 2006;32:193-5. [\[CrossRef\]](#)
10. Bakshi GK, Agarwal S, Shetty SV. An unusual foreign body in the bladder. *J Postgrad Med* 2000;46:41-2.

Correspondence (Yazışma): Uzm. Dr. Uğur Balci.
Atatürk Research and Training Hospital, First Urology Clinic,
İzmir, Turkey.
Phone: +90 244 44 44-1562 e-mail: ubalci1907@yahoo.com
doi:10.5152/tud.2011.052