

## Clinical evaluation of pediatric testicular masses

### Çocukluk çağı testis kitlelerinin klinik değerlendirmesi

Cenk Murat Yazıcı<sup>1</sup>, Polat Türker<sup>1</sup>, Selçuk Yücel<sup>2</sup>

<sup>1</sup>Namık Kemal University Faculty of Medicine, Department of Urology, Tekirdağ, Turkey

<sup>2</sup>Akdeniz University Faculty of Medicine, Department of Urology, Antalya, Turkey

#### Abstract

Scrotal pathologies are frequently seen in pediatric population. There are plenty of diseases that can be seen with similar clinical findings. These are generally benign lesions that can be diagnosed by simple physical examination and radiological techniques. Most of the clinicians are familiar with these diseases and are able to manage them. The problematic diseases of scrotum are testicular masses. They are seen rarely, but when they are diagnosed, they cause anxiety in both family and clinician. This may cause overtreatment of these diseases, as it is proposed to be in adult patients. However, these tumors have different characteristics in pediatric population. They also differ between prepubertal and postpubertal pediatric patients. Like histopathological properties, malignancy potentials of testis tumors are different in prepubertal ages. Benign tumors are much more frequent in pediatric group. This gives the clinician an opportunity for conservative treatment. Testis sparing surgery which is performed rarely for adult testis tumors, can be very efficient for prepubertal patients. According to oncologic principles, conservative surgery must be performed only for absolutely indicated patients. For this reason, clinicians must have the idea how to differentiate benign and malignant testicular masses. In this review, we summarized the most common testicular pathologies in children, and tried to point out the principles of evaluating, differentiating and treating benign and malignant testicular masses of pediatric age group.

**Key words:** Pediatric; teratoma; testis tumor; yolk sac.

#### Özet

Pediyatrik hasta popülasyonunda skrotal patolojilere sık olarak rastlanmaktadır. Benzer klinik bulguları gösteren çok sayıda hastalık mevcuttur. Bunlar basit fizik muayene ve radyolojik tekniklerle tanı konabilen genellikle benign lezyonlardır. Klinisyenlerin çoğu bu hastalıklara alışkandır ve kolaylıkla tedavi edebilir. Skrotumun problemli hastalıkları testiküler kitlelerdir. Ender görülmekle birlikte, tanı konduklarında hem ailede hem de hekimde anksiyeteye neden olurlar. Bu durum, yetişkin hastalardaki yaklaşıma benzer olacak şekilde aşırı tedaviye neden olur. Ancak bu tümörler pediyatrik popülasyonda farklı karaktere sahiptir. Ayrıca prepubertal ve postpubertal pediyatrik hastalarda da farklılık göstermektedir. Testis tümörlerinin histopatolojik özellikleri yanında malignansi potansiyeli de prepubertal dönemde farklıdır. Pediyatrik dönemde benign tümörler daha sıktır. Bu durum hekime daha konservatif tedavi uygulayabilme imkanı vermektedir. Yetişkin hastalarda ender olarak uygulanan testis koruyucu cerrahi prepubertal hastalarda çok etkili olabilir. Onkolojik prensiplere göre koruyucu cerrahi, kesin endikasyonu olan hastalarda uygulanmalıdır. Bu nedenle klinisyen benign ve malign testis kitlelerinin ayırımına yönelik bilgi sahibi olmalıdır. Bu derlemede çocukluk çağındaki en sık testis patolojilerini özetleyerek, ve benign ve malign testis kitlelerinin değerlendirilmesi, ayırıcı tanısı ve tedavisi için temel prensipleri vurguladık.

**Anahtar sözcükler:** Pediyatrik; teratom; testis tümörü; yolk kesesi.

Submitted (Geliş tarihi): 20.05.2010

Scrotal pathologies in pediatric population are common. A wide spectrum of diseases and conditions can be involved in the differential diagnosis of similar clinical findings. While scrotal pain is the main symptom of some scrotal pathologies, others may present only with a scrotal mass or swelling without any pain.

Whatever the symptoms are, scrotal abnormalities can cause a serious anxiety for both patients and their family. This, positively cause early intervention and treatment of most cases but sometimes, negatively cause over and aggressive treatment. Scrotal masses, especially scrotal tumors in pediatric population

can be the best example of overtreated pathologies of scrotum. Although, palpable testicular masses in adults are mostly reported to be malignant and need radical surgery, this clinical situation is different in pediatric population.

Nearly 50% of painless scrotal masses in children are benign and they do not require aggressive surgical treatment.<sup>[1-3]</sup> On the other hand, tumors with very malignant behaviour can also be seen in pediatric population. So underestimating the diagnosis and treatment strategy for this group of patients may cause fatal results. In this review, we summarized the common pathologies in the differential diagnosis of scrotal diseases, and focused on the benign and malign testicular tumors in pediatric group.

### General principles of evaluating pediatric scrotal masses

Since most of the scrotal pathologies have specific clinical and radiological findings, urologists can clearly diagnose and treat most of the pediatric scrotal masses. According to anatomic location and clinical presentation, these can simply be categorized in four groups (Table 1):

1. Testicular painful scrotal masses
2. Testicular painless scrotal masses
3. Extratesticular painful scrotal masses
4. Extratesticular painless scrotal masses

### Non-tumorous masses

Most common painless scrotal masses in pediatric group are inguinal hernia, hydrocele, varicocele and spermatocele. They form more than half of the pedi-

atric scrotal pathologies. As they are easily diagnosed by physical examination and simple radiological investigations (scrotal ultrasonography and doppler ultrasonography), misdiagnosis is rare for these diseases. There are only a few points that a urologist must be aware of, during the evaluation of these pathologies:

1. Most of the simple scrotal hydroceles resolve by the age of 1 year. So both the clinician and family must be patient during this period not to act aggressive for treatment.
2. Blood can be found in hydrocele sac which can be related with intraabdominal bleeding and can be associated with incomplete occlusion of umbilical vessels or a splenic rupture. Thus, this clinic must alert the clinician for further evaluation.
3. Hydrocele may be seen in 10% of testicular tumors. Thus, ultrasonography should be done, especially in patients when physical examination is ineffective in evaluating the testis.
4. A prepubertal varicocele or a right sided varicocele in children may be related with an abdominal or retroperitoneal mass. So the clinician should search these locations for further evaluation.
5. An unnecessary surgery for epididymal cysts may cause an injury to rete testis which may lead to infertility. Thus clinician should be careful while deciding surgery for these patients.
6. In pathologic specimen studies, torsion of appendix testis (hydatid of Morgagni) seem to be a frequent reason of acute testicular pathologies in pediatric group (9-43%).<sup>[4-6]</sup> So a clinician should consider this pathology in differential diagnosis of painful scrotal pathologies in pediatric patients.

**Table 1. Clinical categorization of scrotal masses according to anatomic location and clinical findings**

Testicular painful masses	Testicular painless masses	Extratesticular painful masses	Extratesticular painless masses
Torsion of spermatic cord	Malignant testicular tumors	Epididymitis	Hernia
Orchitis	Benign testicular tumors	Torsion of appendix testis	Hydrocele, hematocele
Testicular trauma (rupture, hematoma)	In utero extravaginal torsion	Torsion of epididymis	Adenomatoid epididymis tumor
Hemorrhage into tumor		Incarcerated hernia	Soft tissue tumors Benign or malignant
Kawasaki disease			Idiopathic scrotal edema
Henoch-Schonlein purpura			

## Tumorous masses

Pediatric testis tumors are rare tumors representing 1-2% of all pediatric solid tumors. The incidence of these tumors are 0.5-2/100,000 children.<sup>[7]</sup> Although they arise from the same organ, they are histologically, genetically and clinically different from adult population. While seminoma and mixed germ cell tumors are the most common tumor types in adult group, they are almost only seen in postpubertal group of pediatric population. From histological aspect, testis tumors in children are generally in single type (mixed type in adults) and genetically they are mostly euploid tumors (aneuploid tumors in adults).<sup>[8,9]</sup> The major clinical difference between adult and pediatric testis tumors is malignancy potential. Nearly 95% of the adult testis tumors are malign, whereas testis tumors with benign property is seen much more in pediatric population.

## Histology of prepubertal testis tumors

The histological types of testis tumors according to prepubertal testis tumor registry (PTTR) data are summarized in Table 2.<sup>[10]</sup> As reported in prepubertal testis tumor registry, yolk sac tumor is most frequent type of testis tumor in children. Teratoma, which is a benign tumor in prepubertal children, is in the second place. But in the literature, there are series debating this data.<sup>[1,12,13]</sup> In a prevalence study, Pohl et al.<sup>[1]</sup> reported that teratoma forms 48% of all testicular tumors in prepubertal children which is followed by yolk sac tumor (15%). Epidermoid cyst, which is also a benign tumor is found in 14% of patients. So they reported that nearly 60% of testicular tumors are benign. As a conclusion, they pointed to the idea that the different prevalence ratios in PTTR series can be due to underregistration of benign testicular pathologies to the data base of PTTR.<sup>[1]</sup> Similar to these findings, Taskinen et al.<sup>[14]</sup> reported that 16 of 34 patients (47%) had teratoma while 6 of 34 (17%) had yolk sac tumor in their series. As their overall estimation, the prevalence of benign lesions are 68%, while remaining seem to be malignant tumors. On the other hand, Ciftci et al.<sup>[15]</sup> reported the predominance of yolk sac tumors in their 51 patients' series which is similar to the reports of PTTR.

## Presentation of prepubertal testis tumors

According to PTTR data, testis tumors represent as a painless scrotal mass in 88% of patients. In 11%, a hydrocele can be the reason for patients evalua-

tion. Scrotal pain due to bleeding into tumor can be another type of presentation in a limited number of patients.<sup>[11]</sup> Because most of the testicular tumors has been diagnosed in early stage, symptoms due to metastasis is rarely seen. If this is the situation, bone and central nervous system symptoms can be the reason of patients' presentation.

## Clinical evaluation of prepubertal testis tumors

For the diagnosis of prepubertal testis tumors, ultrasonography is a very useful radiological technique. It can distinguish intratesticular and extratesticular pathologies with a high sensitivity and specificity.<sup>[16]</sup> Although some special ultrasonographic findings were defined, none of them are able to discrete malignant and benign testicular tumors. Radiologic evaluation for metastasis must be done after the pathologic evaluation of testicular mass, because high percentage of prepubertal testis tumors are benign and most of the malignant testis tumors are diagnosed at early stage of disease. So abdominal computerized tomography and chest radiography are performed according to pathological diagnosis.

Tumor markers are very important for both diagnosis and follow-up of malignant testicular tumors in pediatric group. Alpha-fetoprotein (AFP) which is an albumin precursor that is synthesized by yolk sac, liver and gastrointestinal tract of developing fetus, is very specific marker for testicular yolk sac tumor. Nearly in 90% of yolk sac tumors, this marker is found to be increased.<sup>[17]</sup> It can also be increased in nonseminomatous germ cell tumors, hepatocellular carcinoma,

**Table 2. Incidence of pediatric testicular tumors according to Prepubertal Testis Tumor Registry data<sup>[11]</sup>**

Tumor type	No of patients	Percent (%)
Germ cell tumors		
Yolk sac tumor	244	62
Teratoma	92	23
Epidermoid cyst	13	3
Stromal tumors		
Juvenile granulosa cell	11	3
Sertoli's cell	10	3
Leydig cell	5	1
Non-specified	16	4
Gonadoblastoma	4	1

viral hepatitis and cirrhosis.<sup>[18]</sup> Although AFP is very important in differentiating yolk sac tumors from benign testicular tumors, it can also be found high in neonates. Level of AFP in a newborn can be as high as 50,000 ng/dL. As it has a 5 days half-life, it starts to decline during neonatal life and reach to 0-20 ng/dL by the age of 8 months.<sup>[19]</sup> So for patients smaller than 6 months of age, AFP is not a useful marker in distinguishing yolk sac tumor from benign testis tumors. Beta subunit of human chorionic gonadotropin (beta-HCG), a tumor marker in adult patients, is not useful for prepubertal testis tumors because tumors related with beta-HCG is rarely seen in prepubertal children. Clinical evaluation of prepubertal scrotal pathologies are shown in Fig. 1.

### **Management of specific prepubertal testis tumors**

#### **Yolk sac tumor**

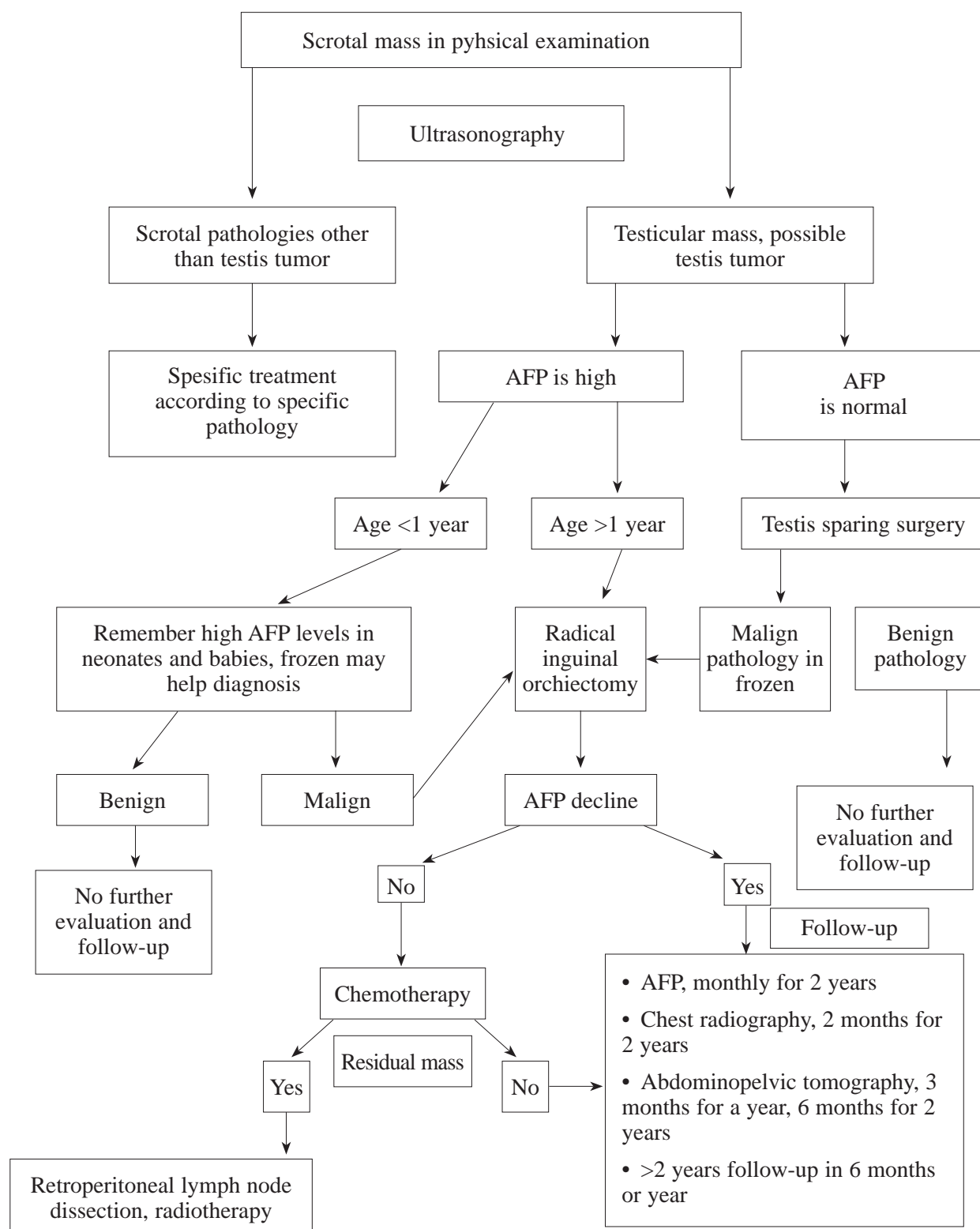
Yolk sac tumor is the most common malignant histologic type in prepubertal patients. It forms nearly 70% of all prepubertal germ cell tumors.<sup>[20]</sup> Macroscopically, it is friable, mucoid and yellow to pale gray in appearance. Microscopically, glomeruloid bodies (Schiller-Duval), embryoid bodies and hyaline bodies are histopathologic features. Positively staining with AFP makes the exact diagnosis of this tumor. Yolk sac tumors in prepubertal period differs from postpubertal and adult patients. Although it is found to be more aggressive in adult patients, 85% of yolk sac tumors are stage 1 tumors that do not make any metastasis before diagnosis in prepubertal ages.<sup>[21]</sup> They are pure tumors that does not shelter any other cell types, which is very random in adult population. The way of metastasis also differs from adults. Lymphatic spread is far more responsible for metastasis in adult patients, but in children, hematogenous way has also an important role in tumor metastasis. For this reason, organ metastasis is seen more frequently than lymphatic metastasis in children. Related to this data, Wu et al.<sup>[21]</sup> reported 20% lung metastasis compared to 4-6% of retroperitoneal lymph node metastasis in their patients. Similar to this finding, Grady et al.<sup>[21]</sup> reported hematogenous and lymphatic spread was 40% and 28%, respectively and most common site of metastasis was lungs.<sup>[20]</sup> As dictated before, AFP is very important in both diagnosis and

follow-up of yolk sac tumors in pediatric patients. It is well documented that, in 92% of yolk sac tumors, there is an increase in AFP levels.<sup>[11]</sup>

Radical inguinal orchiectomy is the standard surgical approach for yolk sac tumors. As it is diagnosed, it should be removed with high ligation of spermatic cord. AFP levels are supposed to decrease after orchiectomy, if tumor is confined to testis which means the early stage of disease (stage 1). These patients can be safely followed up without any adjuvant treatment. Suggested follow-up protocol for these patients is the monthly serum AFP measurement for 2 years, chest radiography in 2 months for 2 years, and abdominopelvic computerized tomography in every 3 months for a year and in 6 months till 2 years.<sup>[22]</sup> After 2 years of surveillance without any recurrence, follow-up periods can be prolonged to 6 months or a year. The recurrences can be diagnosed by elevation of AFP levels and nearly all of them can be managed by chemotherapy.

Patients whose AFP levels do not decrease to normal limits after surgery or who has metastatic radiological finding must be treated with multi-agent platinum-based chemotherapy. Although retroperitoneal lymph node dissection (RPLND) is very routine surgical approach in adult testis tumor treatment, it is limited in prepubertal patients, because of its high rate complications (e.g. bowel obstruction, gastrointestinal bleeding, renal artery ligation, ejaculatory dysfunction) and the property of tumor metastasis route.<sup>[10]</sup> It can be performed to patients whose AFP levels are high or have residual retroperitoneal mass after chemotherapy. RPLND can also be performed to patients with stage 1 tumors whose AFP levels are normal before orchiectomy. This is because AFP will not help to clinician in the follow-up of patient for the recurrence. If needed, RPLND can be performed as a standard or modified technique. In standard technique, all lymphatic tissue from renal hilum to 2 cm beyond the bifurcation of the common iliac arteries must be excised. In modified technique, more limited excision is done. For right-sided tumors, it is limited to anterior surface of aorta and right common iliac artery and for left-sided tumors, limit is anterior surface of vena cava and left common iliac artery.

Radiotherapy is not used in treatment of yolk sac tumors. Although tumor is radiosensitive, treatment



**Figure 1** Clinical evaluation of prepubertal scrotal pathologies. AFP: Alpha-fetoprotein.



doses are toxic for pediatric patients.<sup>[23]</sup> It can only be performed to patients who have metastasis that is resistant to chemotherapy and are unsuitable for surgical resection. Disease-free survival of this tumor is greater than %95 and even in stage 3 patients, this ratio reaches to 90% by the help of chemotherapy.<sup>[24,25]</sup> Recurrences can be observed in 18-22% of stage 1 tumors, but they can easily be treated by adjuvant therapies.

### Teratoma

Teratoma is the most common benign testicular tumor in prepubertal patients. Although it is the second most common testicular tumor after yolk sac tumor in PTTR data, there is some evidence that it can be much more frequent due to underregistration. There are some single institution data reporting that the prevalence of teratoma is nearly 50% of all testicular tumors of prepubertal ages.<sup>[1,12,13]</sup> It is formed by 3 embryological germ cell layers (ectoderm, mesoderm, endoderm). This causes different histological appearance of the tumor grossly. There may be cystic areas and/or calcifications in the tumor that can be detected by ultrasonography, but these are not specific to this tumor. In the histopathological evaluation of teratoma in adults and postpubertal children, 88% of patients have germ cell tumor at the same time. But, it is very rare that nearly all teratomas are pure benign tumors in prepubertal patients.<sup>[26]</sup>

AFP does not increase in teratomas. It is very useful in differentiating teratoma from yolk sac tumor.<sup>[23]</sup> The only exception is the neonatal period where AFP is physiologically over normal limits. Treatment for prepubertal teratoma is testis-sparing enucleation. It is a safe technique, if it is performed in selected patients according to principles of oncologic surgery. Spermatic cord must be mobilized and atraumatically occluded before enucleation of the tumor. Tumor can easily be enucleated by simple maneuvers. If it is infiltrative that can not be enucleated easily, malignancy must be proposed and surgery must be changed to radical orchiectomy. A frozen section must be performed during operation. As it confirms the diagnosis of teratoma, testis sparing surgery can proceed.

Another key point of testis sparing surgery is, pubertal development in older children must be checked from normal testis tissue. If there is sign

of pubertal development, orchiectomy must be performed because of high malignancy risk of teratomas in postpubertal patients. Rushton et al.<sup>[27]</sup> reported no recurrence after testis-sparing enucleation. Similar results were reported by different authors proving the safety of testis sparing enucleation.<sup>[28,29]</sup> In a 10-year follow-up study, Sugita et al.<sup>[12]</sup> reported that no testicular atrophy occurred as none of the patients had recurrence. For prepubertal teratoma, there is no need for further metastatic evaluation and surveillance protocol. But postpubertal patients with teratoma must be evaluated and followed up like adult germ cell tumors.

### Epidermoid cyst

Epidermoid cyst is also a benign form of testis tumor that is of ectodermal origin. Similar to prepubertal teratomas, they are well-circumsized, benign tumors that mostly do not metastasize. There is no germ cell tumors associated with prepubertal epidermoid cyst and AFP levels do not increase. Similar to other types of testis tumors, ultrasonography is very useful for diagnosis. Mixed echogenicity areas that have both hyperechoic and hypoechoic portions are seen in ultrasonography. Although these are very specific for epidermoid cysts, they are not pathognomonic.<sup>[30,31]</sup> Testis sparing surgery is the choice of treatment for this tumor. Principle of surgery is same as in the prepubertal teratoma patients. Ross et al.<sup>[31]</sup> reported no recurrence or metastasis in their series after testis sparing enucleation. So these tumors do not need any further evaluation or follow-up.

### Other types of testicular tumors

Seminoma and mixed germ cell tumors are very rare in pediatric group. If pathologic evaluations report these tumor types, patients must be treated like adult germ cell tumors. Stromal tumors like juvenile granulosa cell tumor, Sertoli cell tumor, Leydig cell tumor may also be seen. These are hormonally active tumors that can cause gynecomastia and can be related with precocious puberty. They must be treated like adult testis tumors, but testis sparing surgery can be performed to Leydig cell tumor because of its low metastatic property.

Testicular tissue may be a place for metastasis of other diseases. Mostly leukemia and lymphoma metastasize to the testis in pediatric group. They form

nearly 5% of all pediatric testis tumors and are generally seen bilaterally.<sup>[32]</sup> History of primary disease or evaluation of the children for the primary disease may help the diagnosis. If this is done, a wedge testicular biopsy will give the exact diagnosis. Local radiotherapy and systemic chemotherapy is the choice of treatment for this diagnosis.<sup>[33]</sup>

### Conflict of interest

No conflict of interest was declared by the authors.

### References

- Pohl HG, Shukla AR, Metcalf PD, Cilento BG, Retik AB, Bagli DJ, et al. Prepubertal testis tumors: actual prevalence rate of histological types. *J Urol* 2004;172:2370-2.
- Metcalf PD, Farivar-Mohseni J, Farhat W, McLorie G, Khoury A, Bagli DJ. Pediatric testicular tumors: contemporary incidence and efficacy of testicular preserving surgery. *J Urol* 2003;170:2412-6.
- Shukla AR, Woodard C, Carr MC, Huff DS, Caning DA, Zderic SA, et al. Experience with testis sparing surgery for testicular teratoma. *J Urol* 2004;171:161-3.
- Murphy FL, Law H, Mushtaq I, Sebire NJ. Testicular and paratesticular pathology in infants and children: the histopathological experience of a tertiary paediatric unit over a 17 year period. *Pediatr Surg Int* 2007;23:867-72.
- Marulaiah M, Gilhotra A, Lynette M, Boucaut H, Way Goh D. Testicular and paratesticular pathology in children: a 12-year histopathological review. *World J Surg* 2010;34:969-74.
- McAndrew HF, Pemberton R, Kikiros CS, Gollow I. The incidence and investigation of acute scrotal problems in children. *Pediatr Surg Int* 2002;18:435-7.
- Coppes MJ, Rackley R, Kay R. Primary testicular and paratesticular tumors of childhood. *Med Pediatr Oncol* 1994;22:329-40.
- Reuter VE. Origins and molecular biology of testicular germ cell tumors. *Mod Pathol* 2005;18:51-60.
- Perlman EJ. Cytogenetic analysis of childhood sinus tumors: a Pediatric Oncology Group study. *Pediatr Pathol* 1994;14:695-708.
- Agarwal PK, Palmer JS. Testicular and paratesticular neoplasm in prepubertal males. *J Urol* 2006;176:875-81.
- Ross JH, Rybicki L, Kay R. Clinical behavior and a contemporary management algorithm for prepubertal testis tumors: a summary of the Prepubertal Testis Tumor Registry. *J Urol* 2002;168:1678-9.
- Sugita Y, Clarnette TD, Cooke-Yarborough C, Chow CW, Waters K, Hutson JM. Testicular and paratesticular tumours in children: 30 years' experience. *Aust N Z J Surg* 1999;69:505-08.
- Rushton HG, Belman AB. Testis-sparing surgery for benign lesions of the prepubertal testis. *Urol Clin North Am* 1993;20:27-37.
- Taskinen S, Fagerholm R, Aronniemi J, Rintala R, Taskinen M. Testicular tumors in children and adolescents. *J Pediatr Urol* 2008;4:134-7.
- Ciftci AO, Bingol-Kologlu M, Senocak ME, Tanyel FC, Buyukpamukcu M, Buyukpamukcu N. Testicular tumors in children. *J Pediatr Surg* 2001;36:1796-801.
- Benson CB, Doubilet PM, Richie JP. Sonography of the male genital tract. *AJR Am J Roentgenol* 1989;153:705-13.
- Brewer JA, Tank ES. Yolk sac tumors and alpha-fetoprotein in first year of life. *Urology* 1993;42:79-80.
- Perkins GL, Slater ED, Sanders GK, Prichard JG. Serum tumor markers. *Am Fam Physician* 2003;68:1075-82.
- Wu JT, Book L, Sudar K. Serum alpha fetoprotein (AFP) levels in normal infants. *Pediatr Res* 1981;15:50-2.
- Grady RW, Ross JH, Kay R. Patterns of metastatic spread in prepubertal yolk sac tumor of the testis. *J Urol* 1995;153:1259-61.
- Grady RW. Current management of prepubertal yolk sac tumors of the testis. *Urol Clin North Am* 2000;27:503-6.
- Wu H, Snyder HM, 3rd. Pediatric urologic oncology: bladder, prostate, testis. *Urol Clin North Am* 2004;31:619-27.
- Connolly JA, Gearhart JP. Management of yolk sac tumors in children. *Urol Clin North Am* 1993;20:7-14.
- Hawkins EP. Nongerminomatous malignant germ cell tumors in children: a review of 89 cases from the Pediatric Oncology Group, 1971-1984. *Cancer* 1996;58:2579-84.
- Huddart SN. The UK Children's Cancer Study Group: testicular malignant germ cell tumors, 1979-1988. *J Pediatr Surg* 1990;25:406-10.
- Renedo DE, Trainer TD. Intratubular germ cell neoplasia (ITGCN) with p53 and PCNA expression and adjacent mature teratoma in an infant testis. An immunohistochemical and morphologic study with a review of the literature. *Am J Surg Pathol* 1994;18:947-52.
- Rushton HG, Belman AB, Sesterhenm I, Patterson K, Mostofi FK. Testicular sparing surgery for prepubertal teratoma of the testis: A clinical and pathological study. *J Urol* 1990;144:726-30.
- Grady R, Ross J, Kay R. Epidemiological features of testicular teratoma in a prepubertal population. *J Urol* 1997;158:1191-2.
- Tasaki Y, Nakagawa M, Hanada T, Mimata H, Nomura Y. Testis sparing surgery for infantile synchronous bilateral teratoma of the testis. *Int J Urol* 1998;5:501-3.
- Eisenmengen M, Lang S, Donner G, Kratzik C, Marberger M. Epidermoid cysts of the testis: organ-preserving surgery following diagnosis by ultrasonography. *Br J Urol* 1993;72:955-7.
- Ross JH, Kay R, Elder J. Testis sparing surgery for pediatric epidermoid cysts of the testis. *J Urol* 1993;149:353-6.

32. Kramer SA, Kelalis PP. Testicular tumors in children. In: Javadpour N, editor. Principles and management of testicular cancer. Thieme: New York; 1986. p. 362-77.
33. Palmer JS, Morris K, Steinberg GD, Kaplan WE. Testicular, sacrococcygeal, and other tumors. In: Vogelzang NJ, Scardino PT, Shipley WU, Coffey DS, editors. Comprehensive textbook of genitourinary

oncology. 2nd ed. Lippincott Williams & Wilkins: Philadelphia; 2000. p. 91-100.

**Correspondence (Yazışma):** Doç. Dr. Selçuk Yücel.  
Akdeniz Üniversitesi Tıp Fakültesi, Üroloji Anabilim Dalı,  
07070 Antalya, Türkiye.  
Phone: +90 506 855 26 87 e-mail: drsyucel@yahoo.com  
doi:10.5152/tud.2010.050